

# **CONTROVERSIE E NOVITA'**

## **BLOCCHI NERVOSI ECOGUIDATI IN URGENZA**

**Dott. Gian A. Cibinel**

**SC Medicina e Chirurgia d'Urgenza - Ospedale Civile di Pinerolo - ASL TO3**

# IL PROBLEMA DOLORE

- Dolore spontaneo non traumatico
- Dolore spontaneo traumatico
- Dolore procedurale

# ANALGESIA IN URGENZA

- Analgesici p.os
- Analgesici per via intranasale
- Analgesici per via parenterale
  - paracetamolo
  - ASA e FANS
  - tramadolo
  - oppiacei
- Anestesia locale
- Anestesia loco-regionale


# BLOCCHI NERVOSI IN URGENZA

- Dita
  - nervi interdigitali
- Arto superiore
  - mediano
  - radiale
  - ulnare
- Spalla
  - blocco interscalenico
  - blocco sovraclaveare
  - blocco infraclaveare

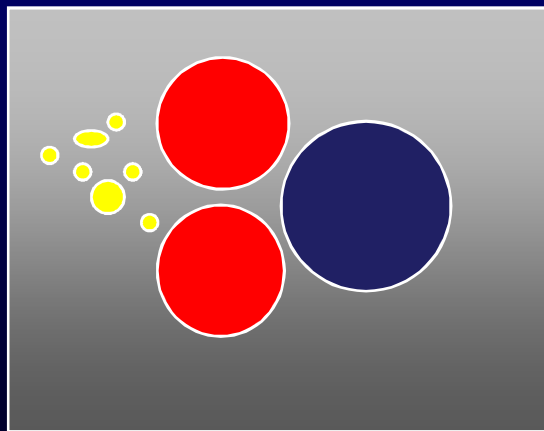
# BLOCCHI NERVOSI IN URGENZA

- Sciatico
- Popliteo
- Femorale
  - 3 in 1
- Fasciale coscia
- Parietale addominale



# VASI E NERVI DELL'INGUINE



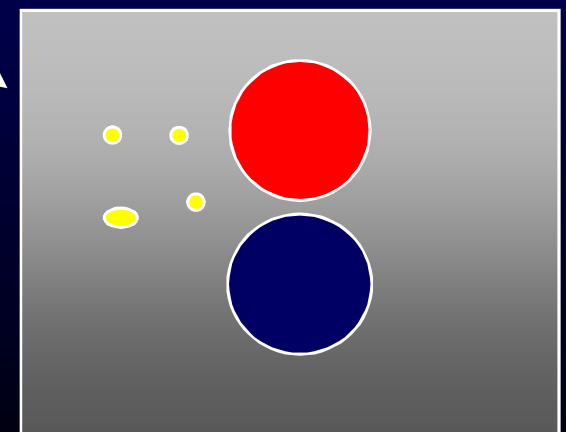
**Nervo femorale,  
arteria e vena  
femorali comuni**



**Biforcazione  
dell'arteria femorale**



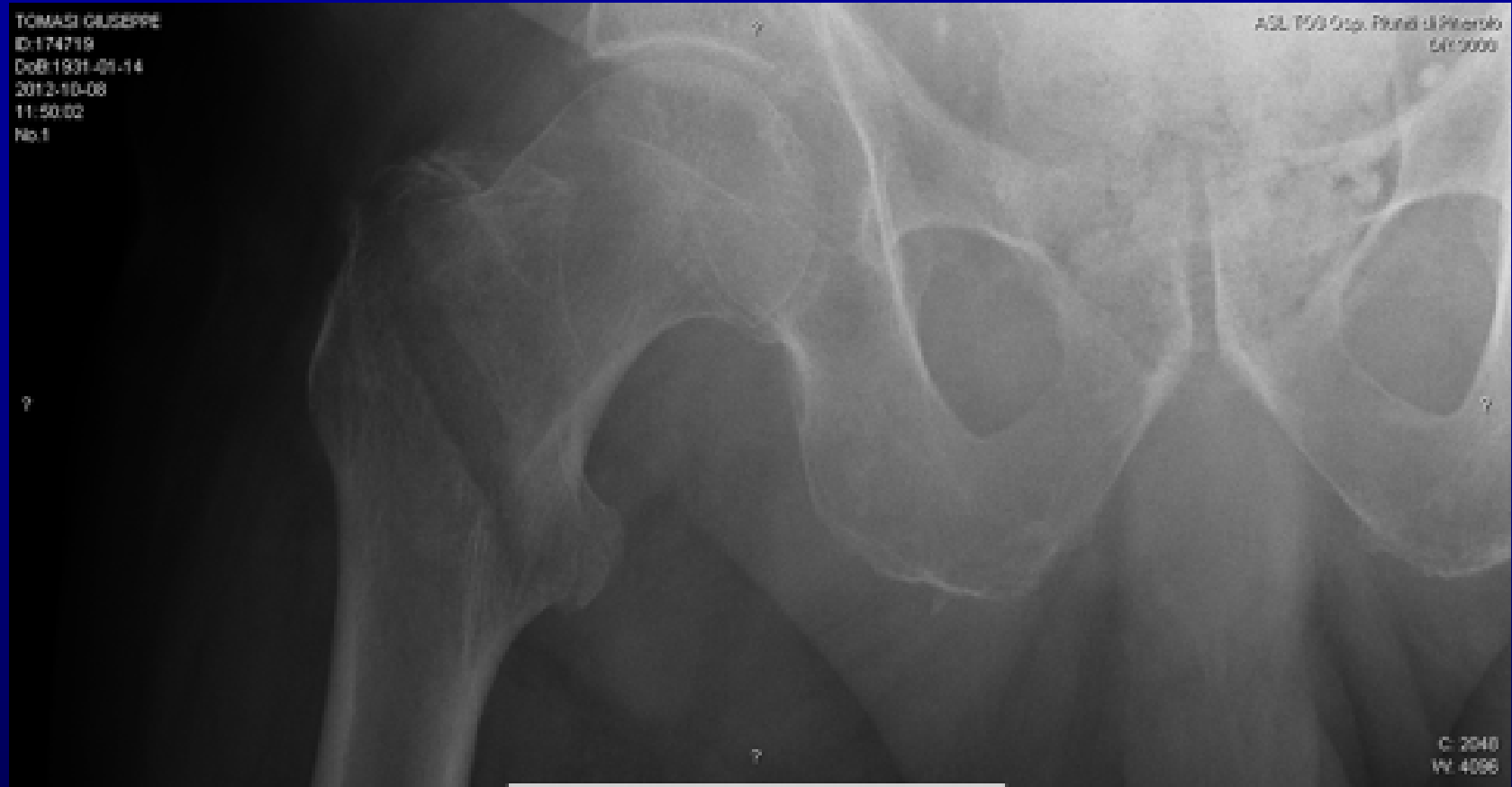**Confluenza della  
grande safena**



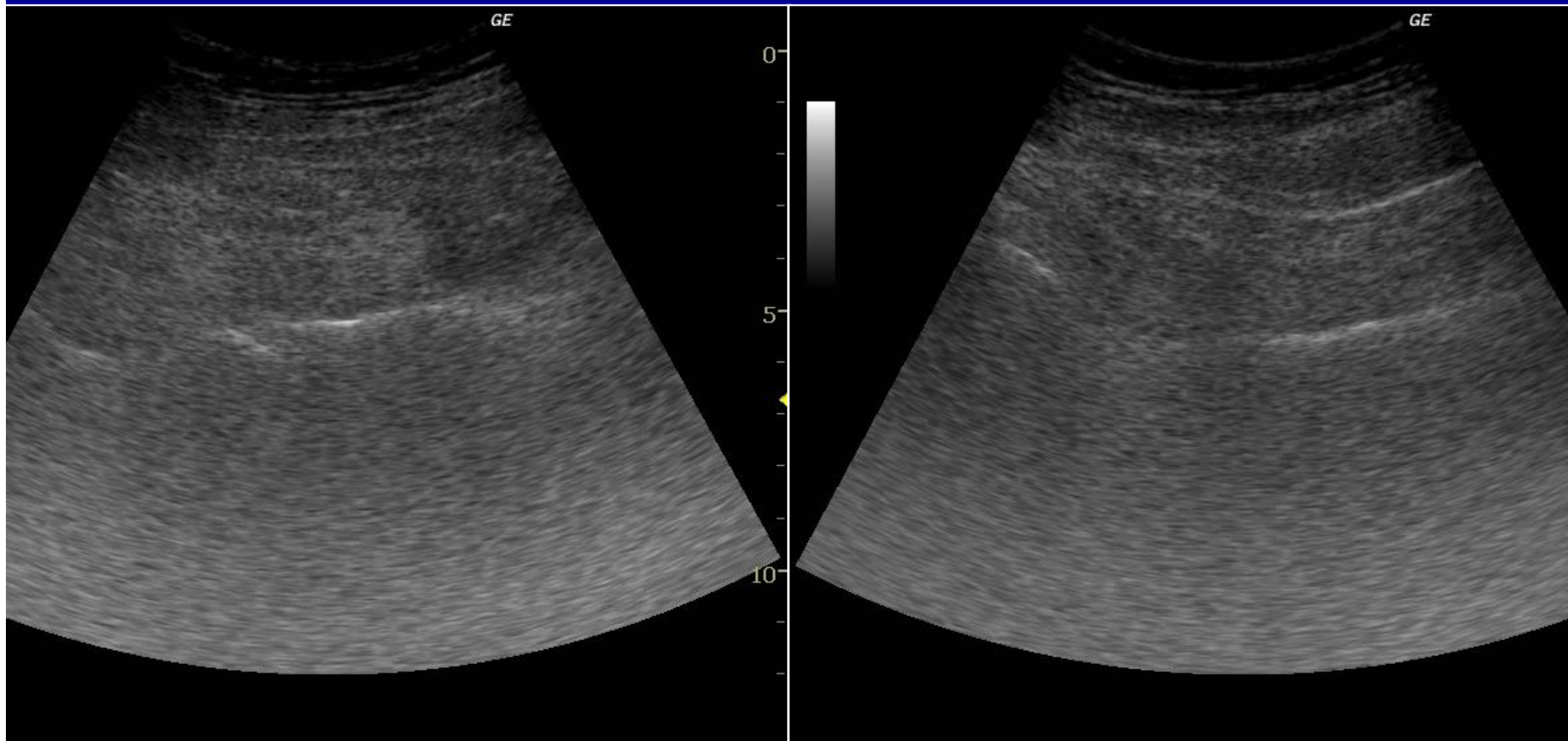
**Arteria e vena femorali  
superficiali**

TOMASI GIUSEPPE  
ID: 174719  
DoB: 1931-01-14  
2012-10-08  
11:50:02  
No. 1

ASL TSO Osp. Pizzardi - Piacenza  
641-0000



C 2040  
W 4000



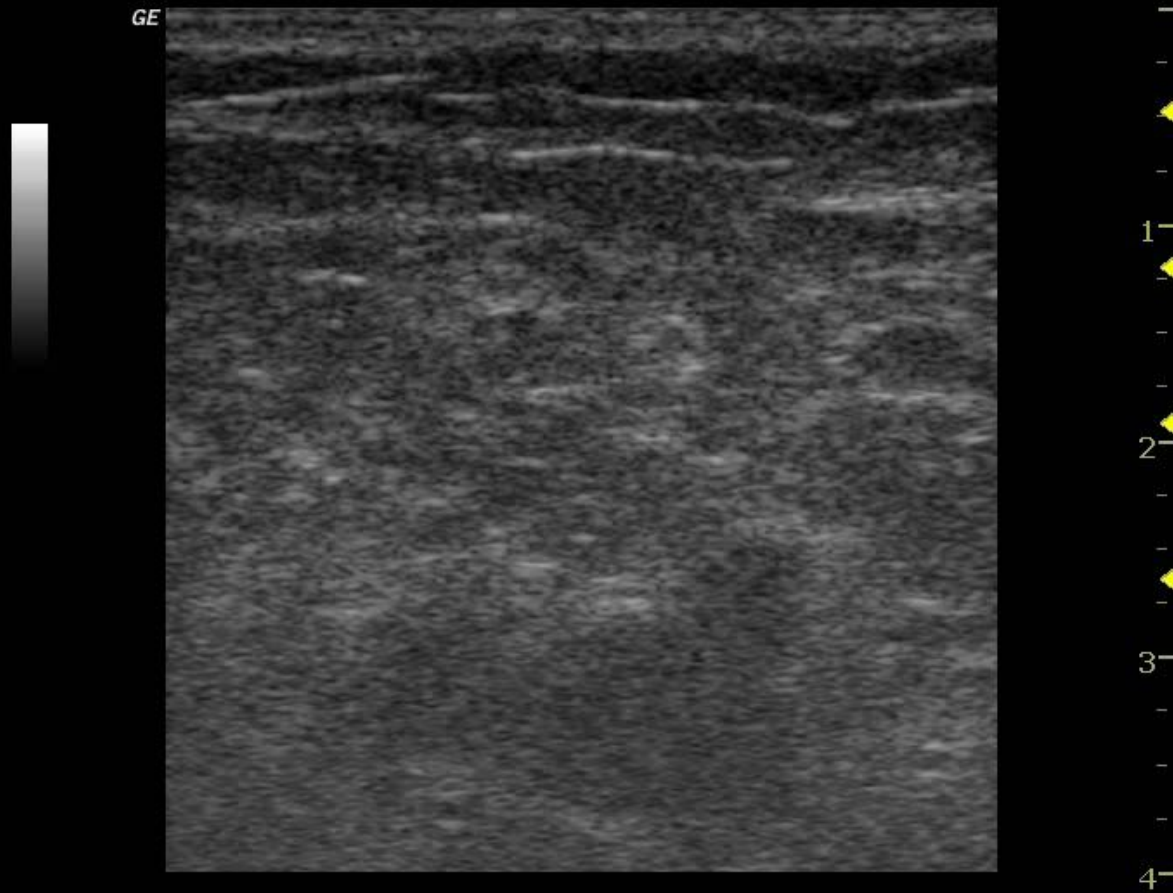
Studio ecografico preliminare



Preparazione 1

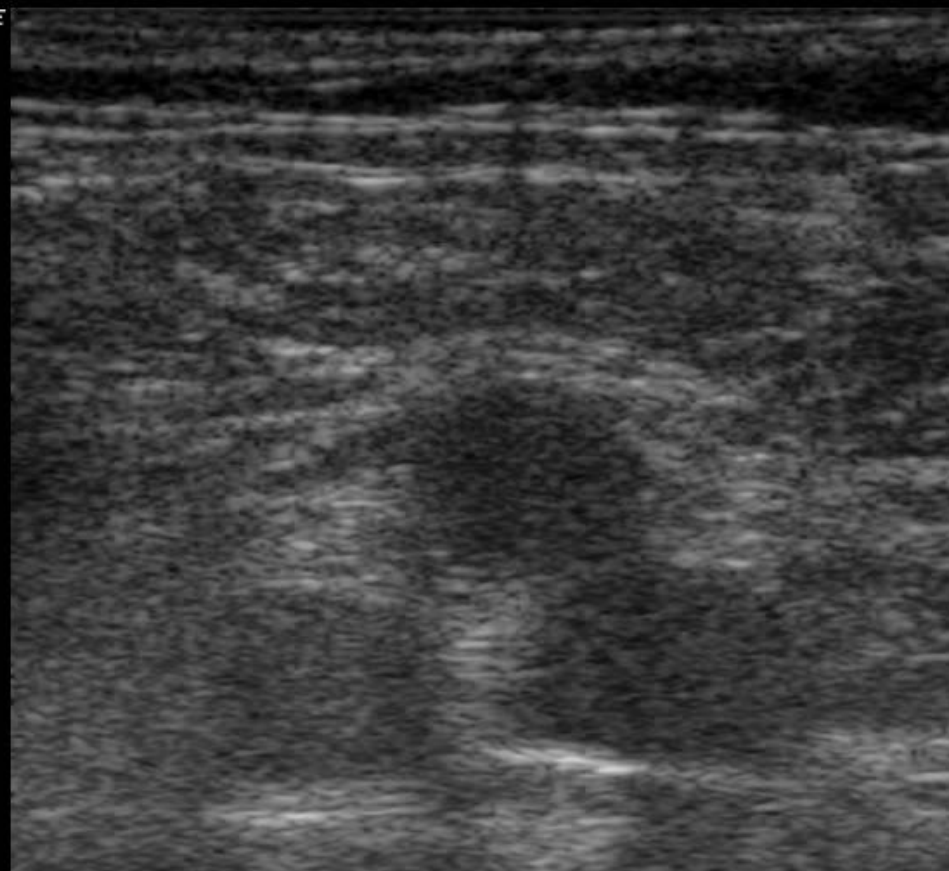
Preparazione 2

Posizione  
sonda 1



Posizione  
sonda 2

GE

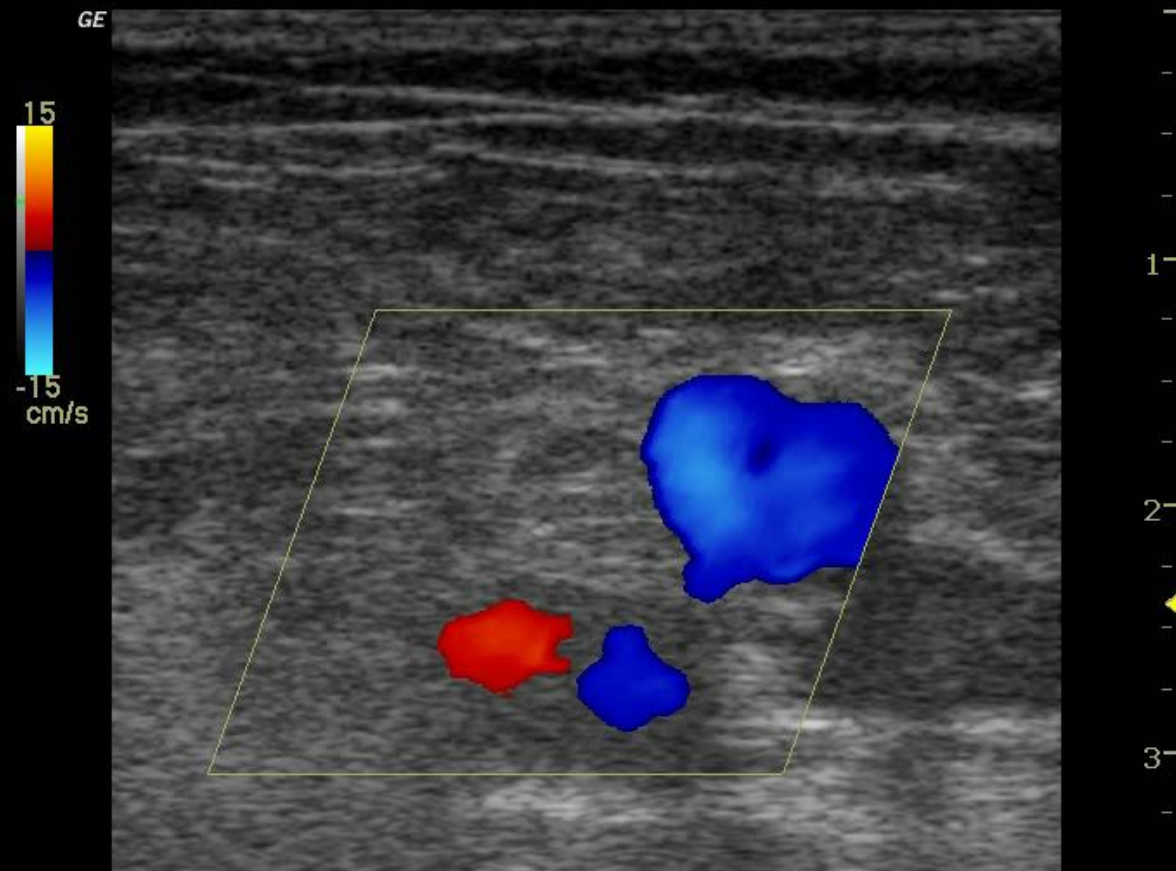


1

2

3

Posizione  
sonda 3



Preparazione  
ago

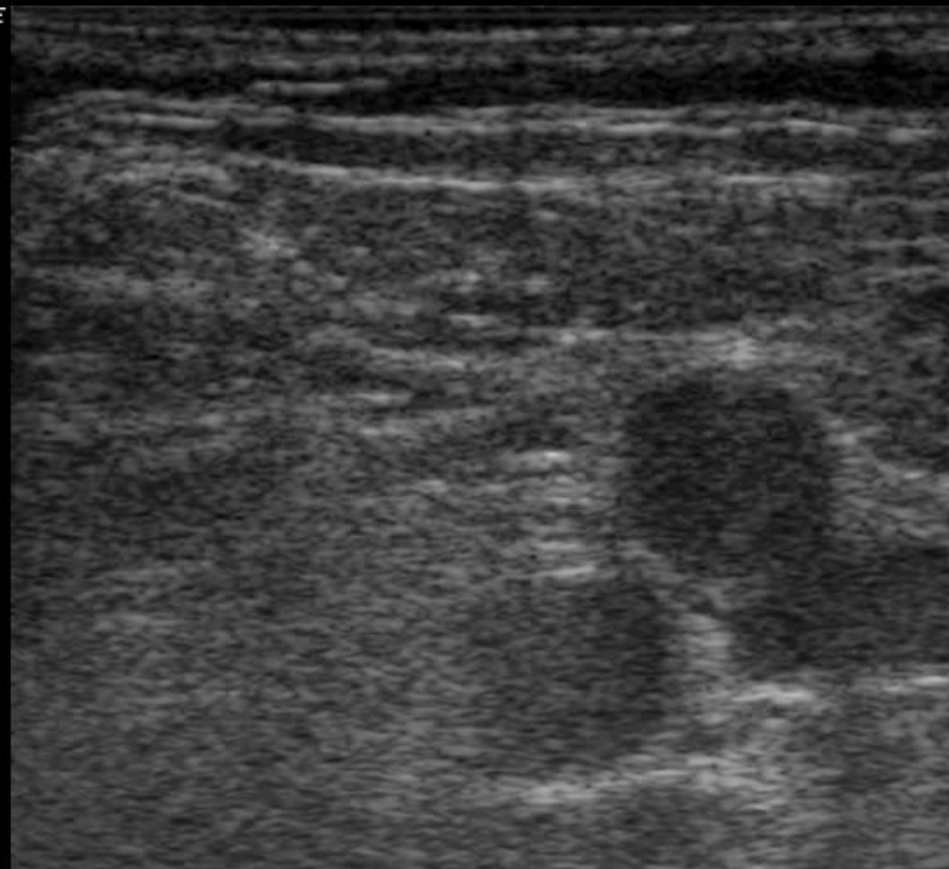
Collegamento  
siringa

Riempimento  
raccordo e ago



Introduzione  
ago 1

GE



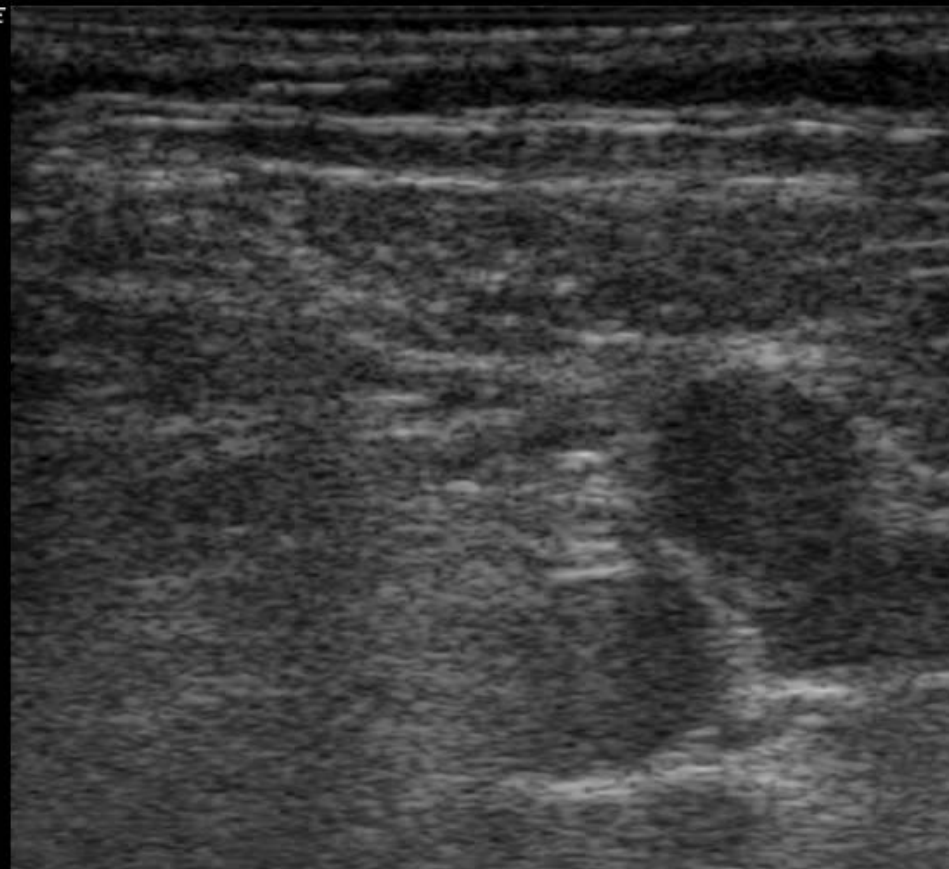
1-

2-

3-

Introduzione  
ago 2

GE



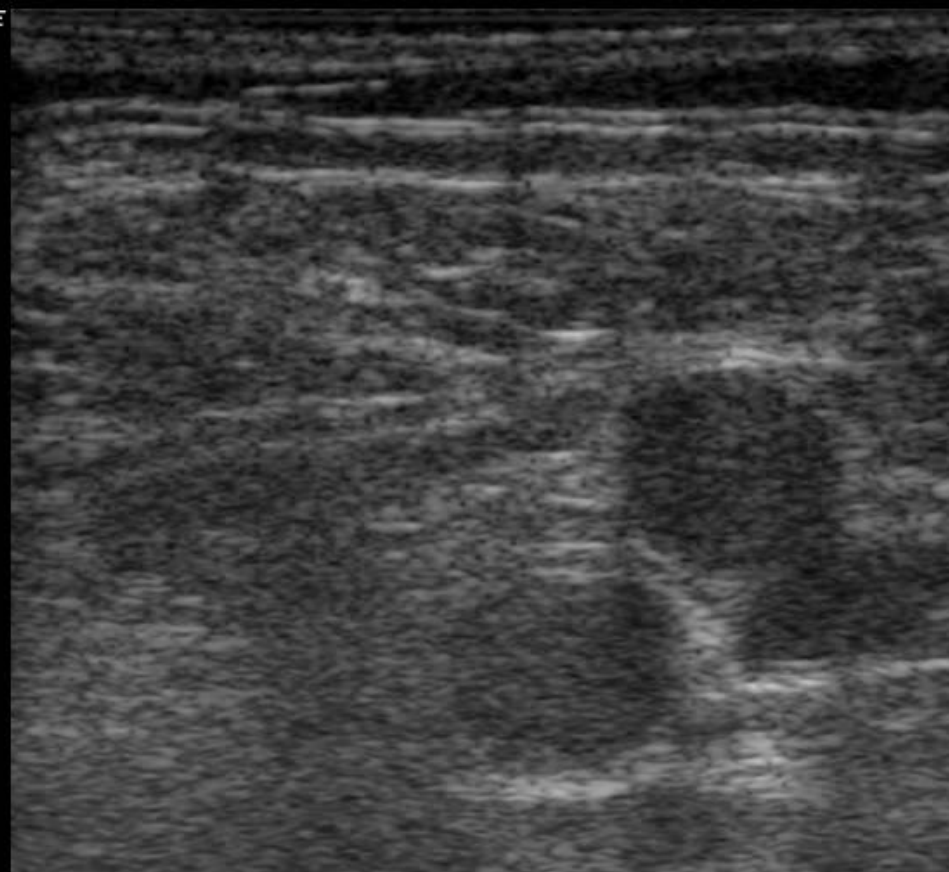
1-

2-

3-

Iniezione 1

GE

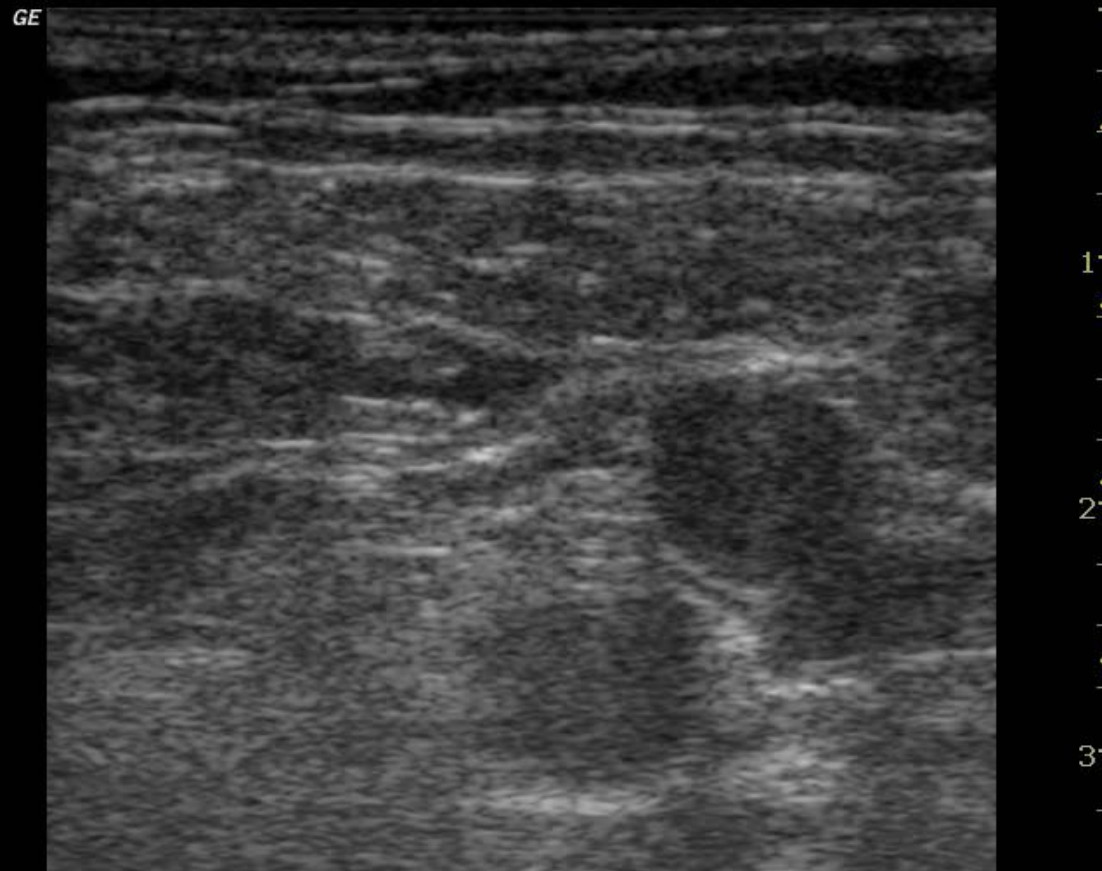


1

2

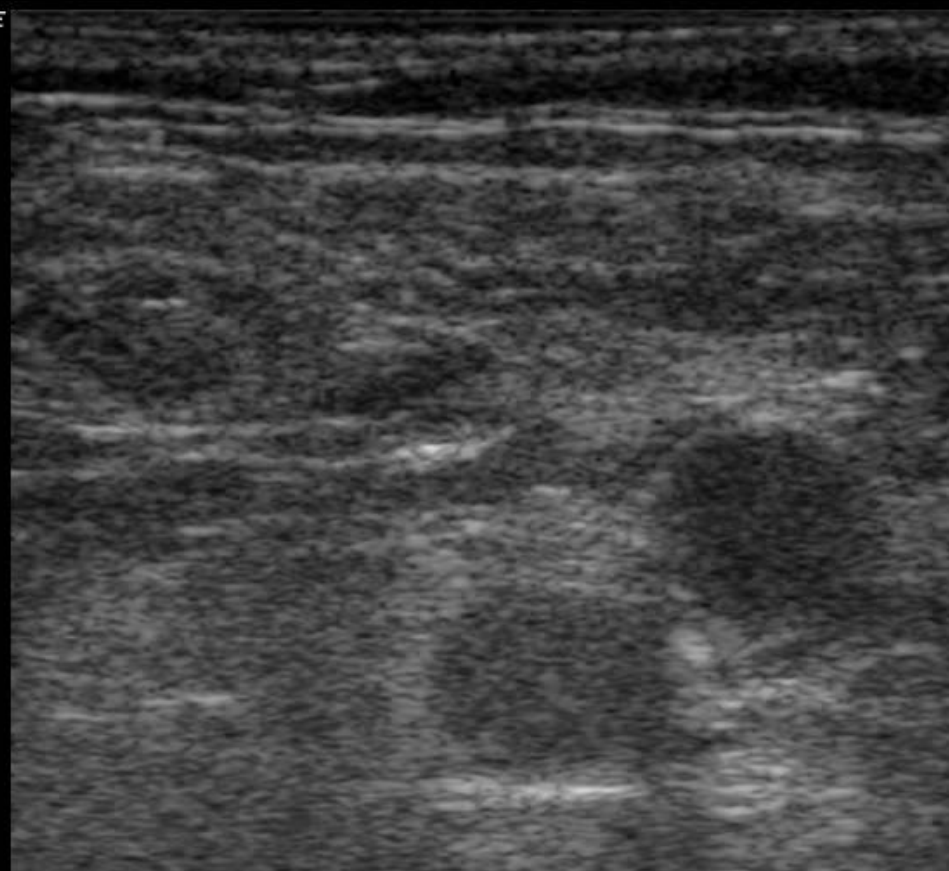
3

Iniezione 2



Estrazione  
ago

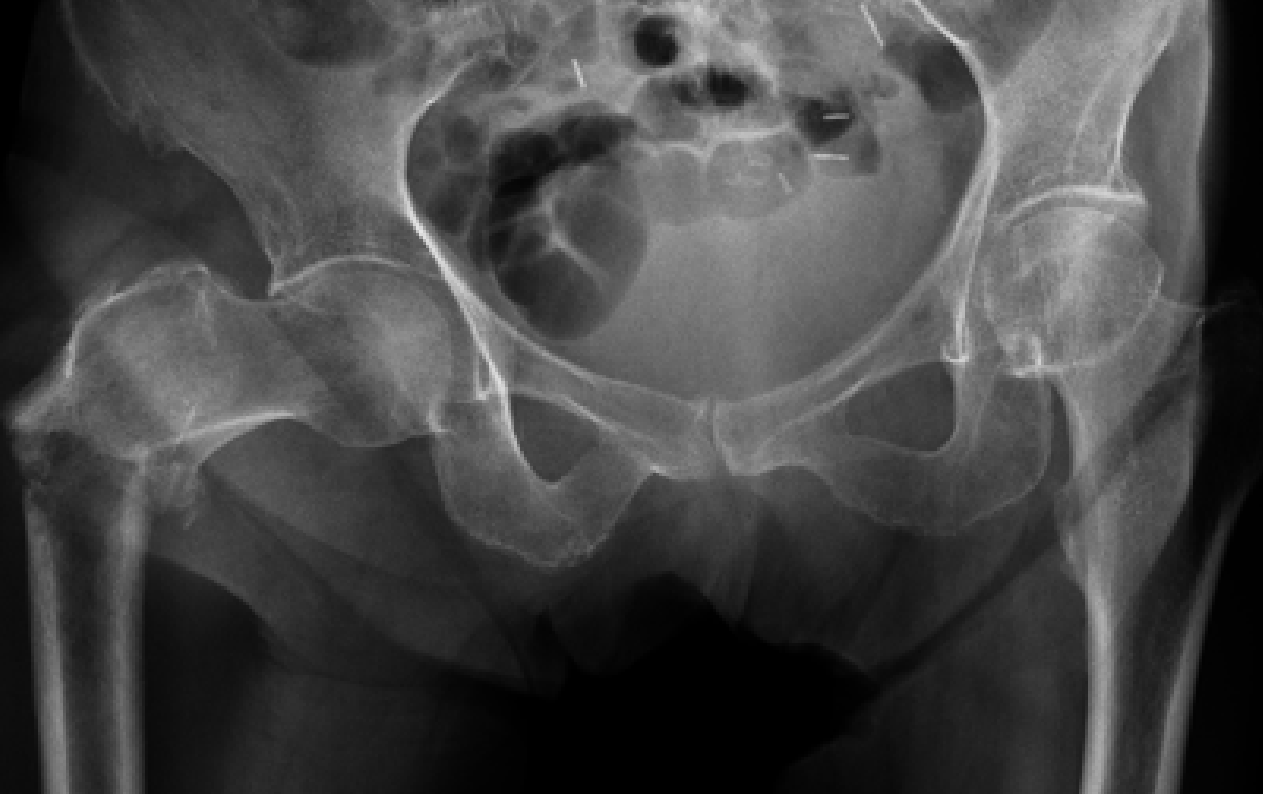GE



Compressione 1

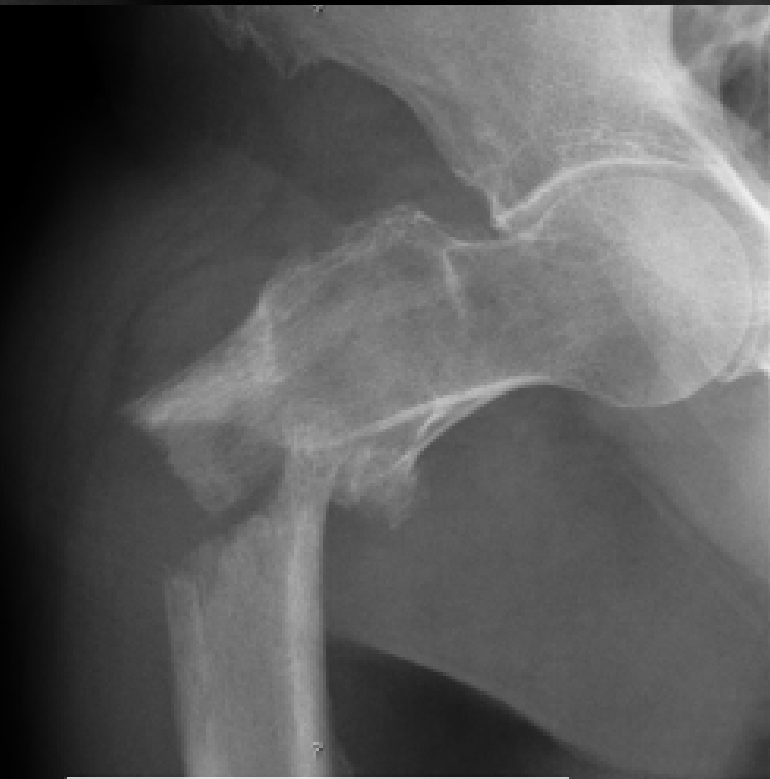
Compressione 2

D



ID: 1881908  
DOB: 1921-01-18  
2012-10-10  
09:53:16  
No. 1

D



DR: 9000

7

7

C: 2048  
W: 4096



**GRAZIE PER  
L'ATTENZIONE**

**DALLA MEDURG DI  
PINEROLO**

