

Congresso Nazionale SIMEU

Rimini 20 ottobre 2012

Dolore toracico… perle e tranelli ECG

Enrico G. Ruggiero

Medicina d'Urgenza e Pronto Soccorso
Ospedale S. Paolo Napoli

Direttore F. Schiraldi



nella vita reale…

Edward S. in P.S. per dolore toracico

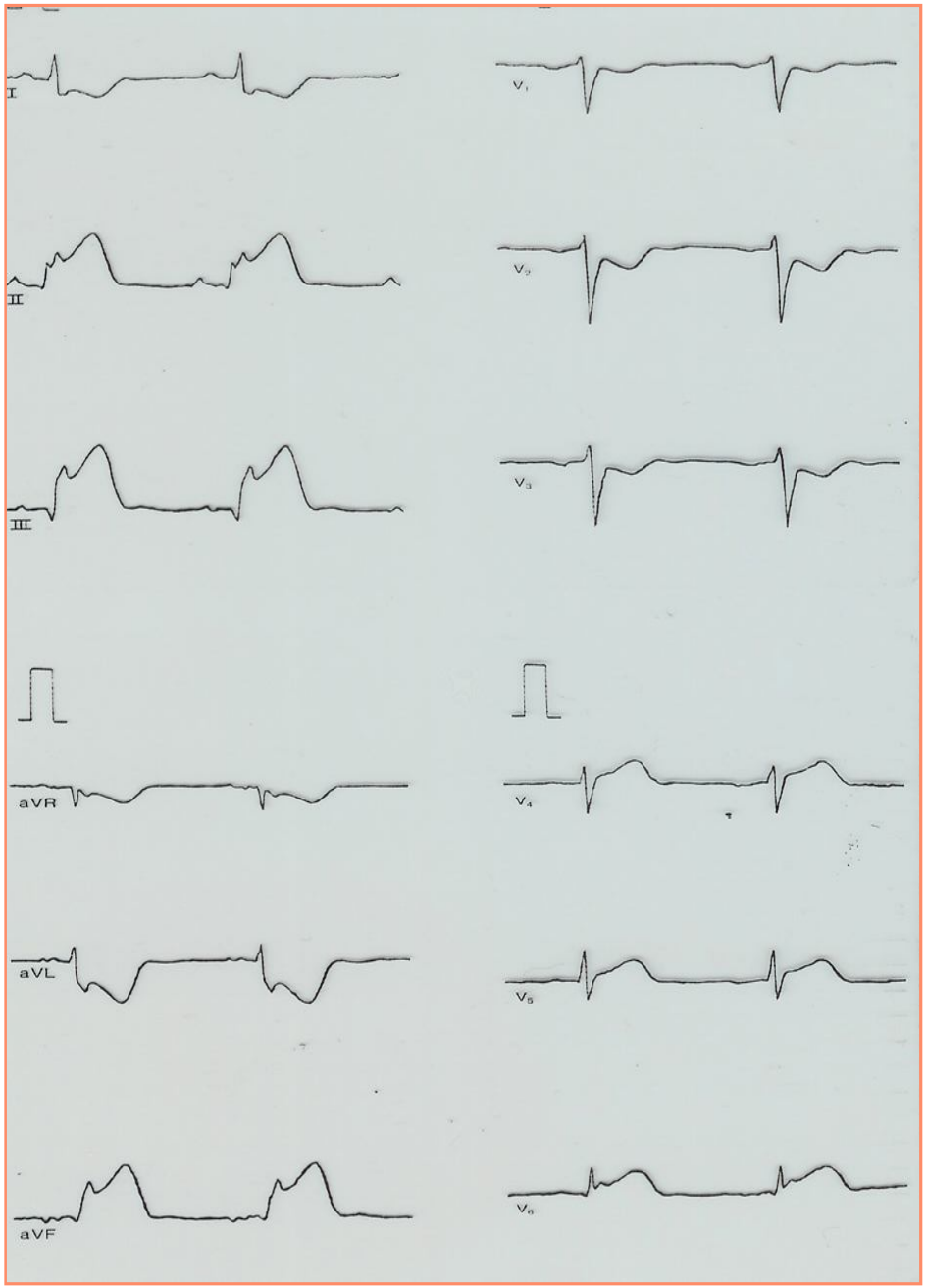

S.C.A.

necrosi transmurale parete inferiore

TROPONINA T	0,071	*
CK-MB massa	9,6	*
MIOGLOBINA	178,7	*

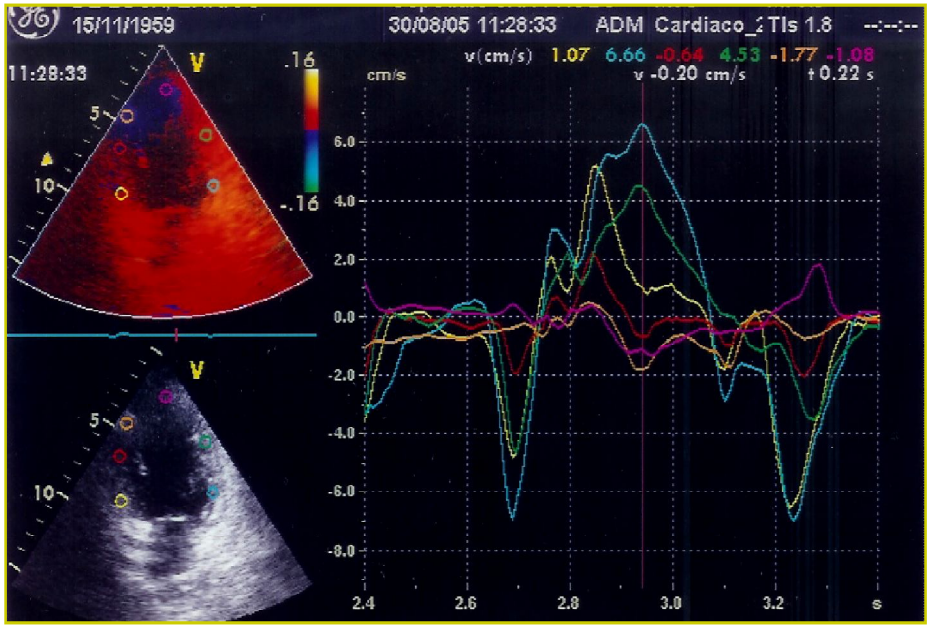

Sandro T. in P.S. per dolore toracico

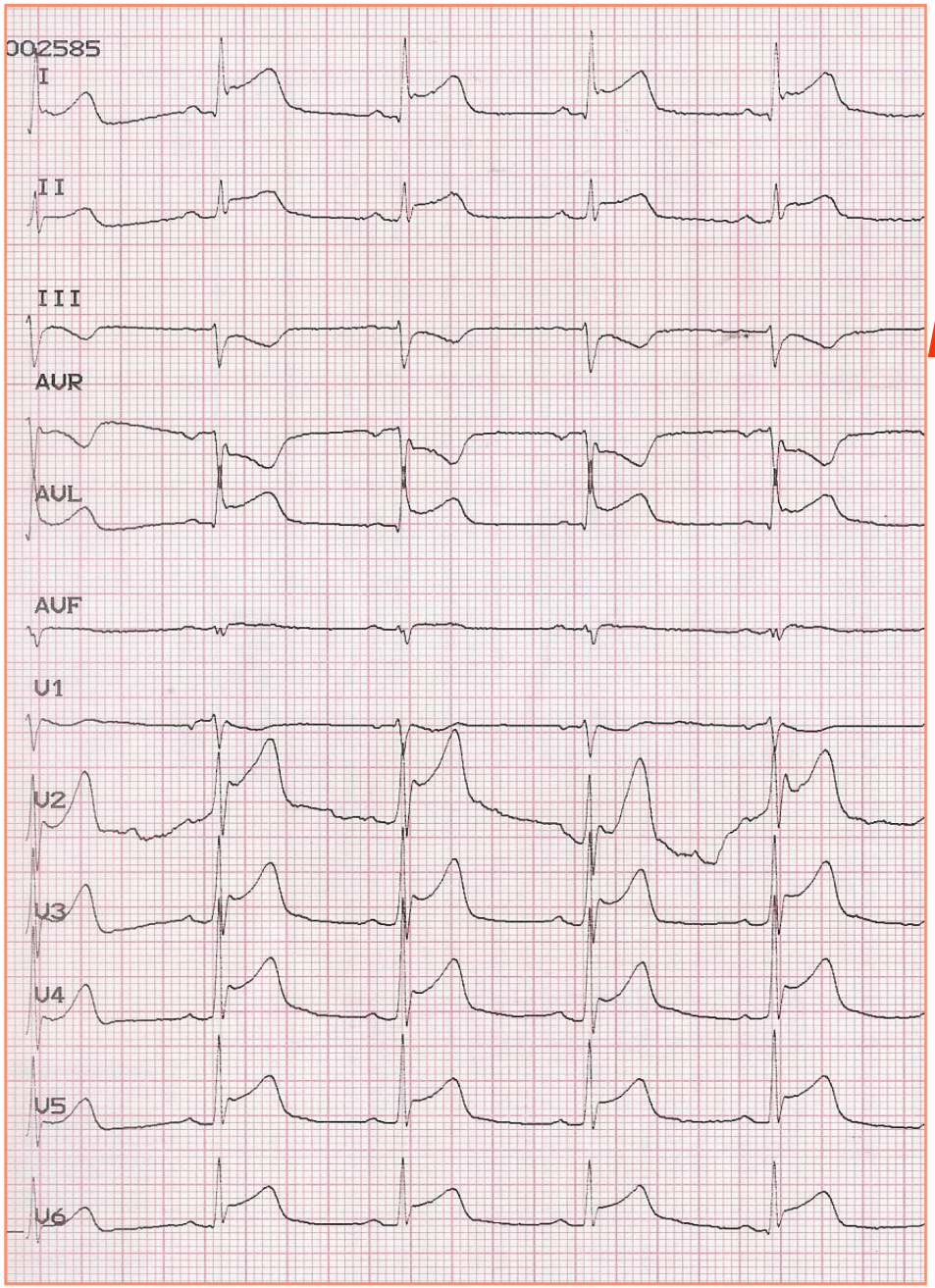

PERICARDITE

PATOLOGIA NON ASCRIVIBILE alla S.C.A.

TROPONINA T	0,089	*
CK-MB massa	4,9	
MIOGLOBINA	85,9	*

Sandro T. dolore toracico…in P.S.

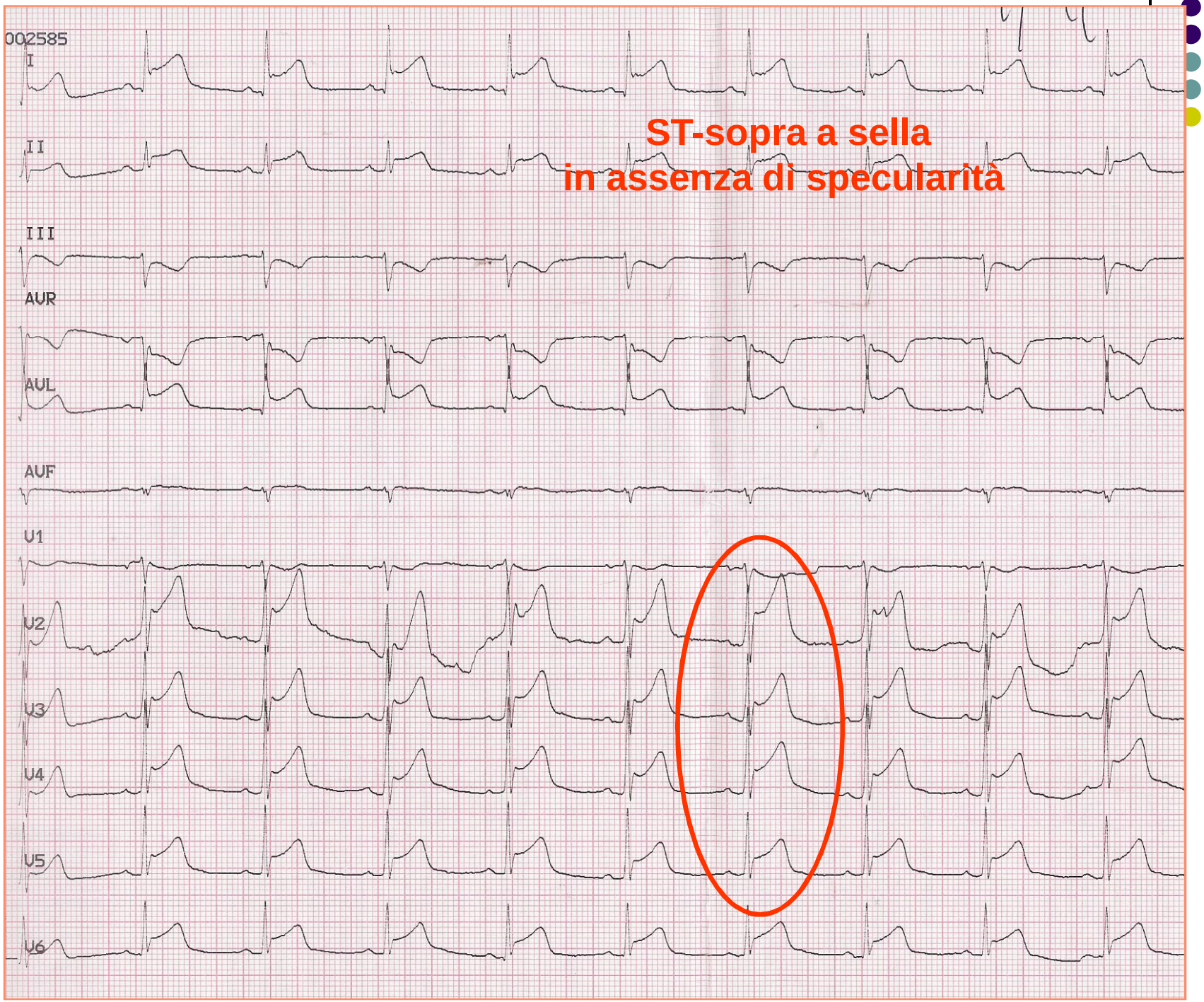

Sandro T. *dolore toracico…in P.S.*

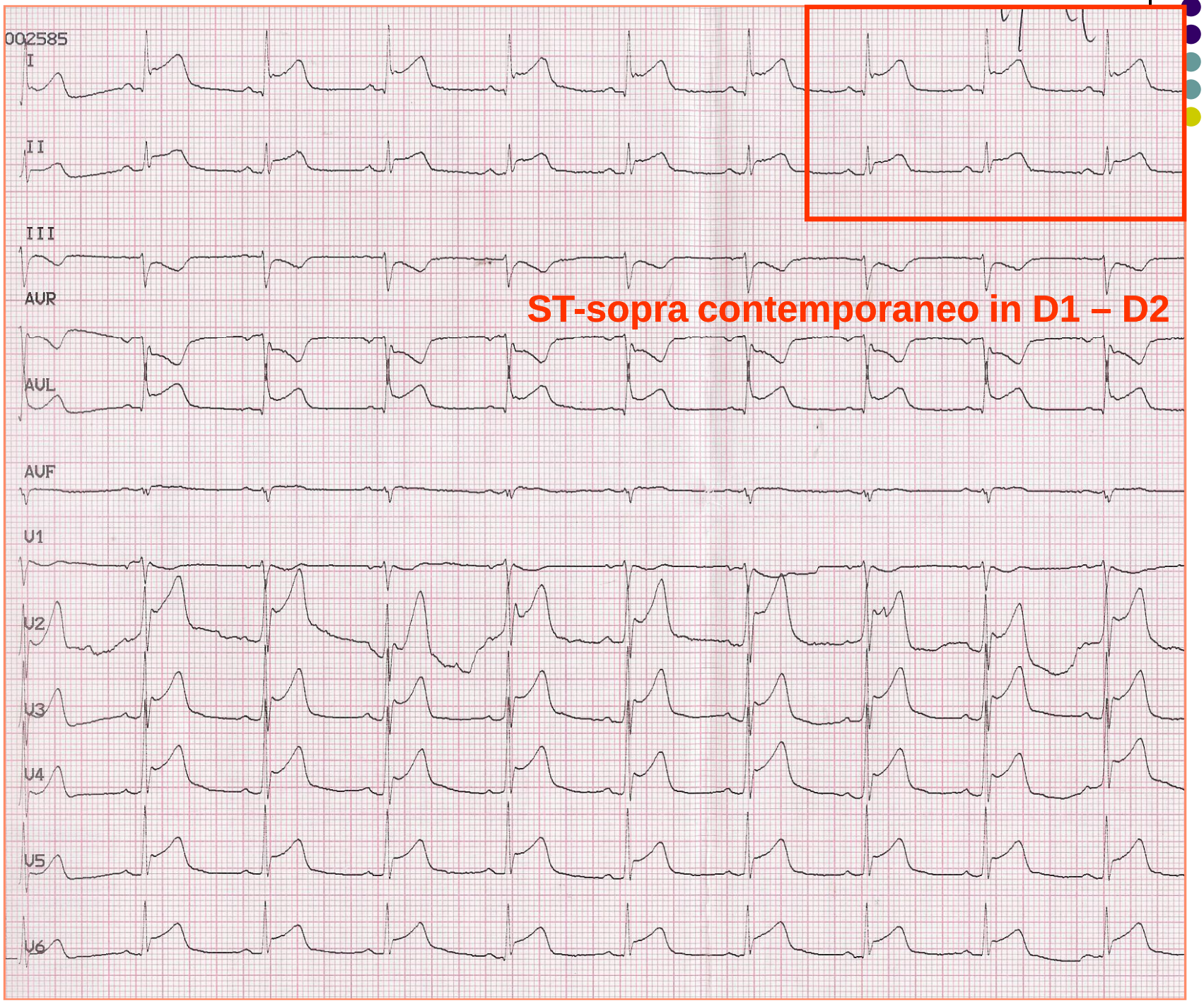

Sandro T. dolore toracico…in P.S.

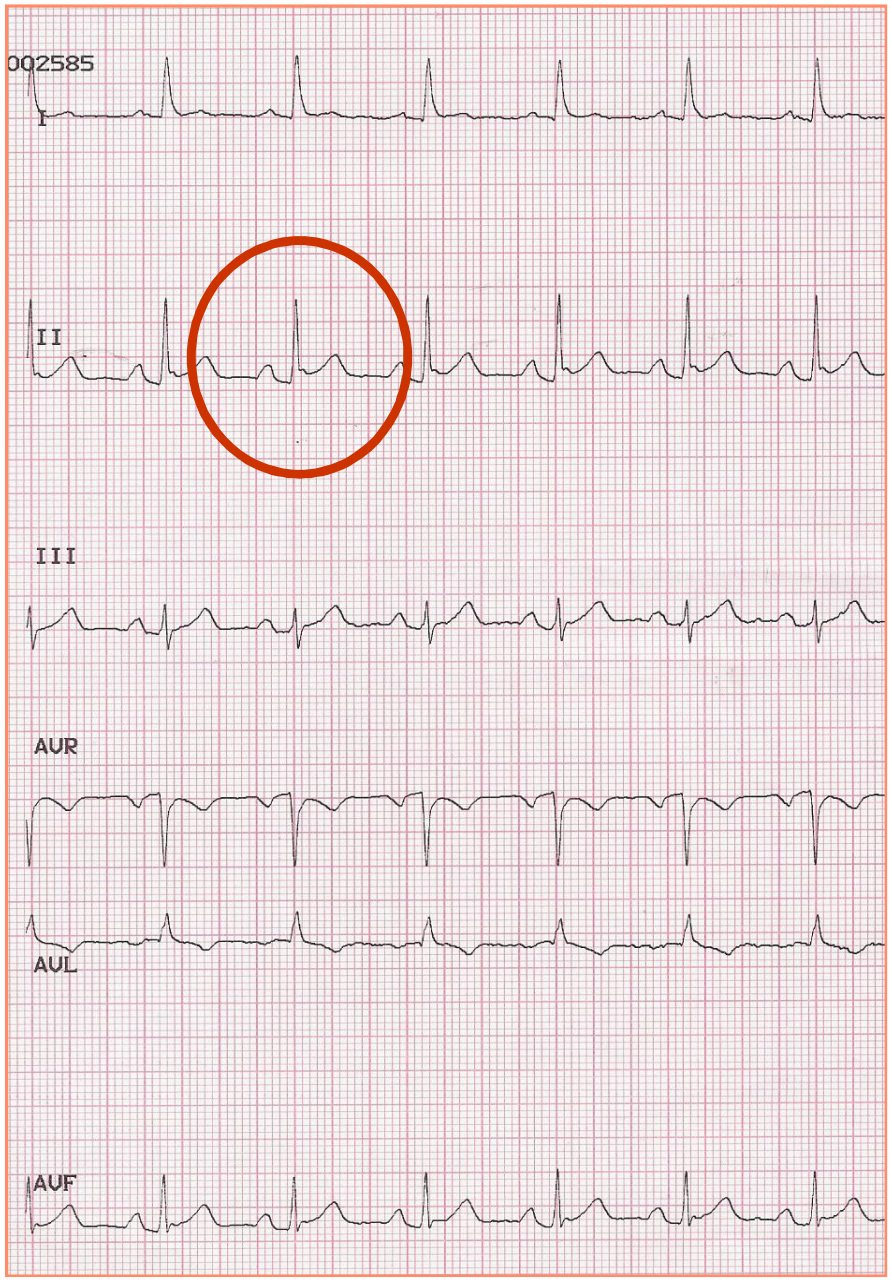

…segmento PR sottolivellato

Sandro T. dolore toracico…in P.S.

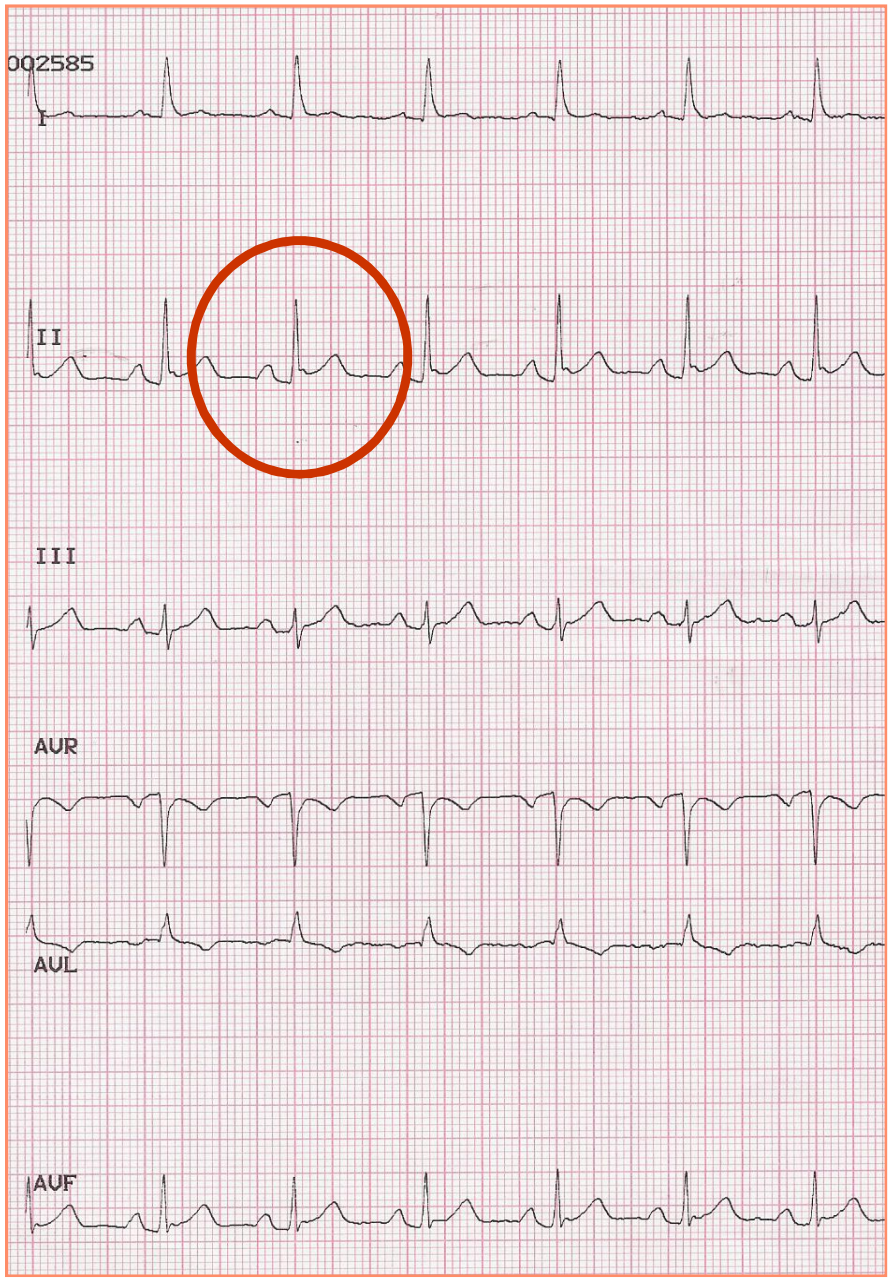

…segmento PR sottolivellato

…flogosi foglietti pericardici

Andrea P. in P.S. per dolore toracico

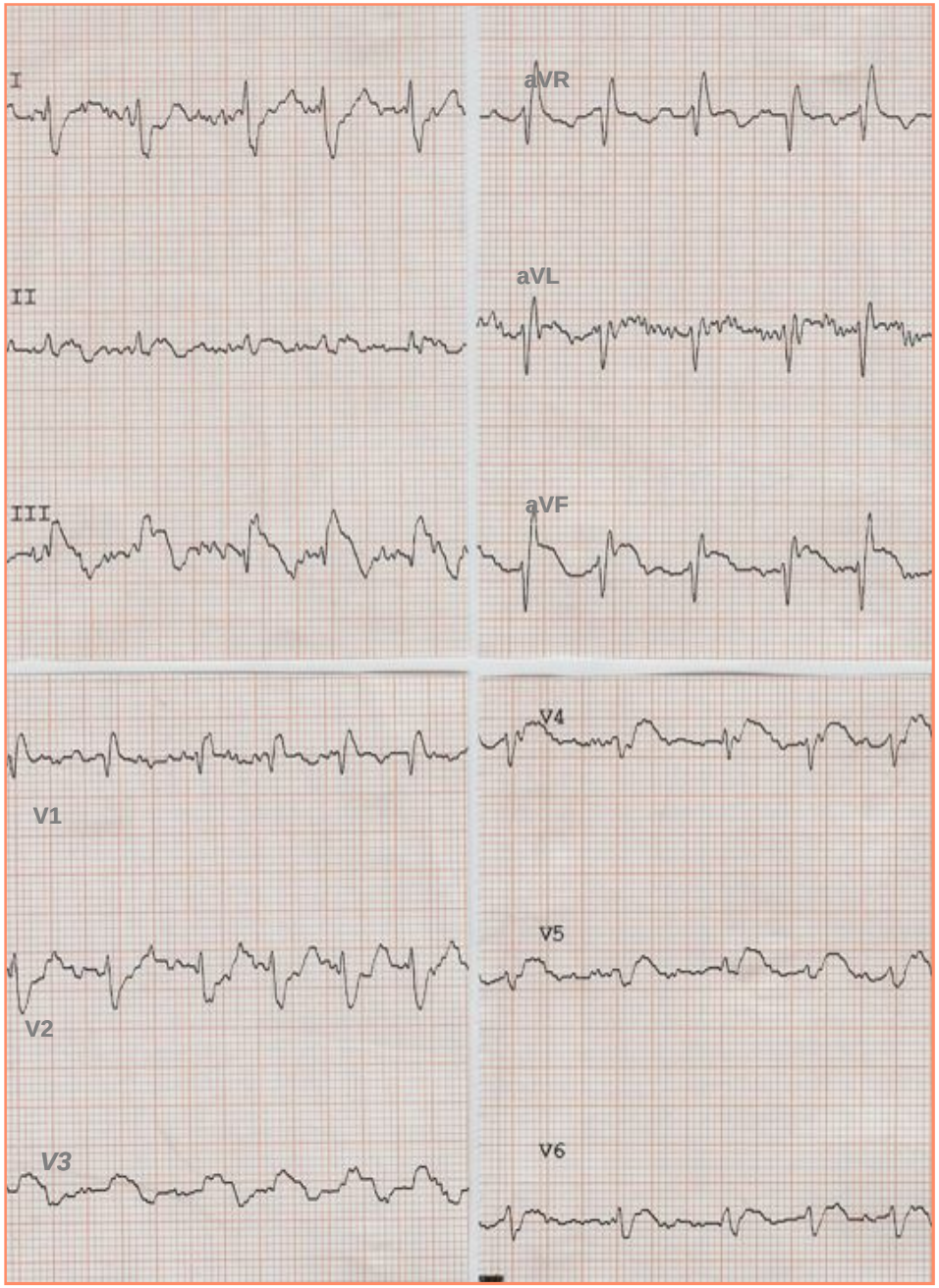

CPK	139	
TROPONINA T	0,172	*
CK-MB massa	7,5	*
MIOGLOBINA	61,6	

polipnea

rantoli basali

ST EMI inferiore + BBDx

classe emodinamica di esordio Killip 2

pH	7.491↑
pCO2	28.9↓
pO2	42.0↓
HCO3-att	21.6
HCO3-std	23.6
ctCO2	22.5
BE(B)	-0.6
BE(ecf)	-1.7

delta (A-a)O2 =72

tHb	13.3
Hct	39
ctO2(a)	15.1
BO2	18.4
pO2	42.0
p50	27.2
sO2	81.1
O2Hb	80.7
COHb	0.1
MetHb	0.4
HHb	18.8

ELETTROLITI

Na+	135.9
K+	4.18
Ca++	4.7
Ca++(pH 7.4)	4.9
Cl-	112
Gap Anionico	6.5

ATTIVITA' PROTROMBINICA	91
INR	1,08
PTT	28
RATIO	0,94
D.DIMERI	4655
UREA	40
GLUCOSIO	95
CREATININA	0,93

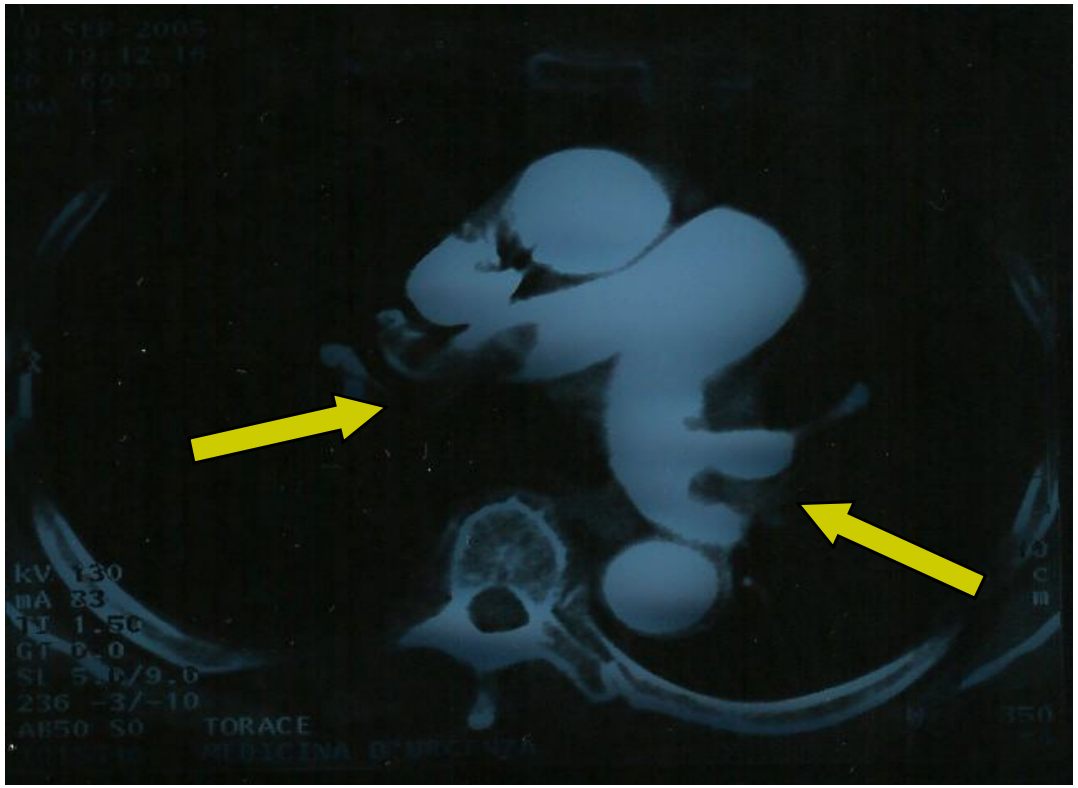

TROMBO EMBOLIA POLMONARE

PATOLOGIA NON ASCRIVIBILE alla S.C.A.

Andrea P. in P.S. per dolore toracico

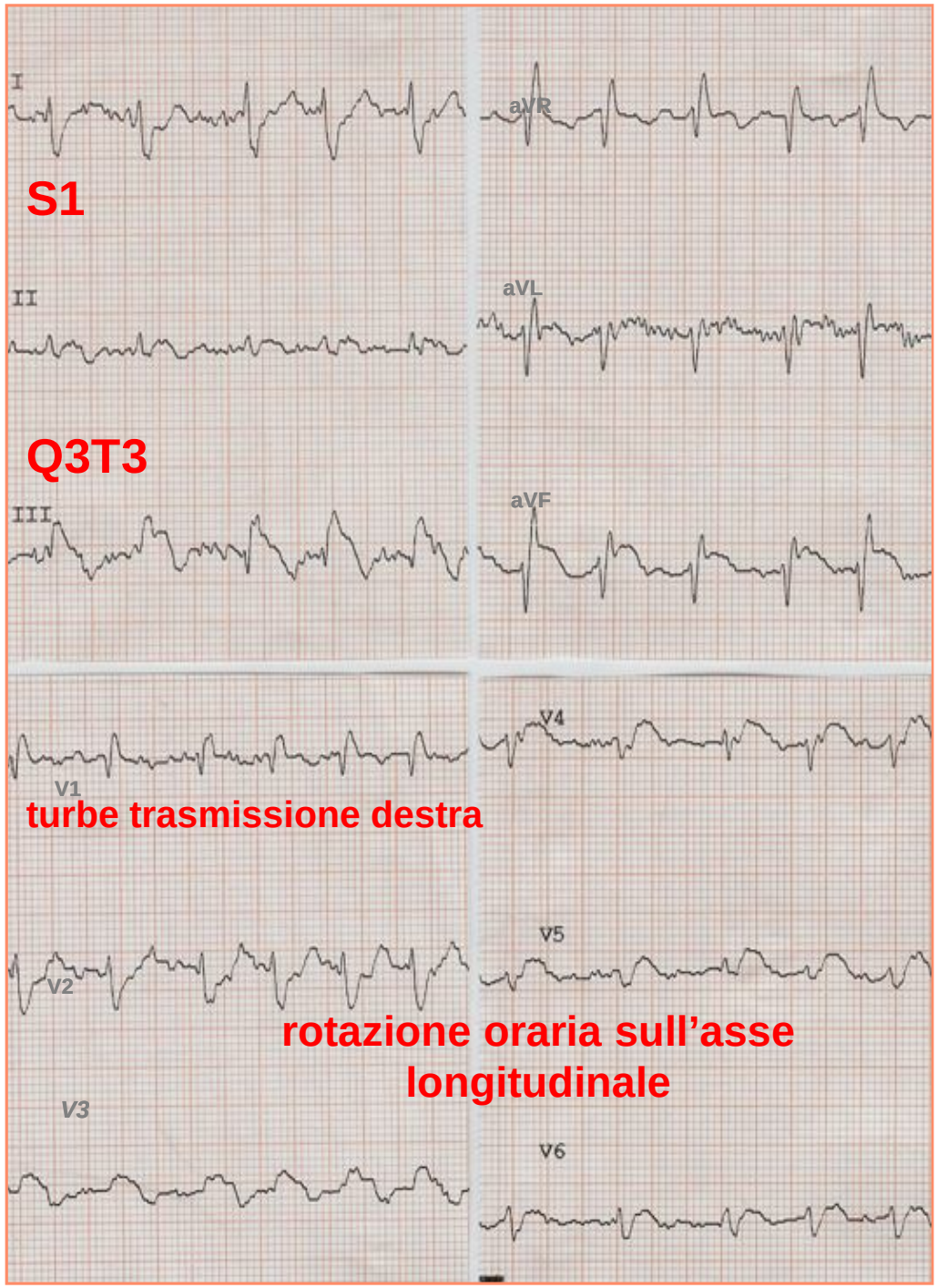

CARICO DI LAVORO VENTRICOLO DESTRO

Gestione del dolore toracico in PS

- Il 2-10% degli IMA è rinviato a casa, senza che sia stata riconosciuta la patologia.

… INFARTI NON RICONOSCIUTI IN P.S.

nel 12% dei casi per mancata esatta interpretazione dell'ecg

Glibler WB. Ann Emerg Med 1990; Mc Carthy BD. Ann Emerg Med 1993; Duncan DB. Cardiology 1996.

Pope JH et al: Missed diagnoses of acute cardiac ischemia in the ED N Engl J Med 2000; 342: 1163-70 (retrospettivo, multicentrico, 10.689 pz)

IMA non diagnosticato
(4% del totale)

Errori per:

- **Giovane età del pz**
- **Presentazione atipica dei sintomi**
- **Ecg non diagnostico (20%)**
- **Ecg sottostimato o mal eseguito (25-40%)**
- **Dimissione basata su singolo valore di enzima**
- **Dimissione basata sulla risposta all'antiacido**

Ann. Emerg Med; 1989; 18:1029-1034.
N EnglJ Med 2000; 342: 1163-70

Caratteristiche ECG nell'infarto miocardico acuto

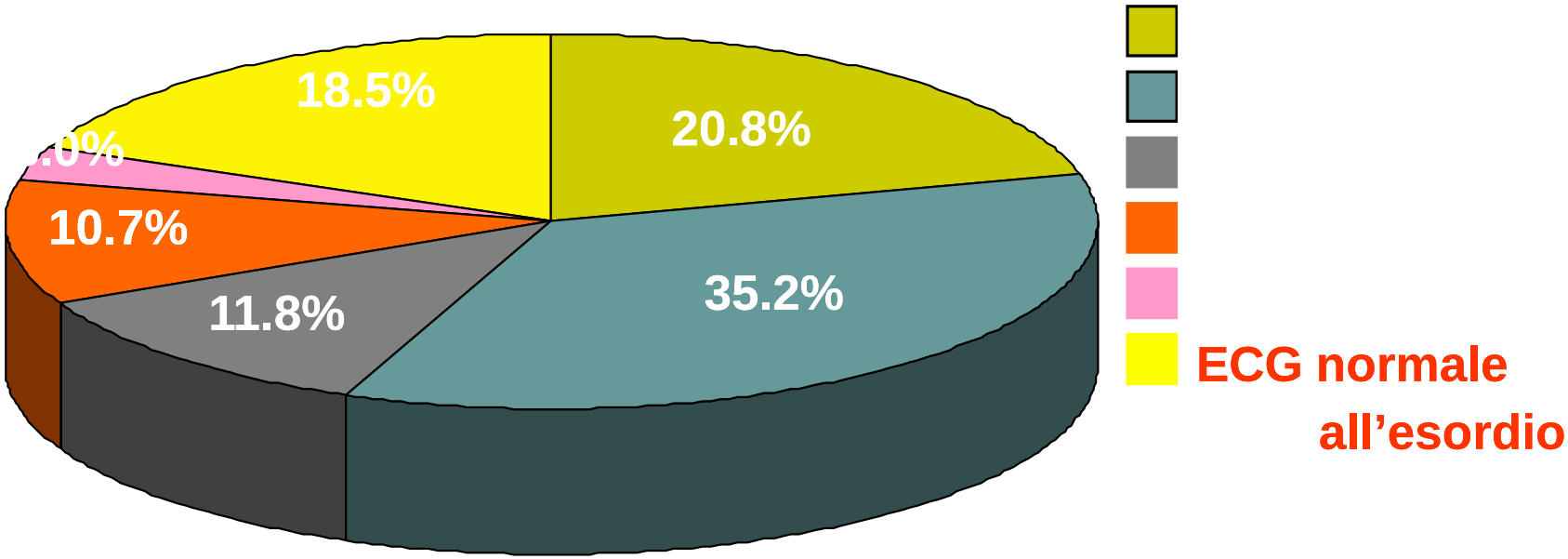

Miller et al. Am J Cardiol 2001; 87: 1045-50

3492

...linee guida condivise

TasK-Force on Pratice Guidelines

A.C.C. – A.H.A. – E.S.C. – SIMEU - FIC

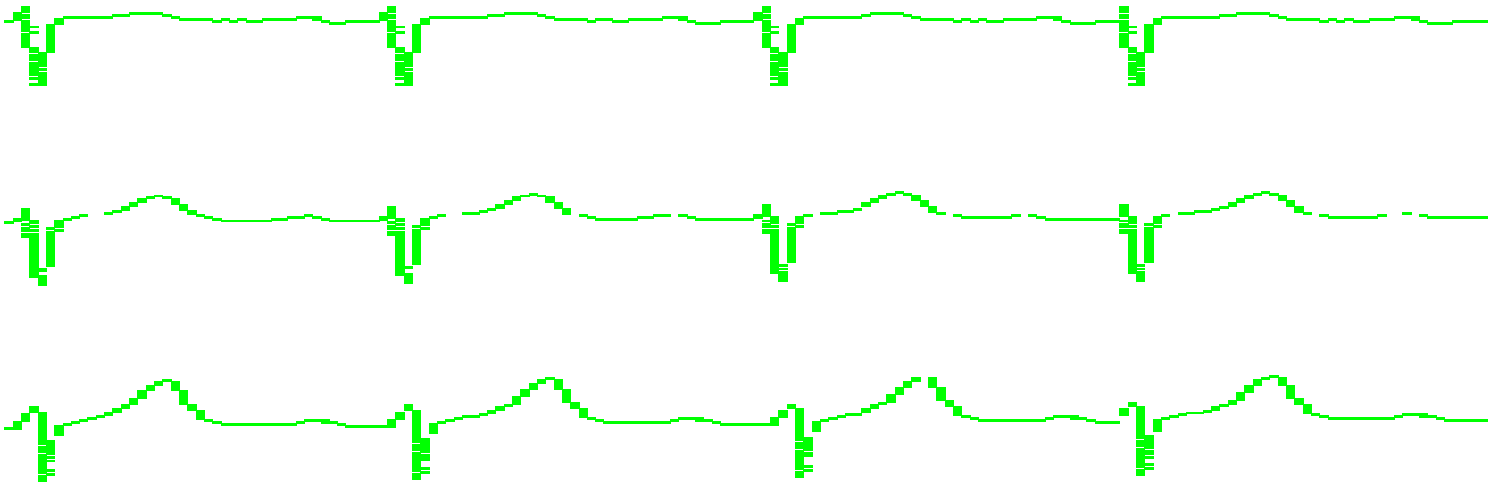

…attenta lettura dell'ecg di superficie

PUNTI LUCE

piccoli tranelli

perle preziose

consigli utili





…che disastro



attenzione…
entriamo nel dettaglio

tutti sanno che…

ST-EMI

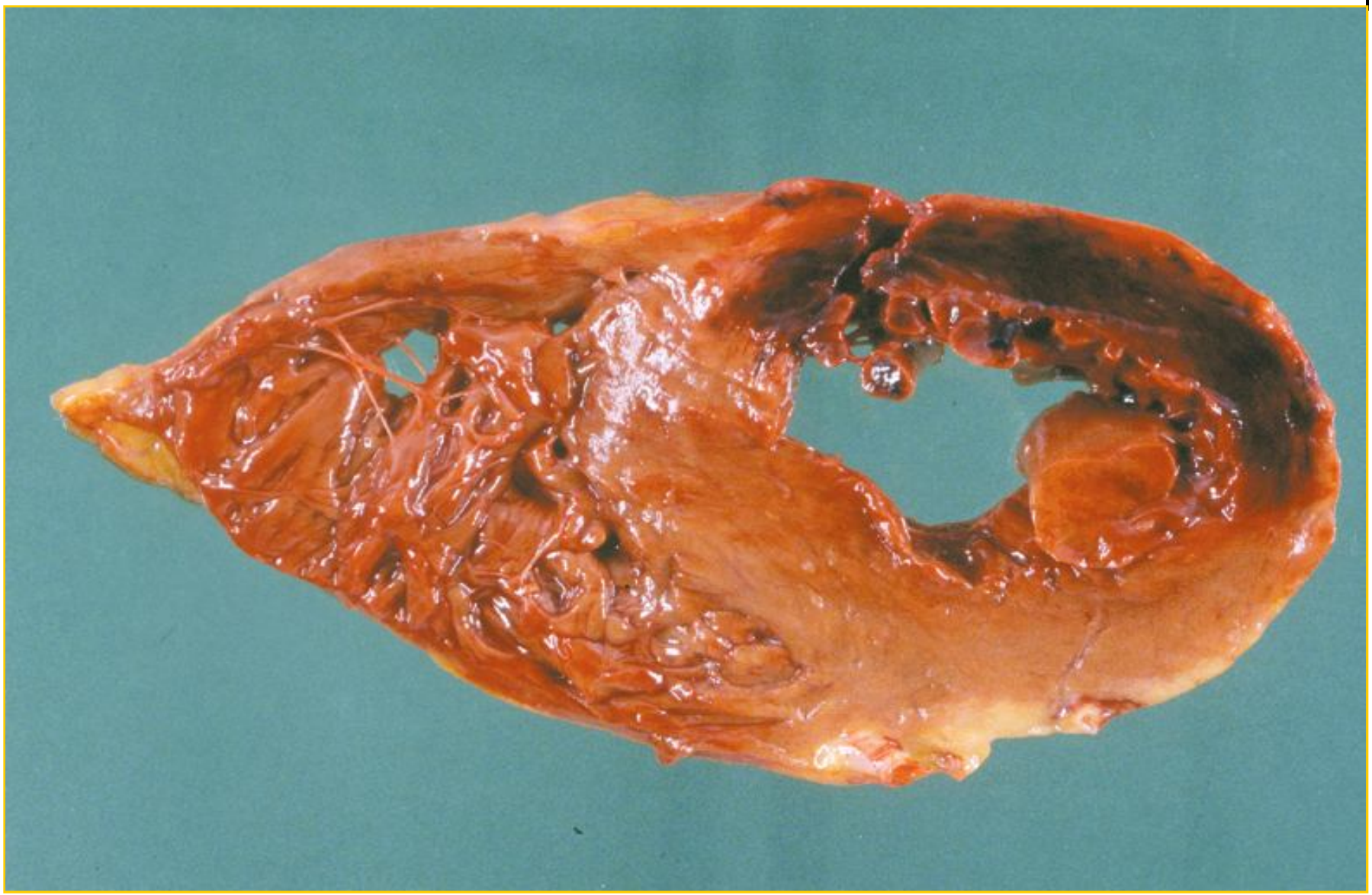

nei primi minuti di uno stato ischemico protratto…

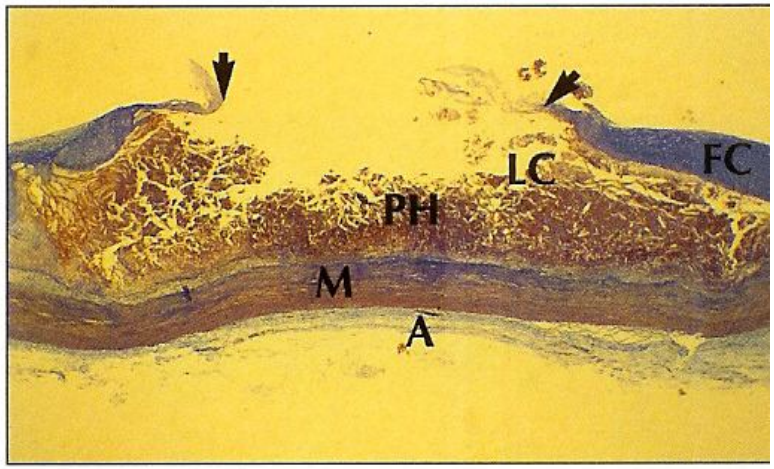

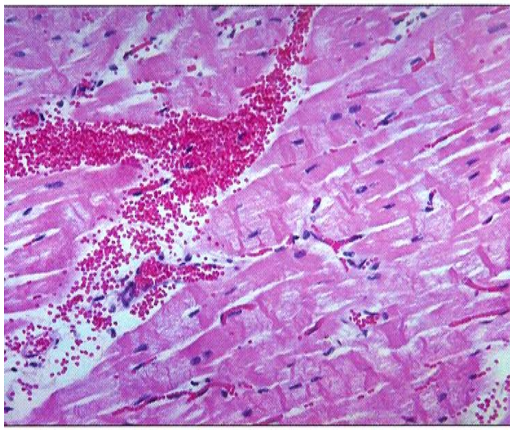

modificazioni di flussi ionici polarizzanti di membrana…

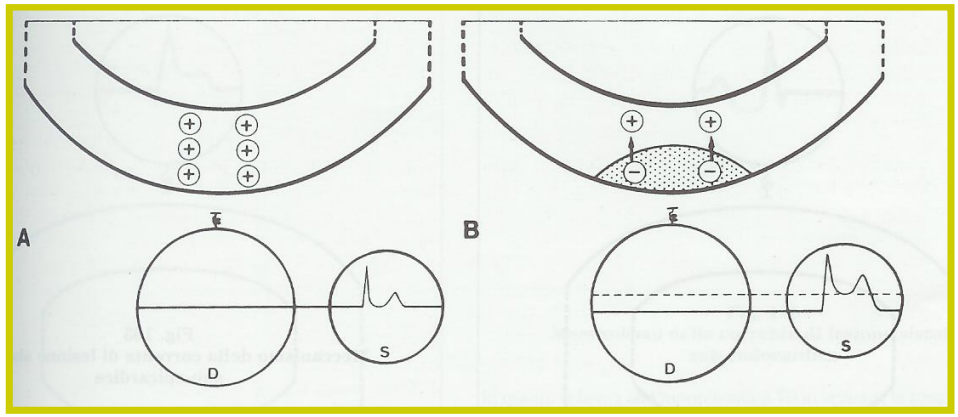

nei primi minuti di uno stato ischemico protratto…

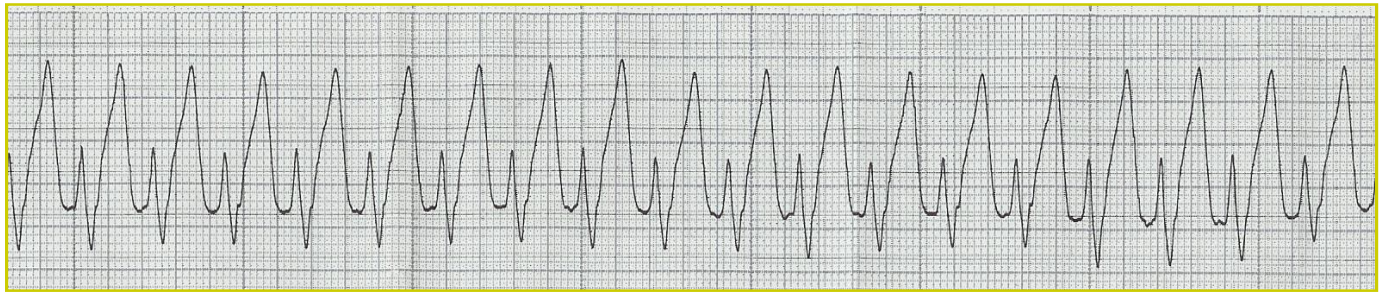

onda T "aguzza"

onda monofasica Smith-Pardee

…specularità
sensibilità 96%
specificità 90%

…nelle ore successive

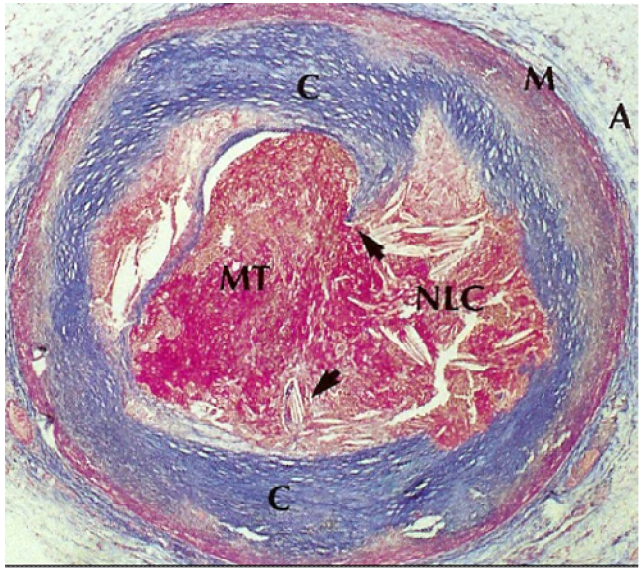

... nel danno transmurale

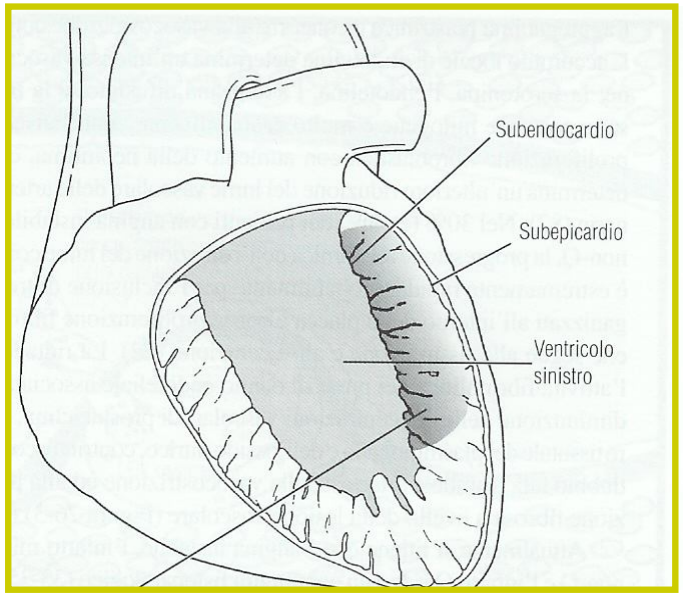

per necrosi coagulativa cellulare…

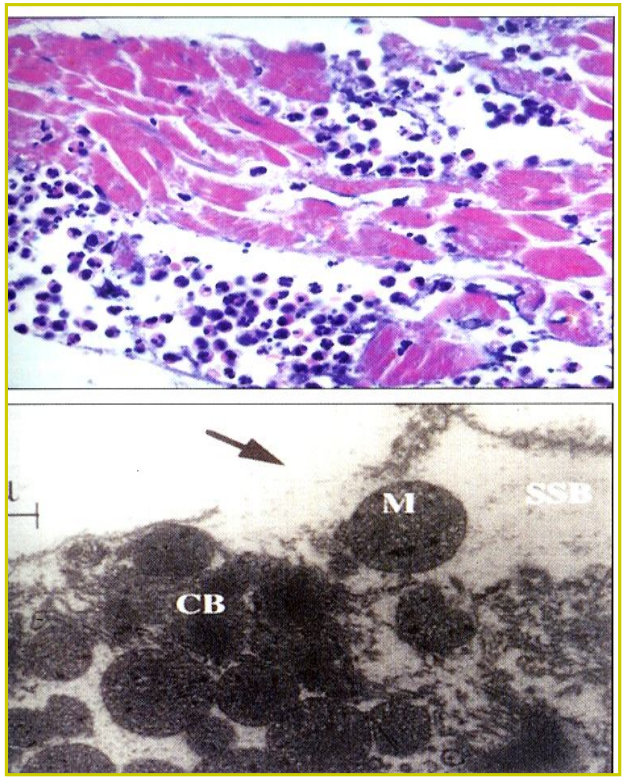

…nelle ore successive

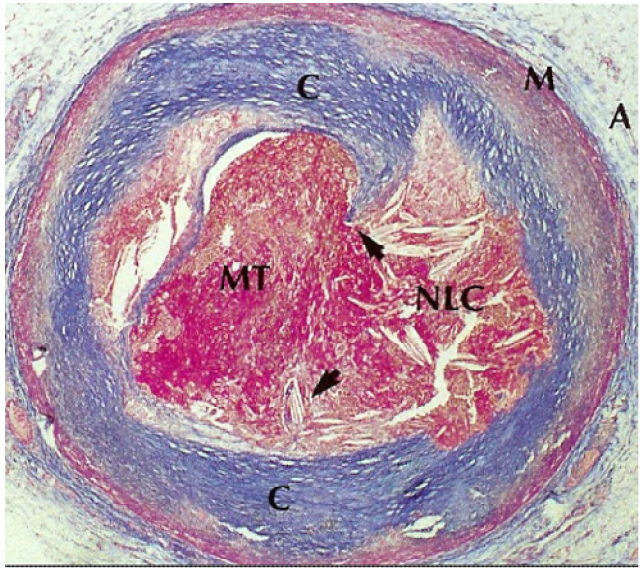

... nel danno transmurale

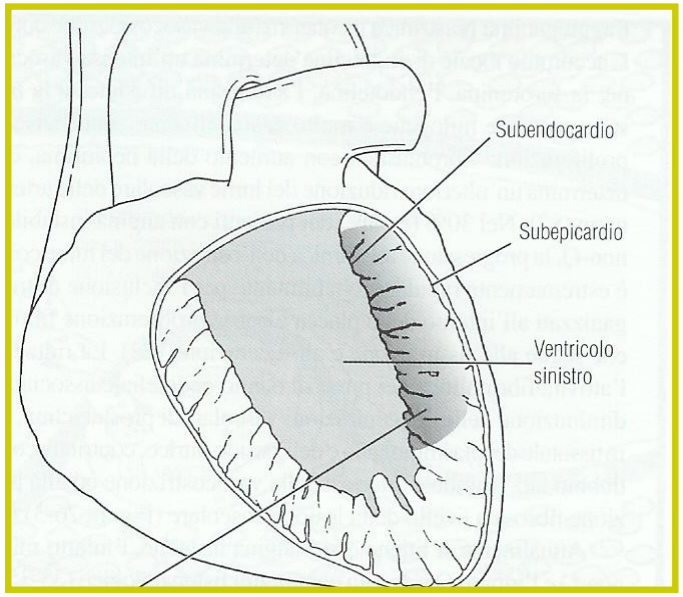

per necrosi coagulativa cellulare…

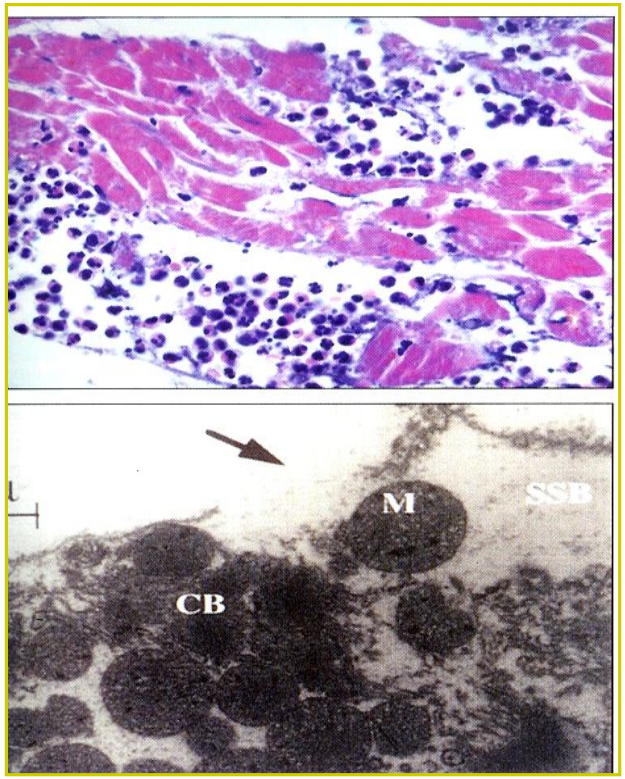

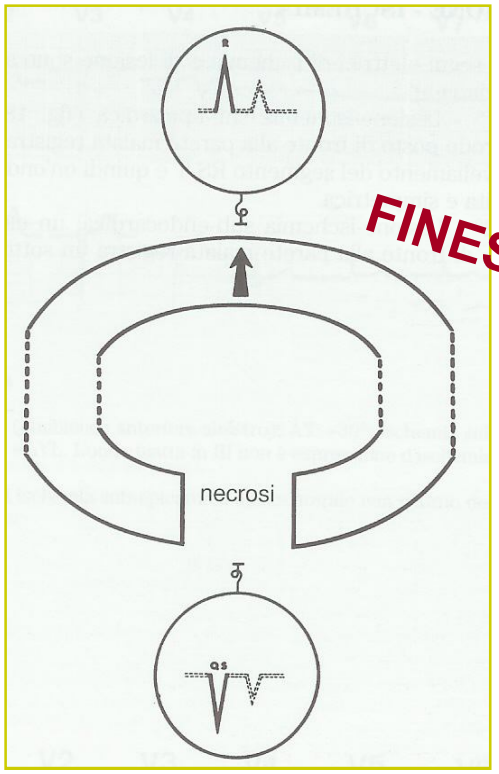

FINESTRA ELETTRICA

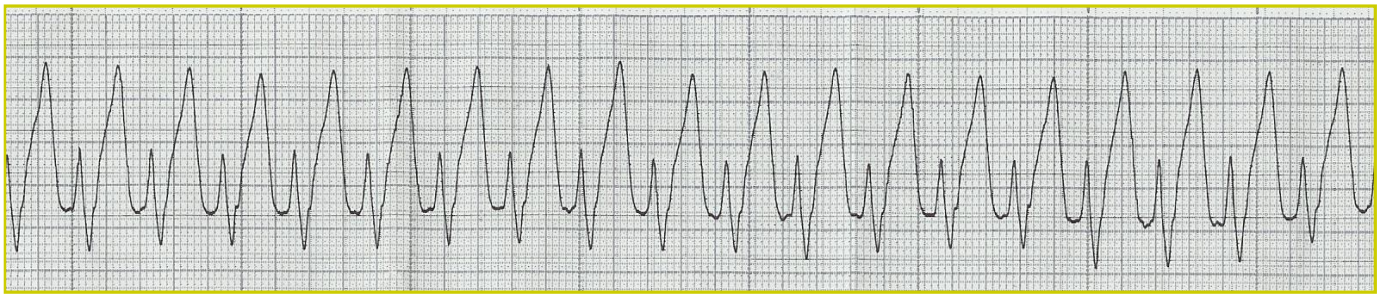

onda monofasica

Smith-Pardee

…dopo alcune ore

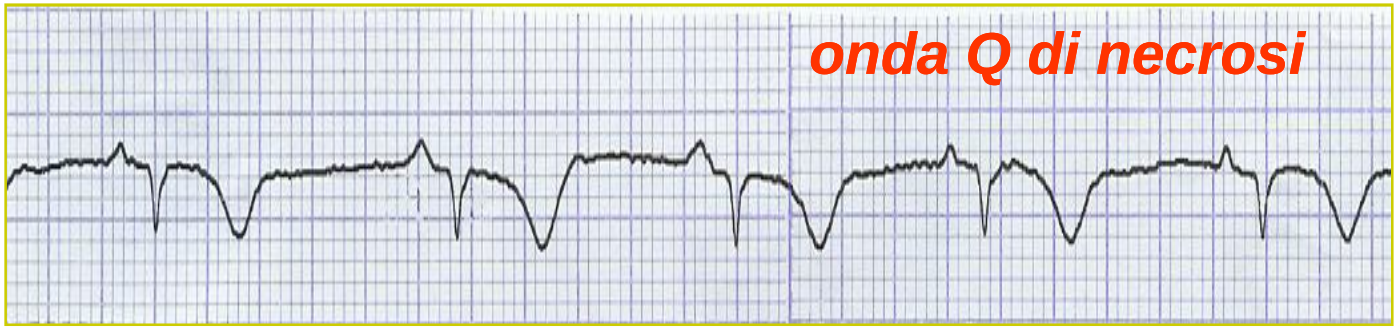

onda T coronarica
Pardee

e tutti sanno anche che…

…è possibile identificare la coronaria lesa

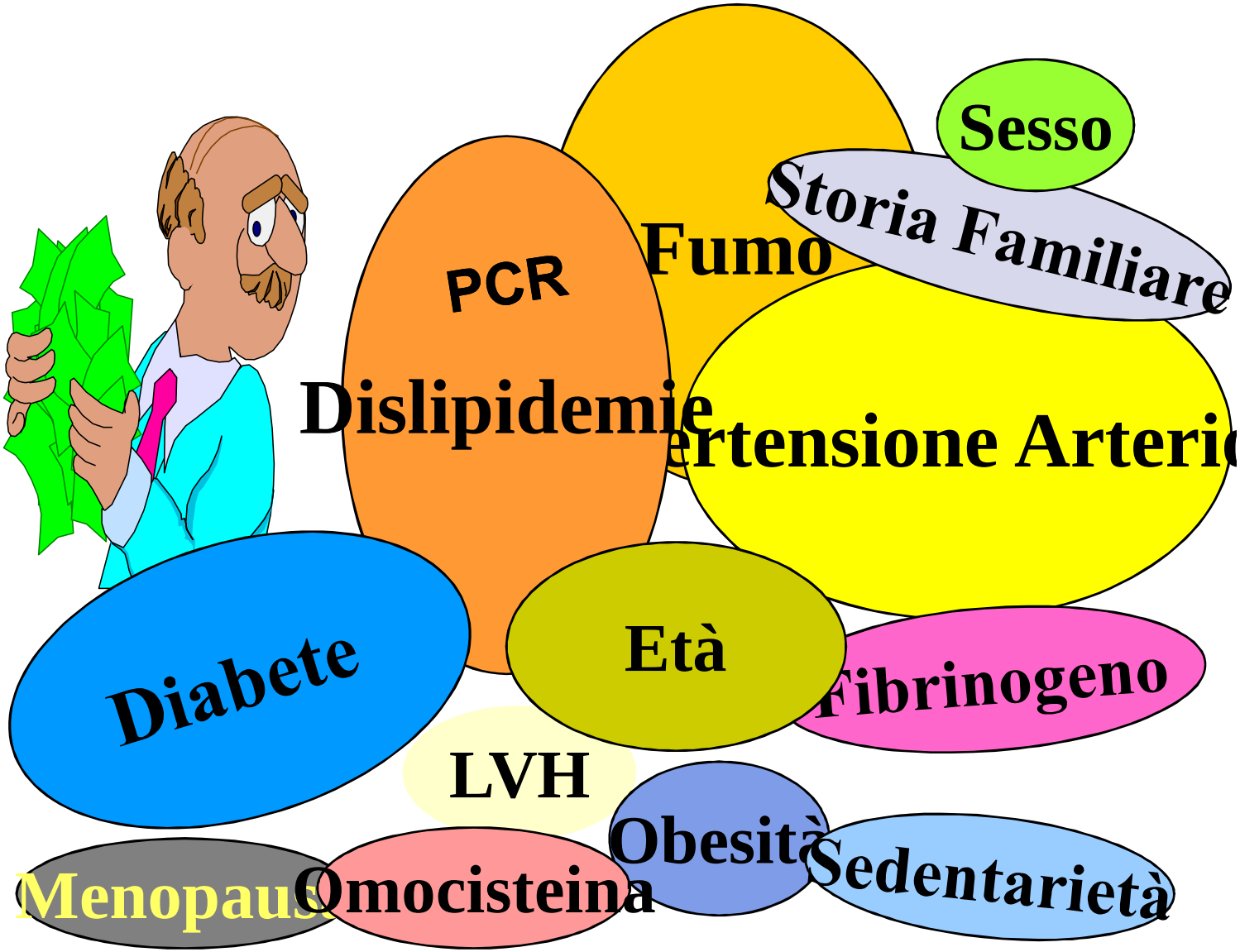

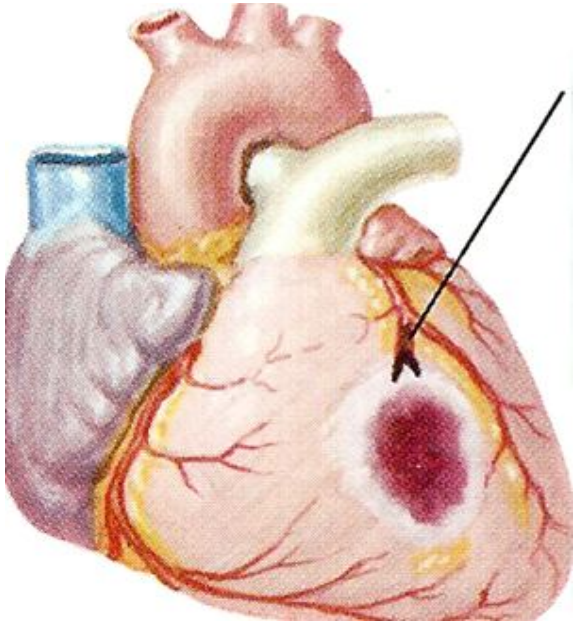

ST EMI settale

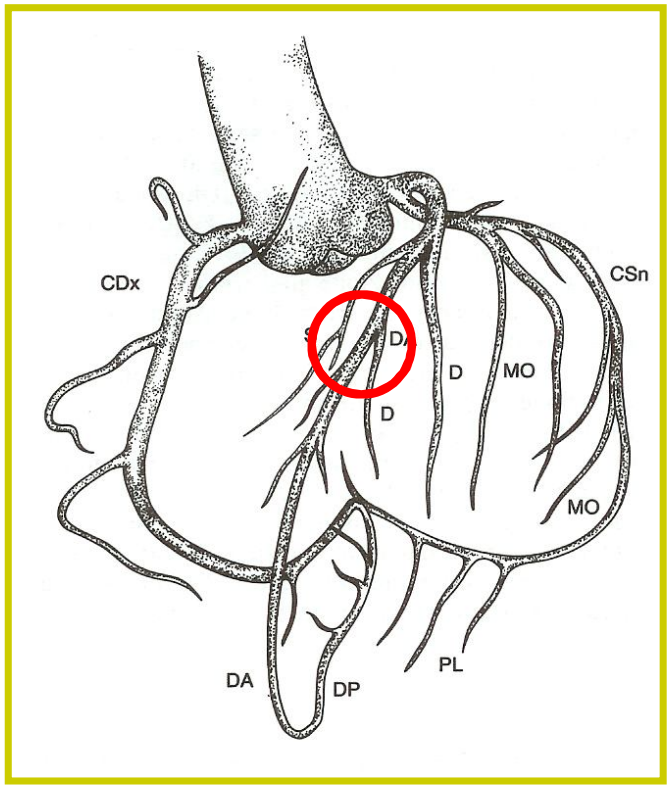

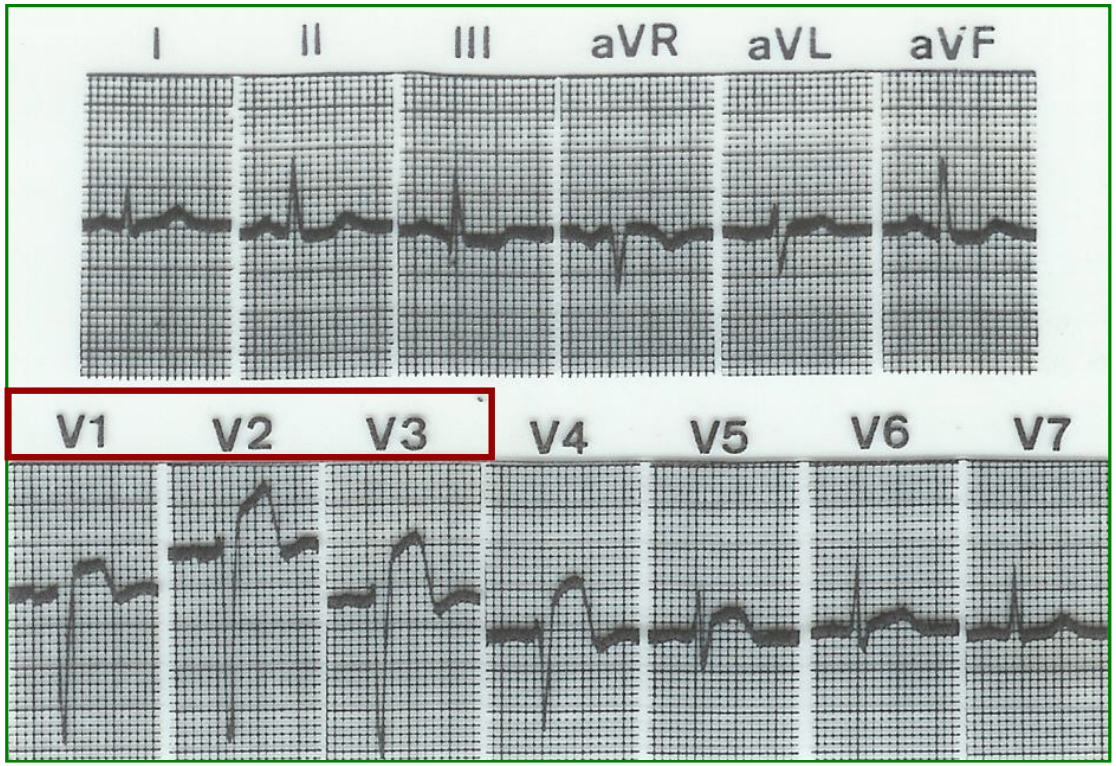

…rami settali/diagonali discendente anteriore

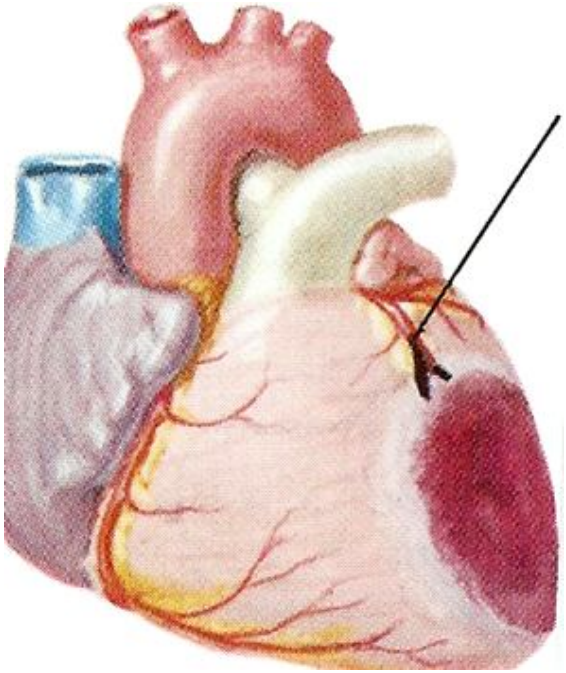

ST EMI antero-laterale

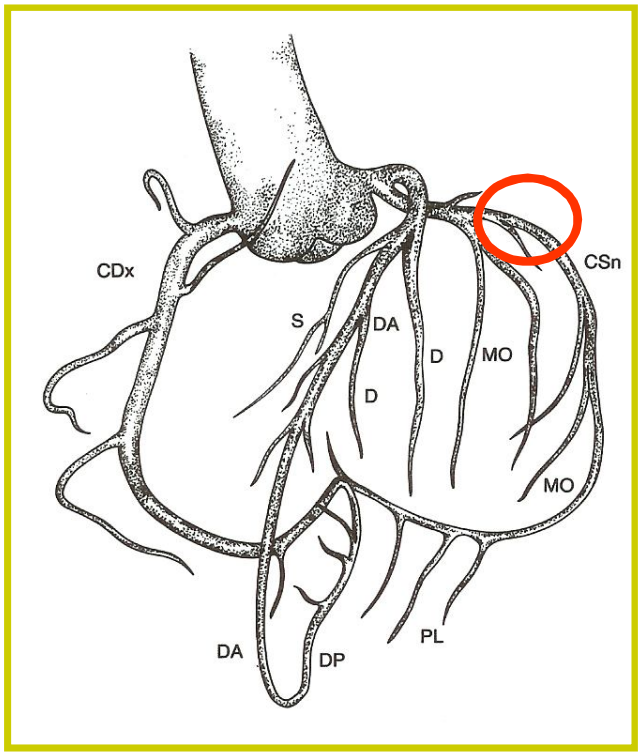

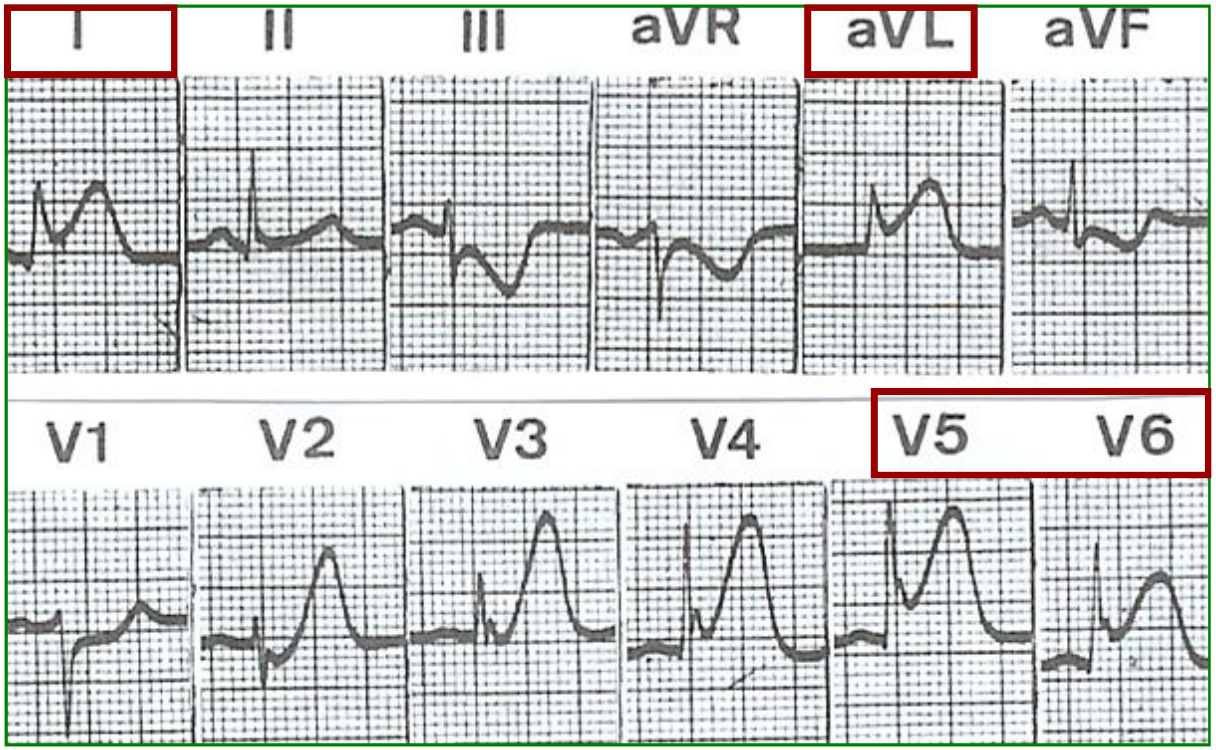

…circonflessa sx

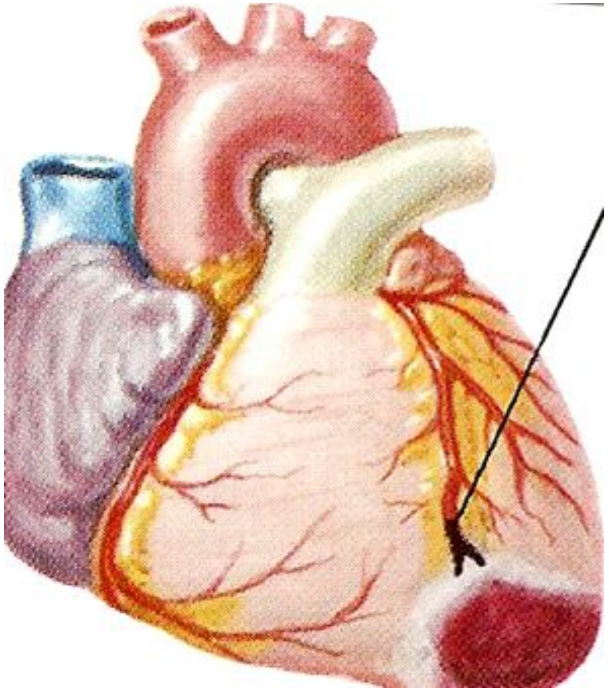

ST EMI punta

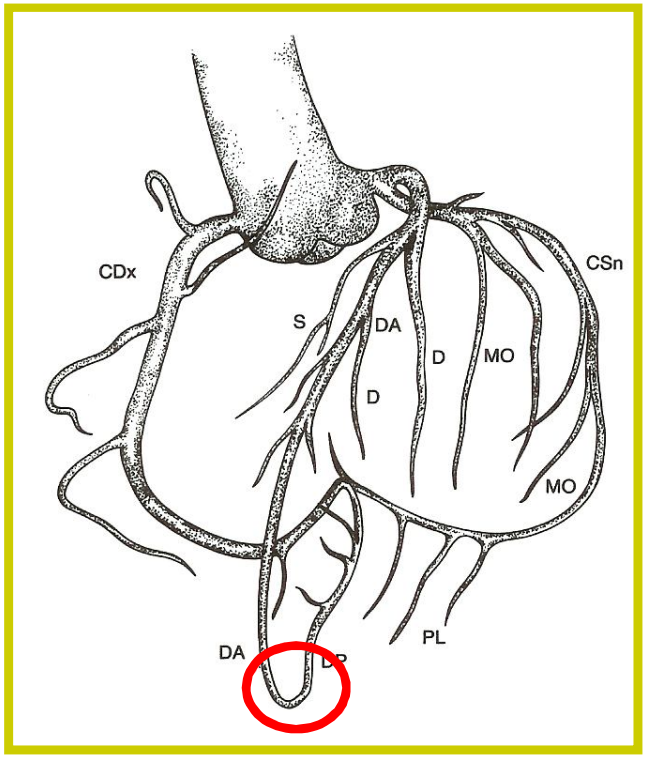

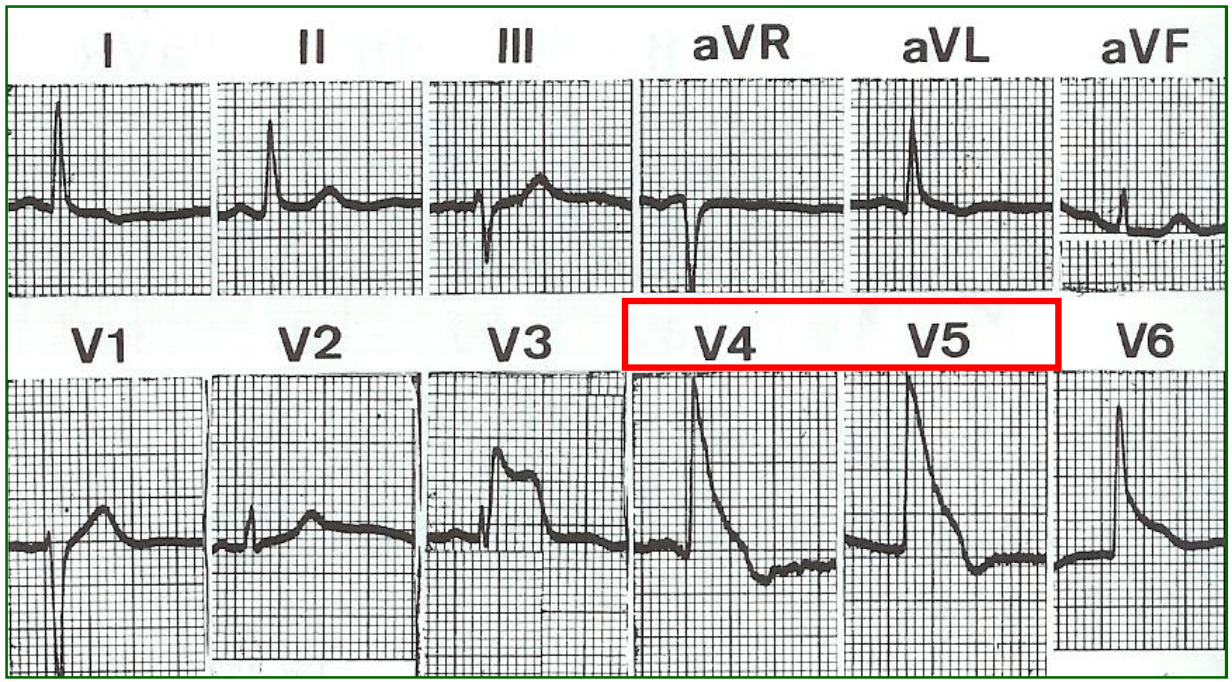

…ramo ricorrente posteriore IVA

ST EMI inferiore

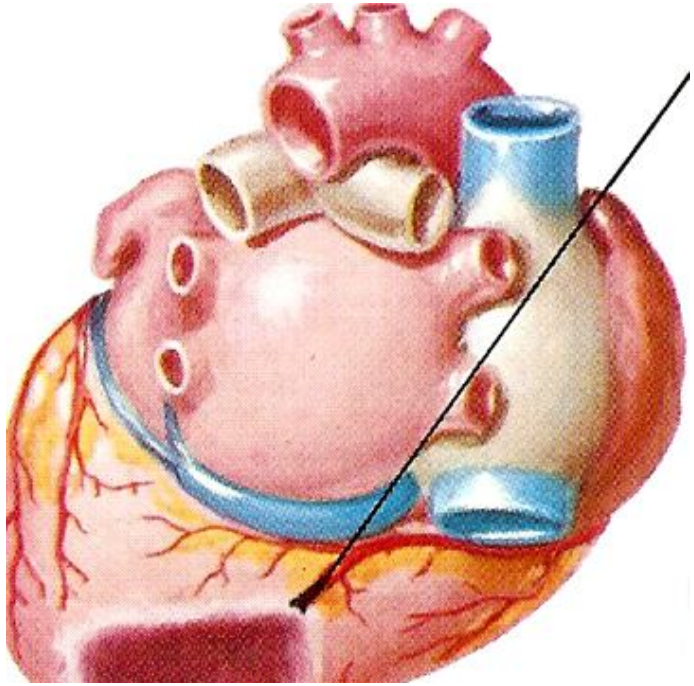

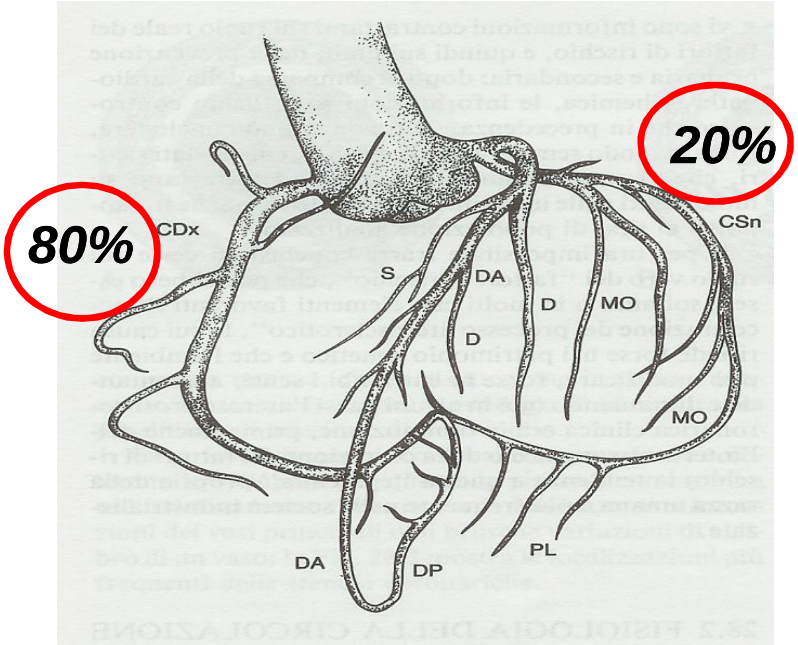

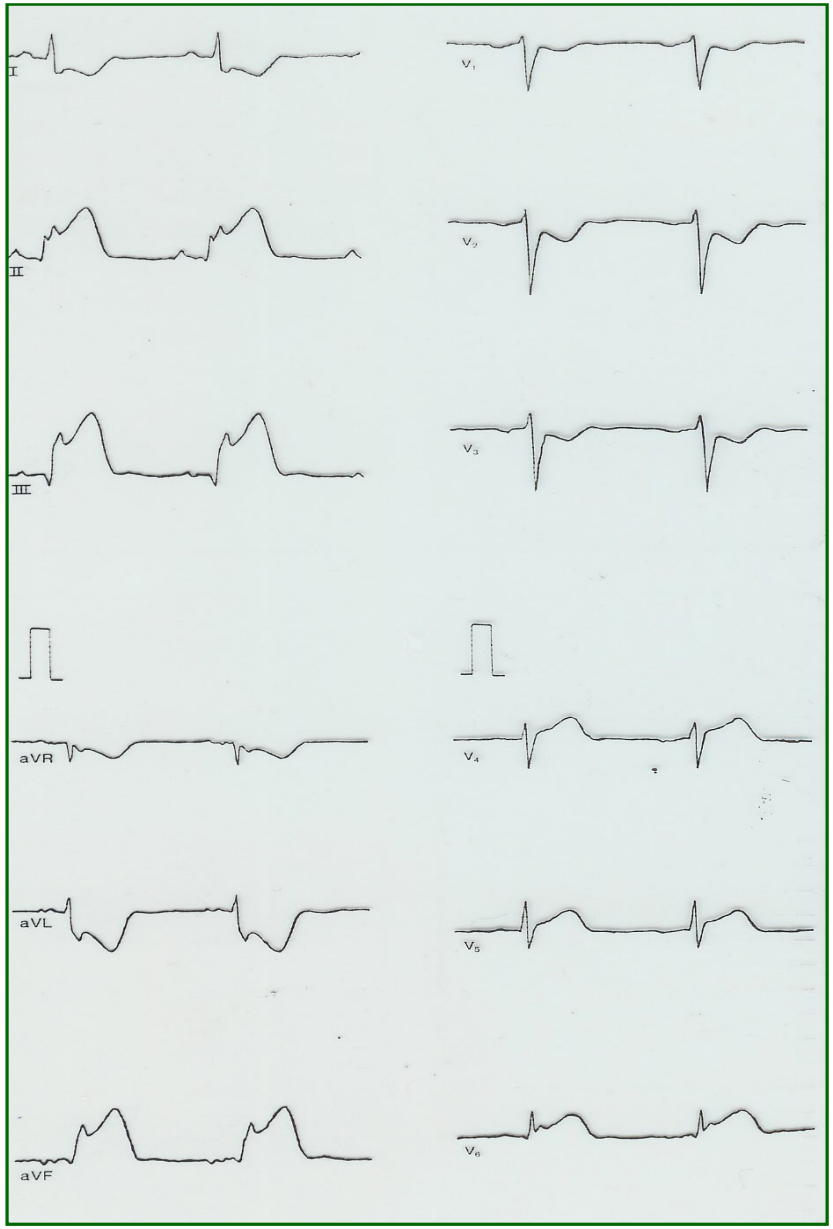

80% Coronaria Destra

20% Circonflessa Sx

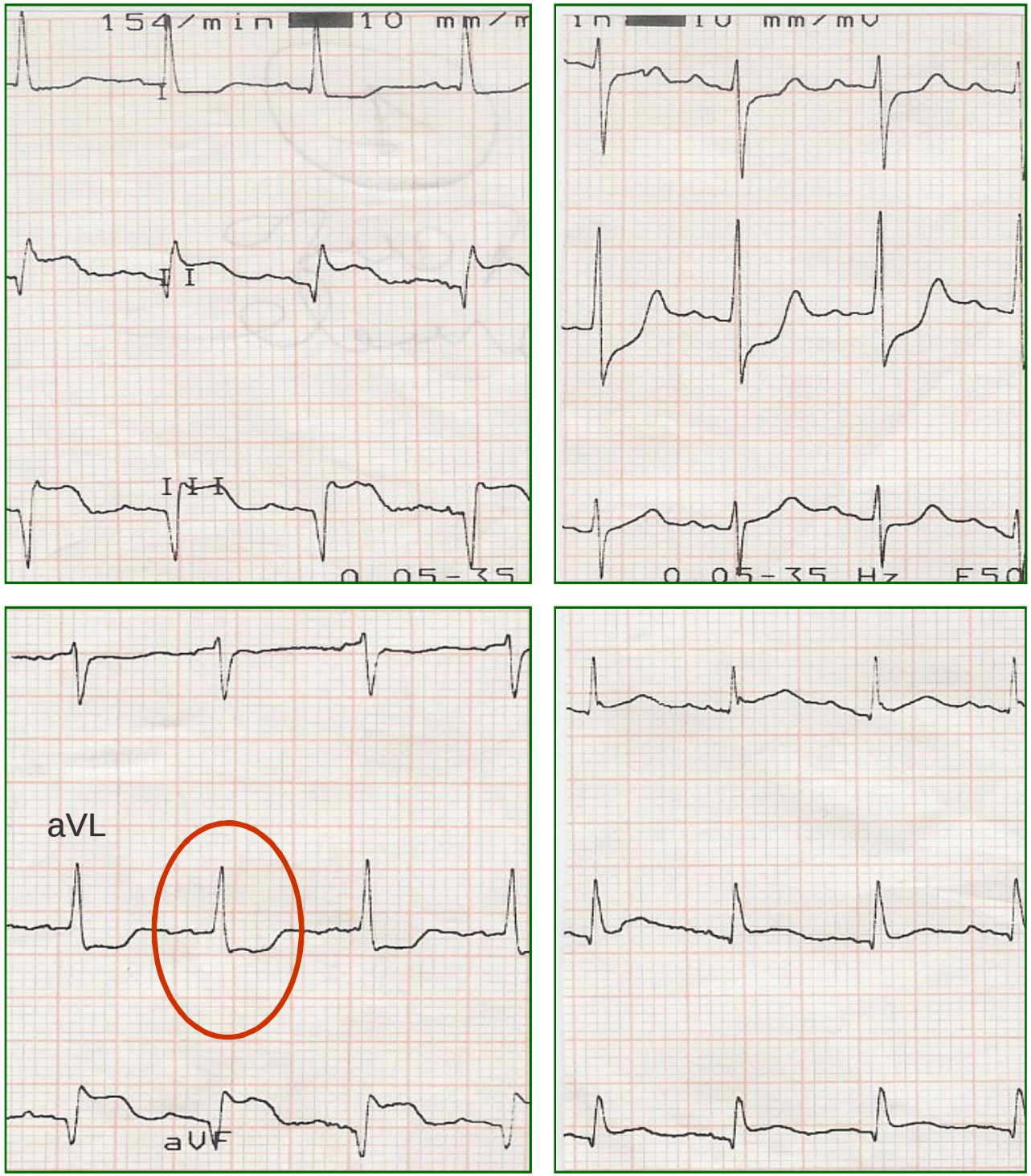

Coronaria Destra

ST-sopra D3 > D2

ST-sotto D1 - aVL

ST = aVR

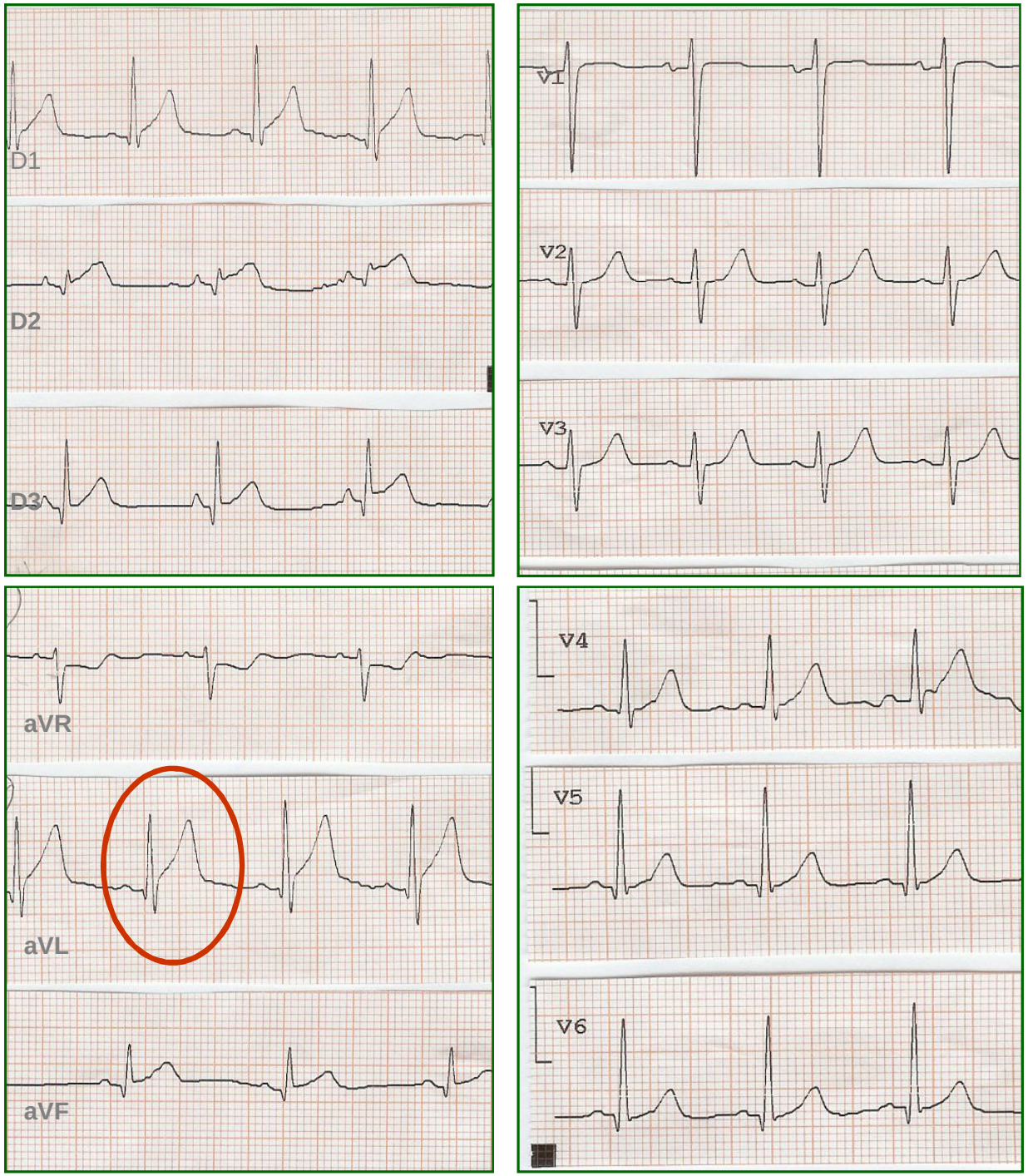

Circonflessa Sx

ST-sopra D2 > D3

ST-sopra D1 - aVL

ST-sotto aVR

...perla preziosa!

Mario F. a 73

in P.S. per angor tipico

assenza di stasi polmonare

TROPONINA T	2,530	*
CK-MB massa	82,8	*
MIOGLOBINA	242,6	*

sembra facile

…senza insidie

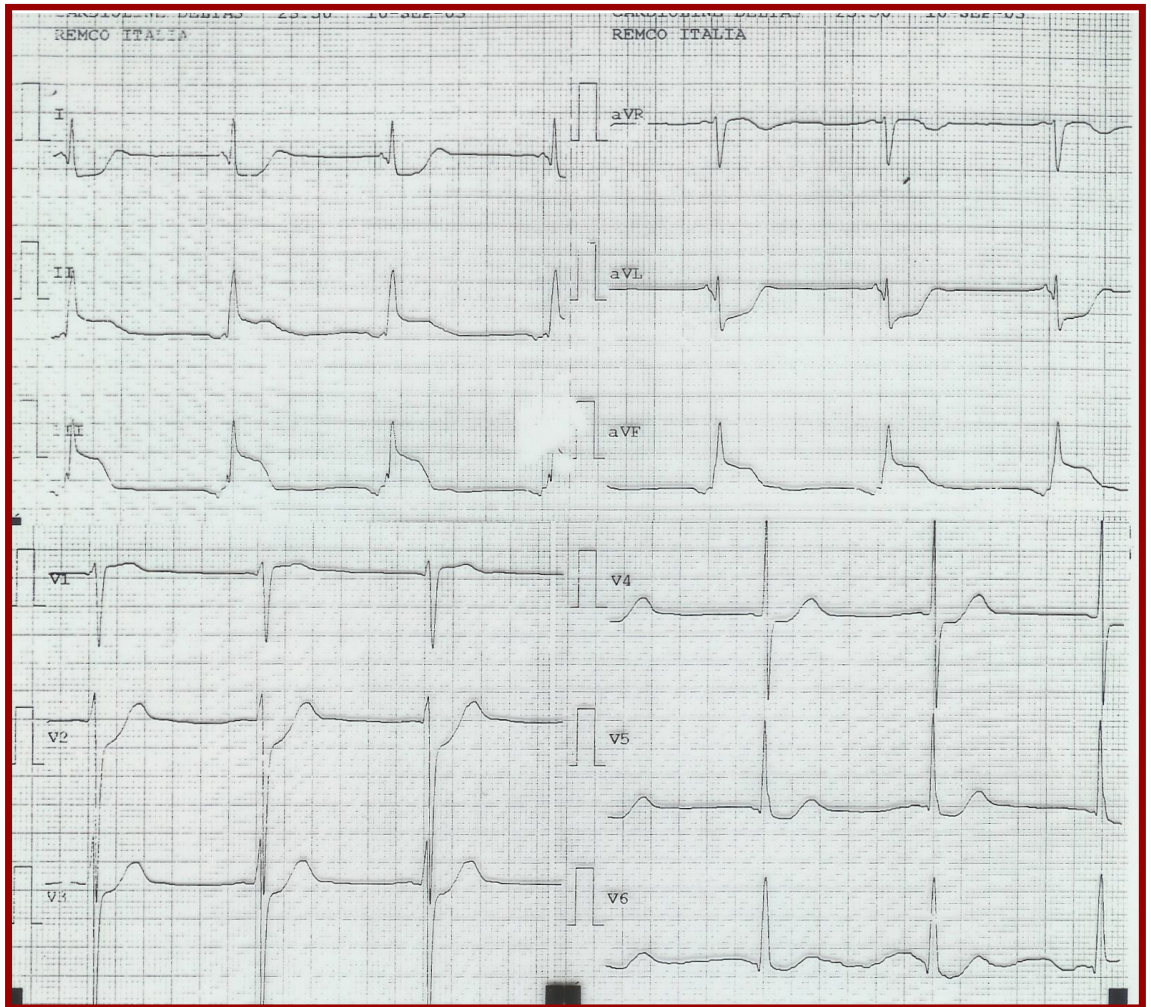

ST-EMI parete inferiore

classe emodinamica di esordio

Killip 1……ma

Mario F. a 73

in P.S. per angor tipico

assenza di stasi polmonare

TROPONINA T	2,530	*
CK-MB massa	82,8	*
MIOGLOBINA	242,6	*

sembra facile

…senza insidie

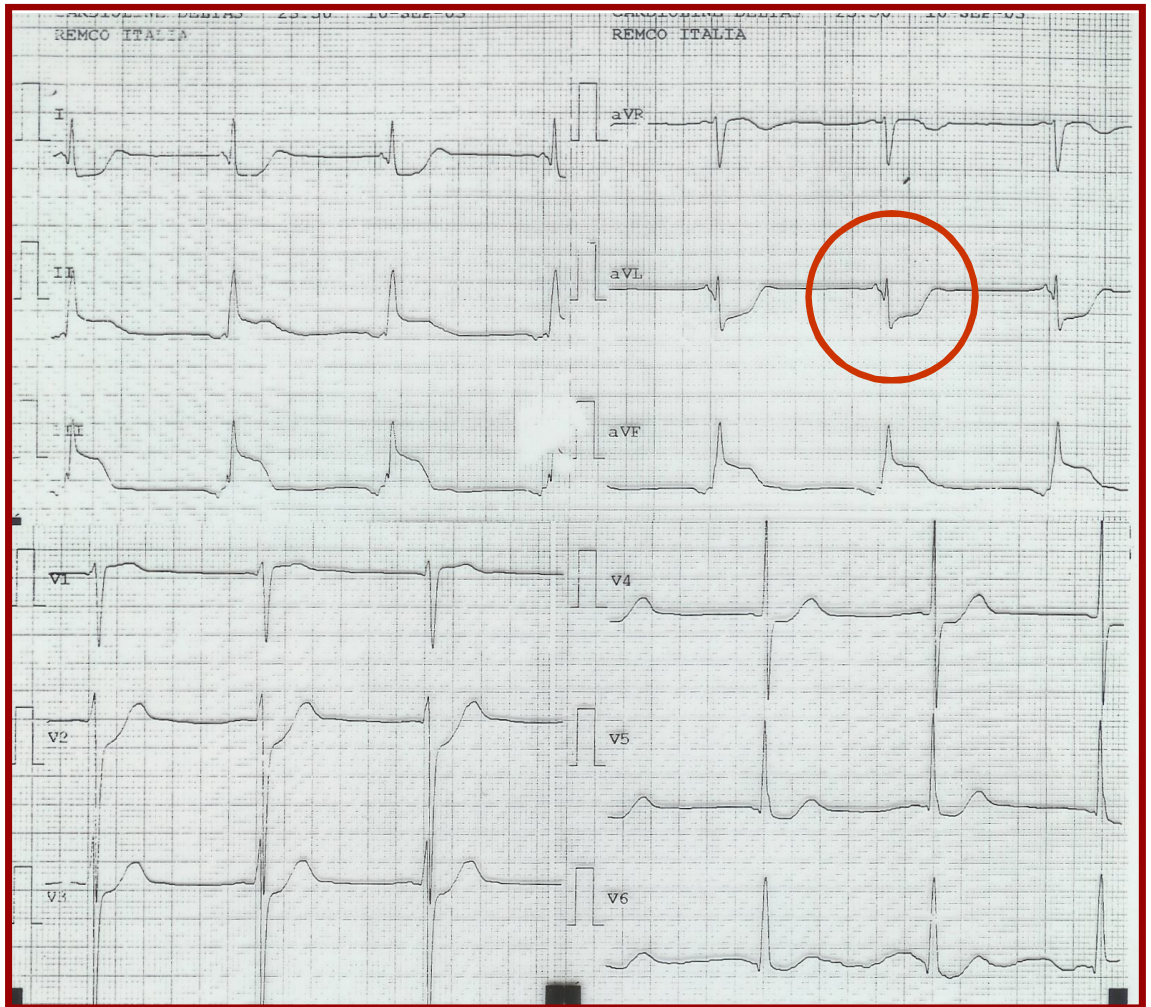

ST-EMI parete inferiore

classe emodinamica di esordio

Killip 1……ma

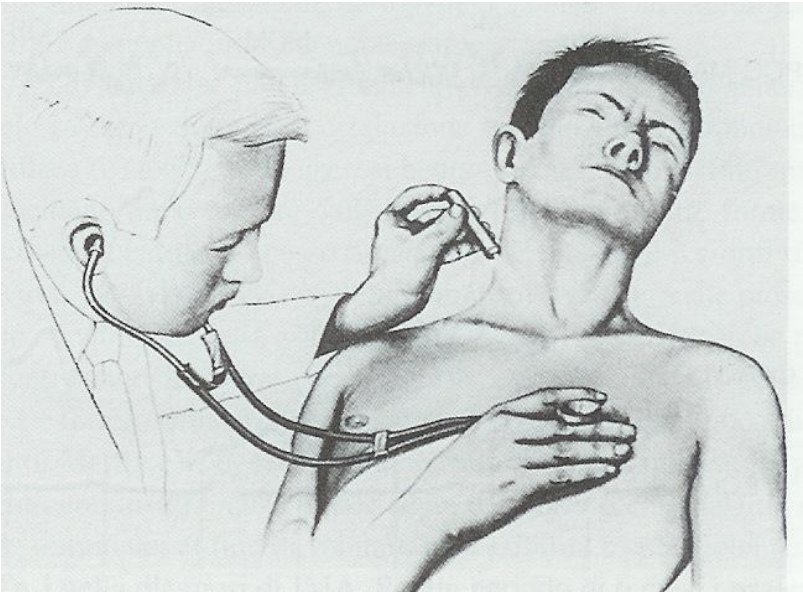

… severo stato ipotensivo

turgore delle giugulari

… ipotizziamo occlusione Cdx e compromissione ventricolo destro

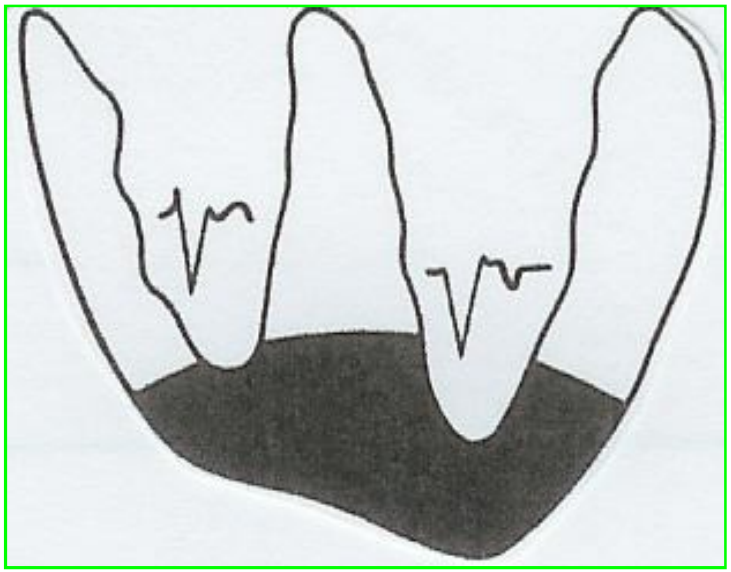

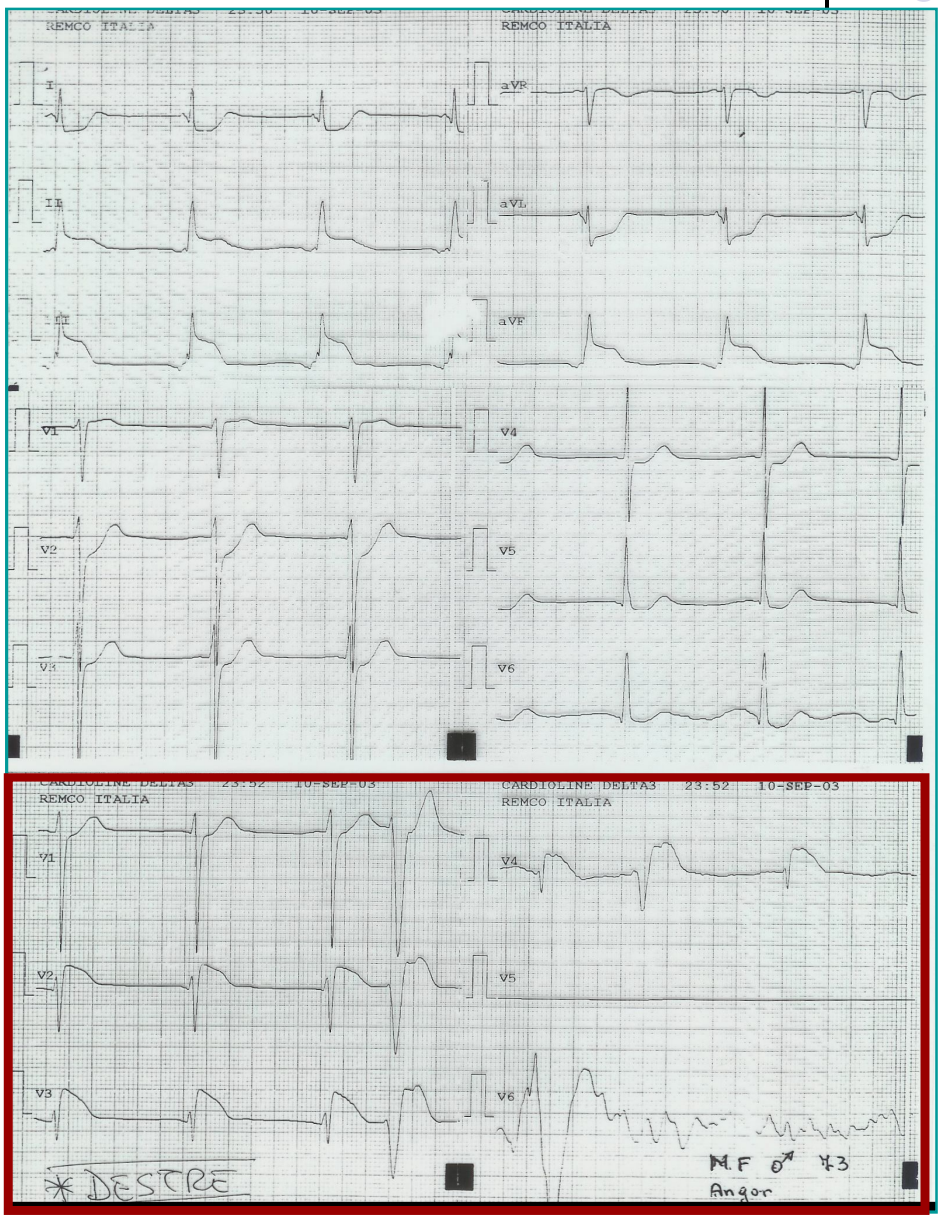

…studio derivazioni destre

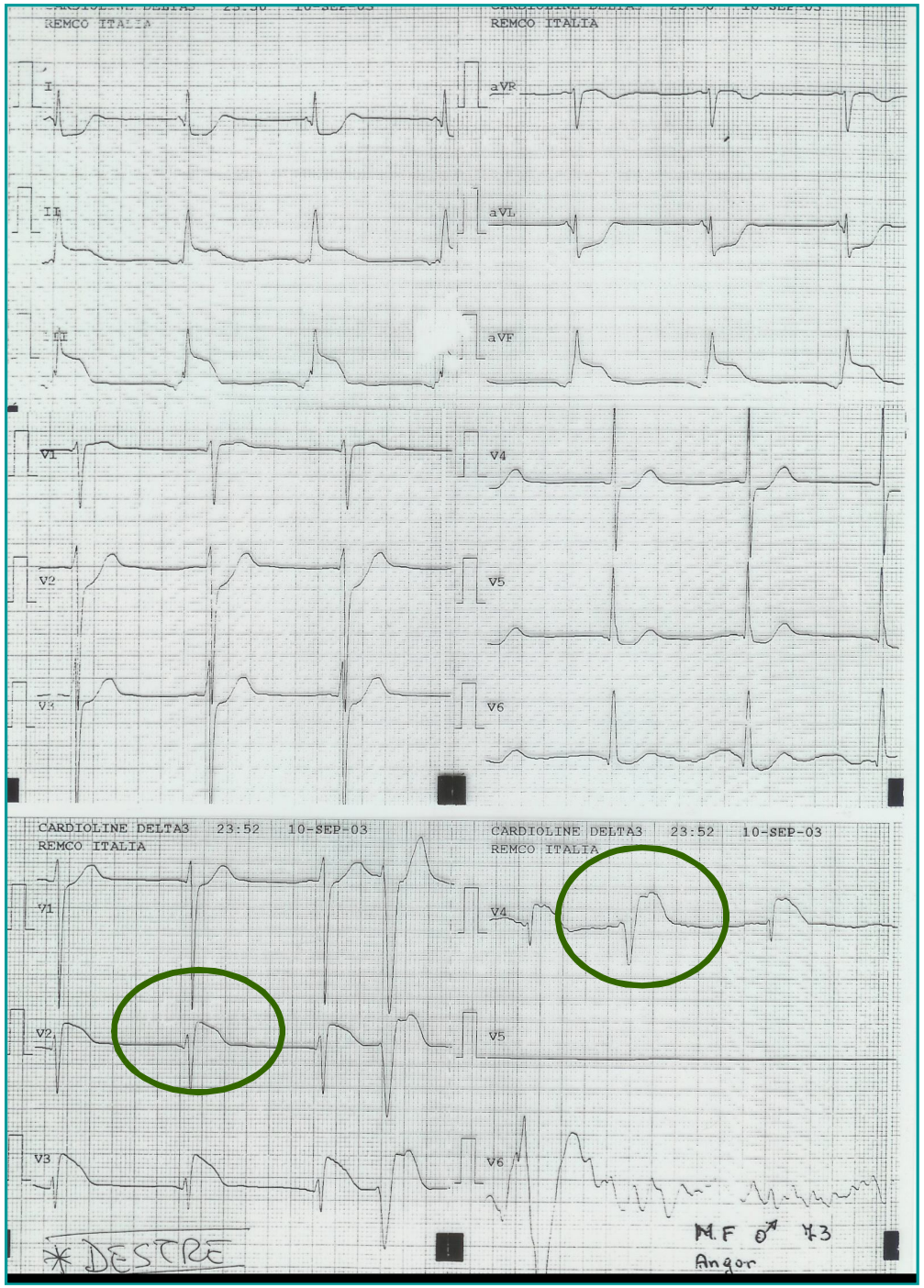

compromissione ventricolo destro

V2R - V4R

ST-sopra => 0.1mV

e/o QS - Qr

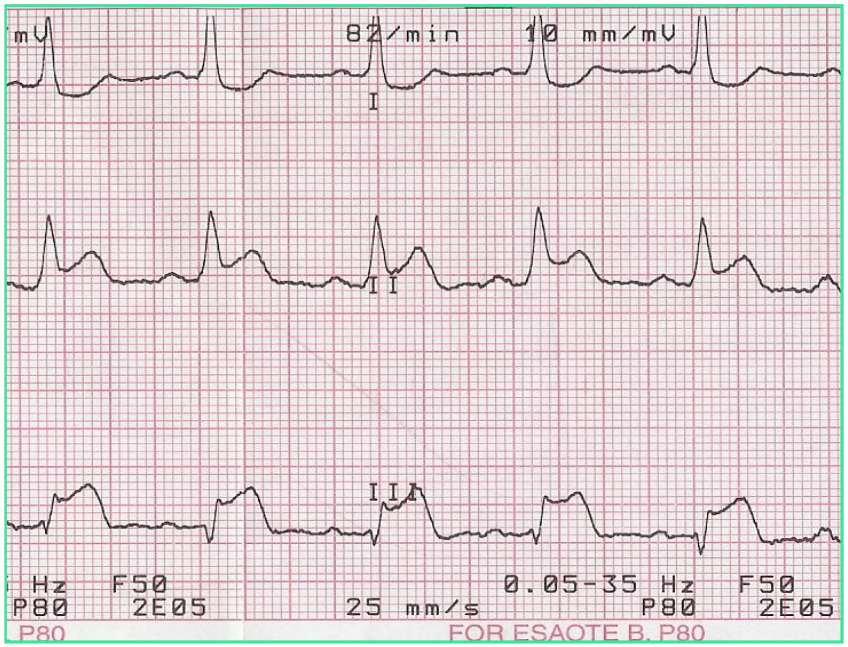

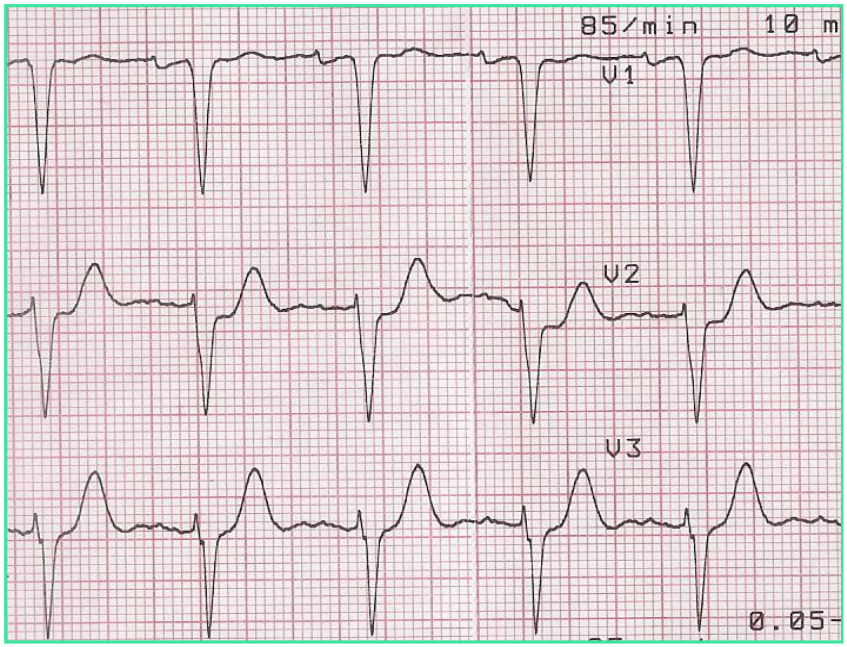

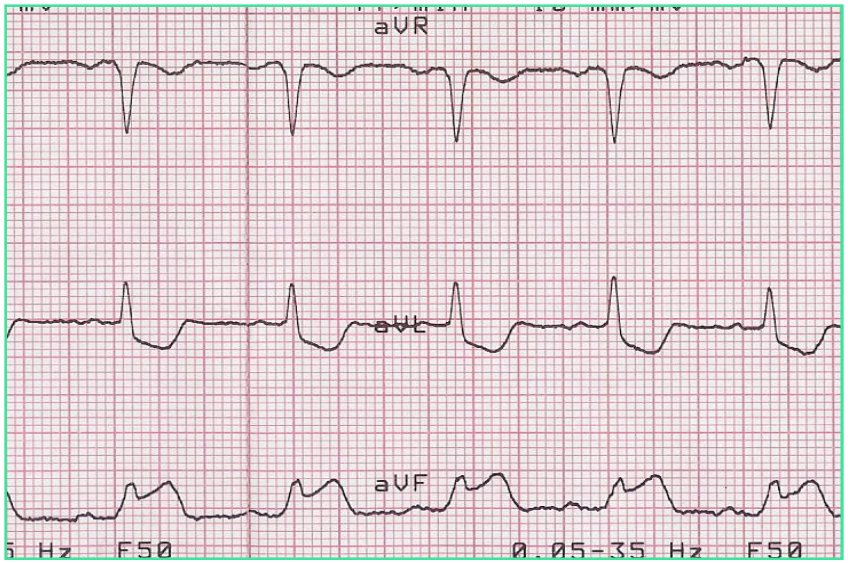

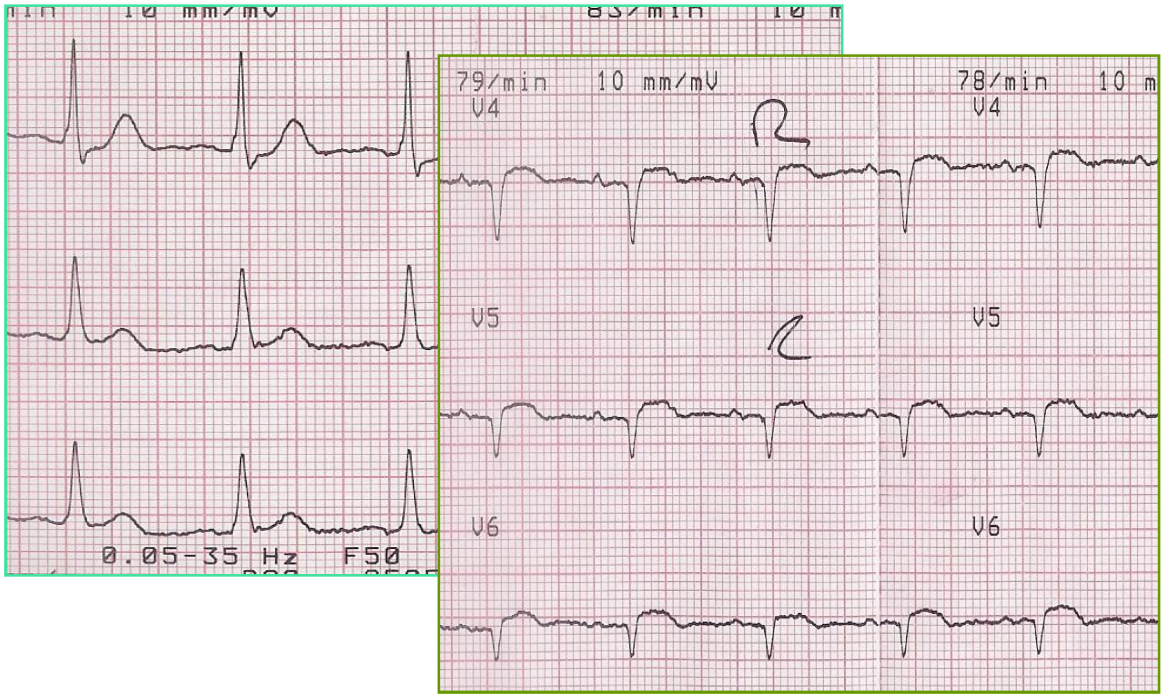

Gerardo *a 47 dolore toracico*
e stato ipotensivo

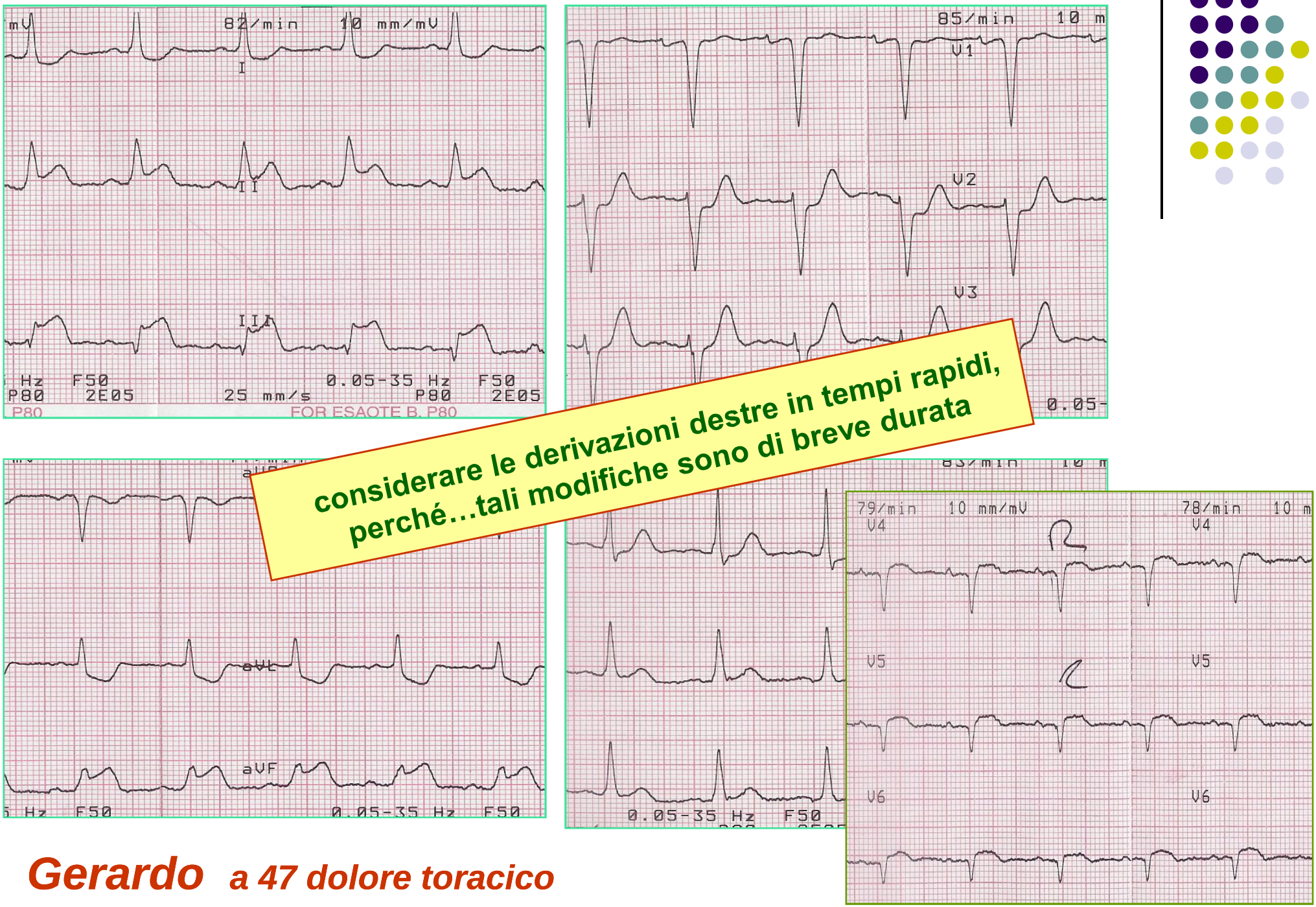

considerare le derivazioni destre in tempi rapidi, perché…tali modifiche sono di breve durata

Gerardo ***a 47 dolore toracico e stato ipotensivo***

ma, ancora attenzione…
altra perla preziosa

Enzo P. a 57 in P.S. per angor tipico

in caso di necrosi della parete inferiore …sempre sospettare l'estensione del danno tissutale

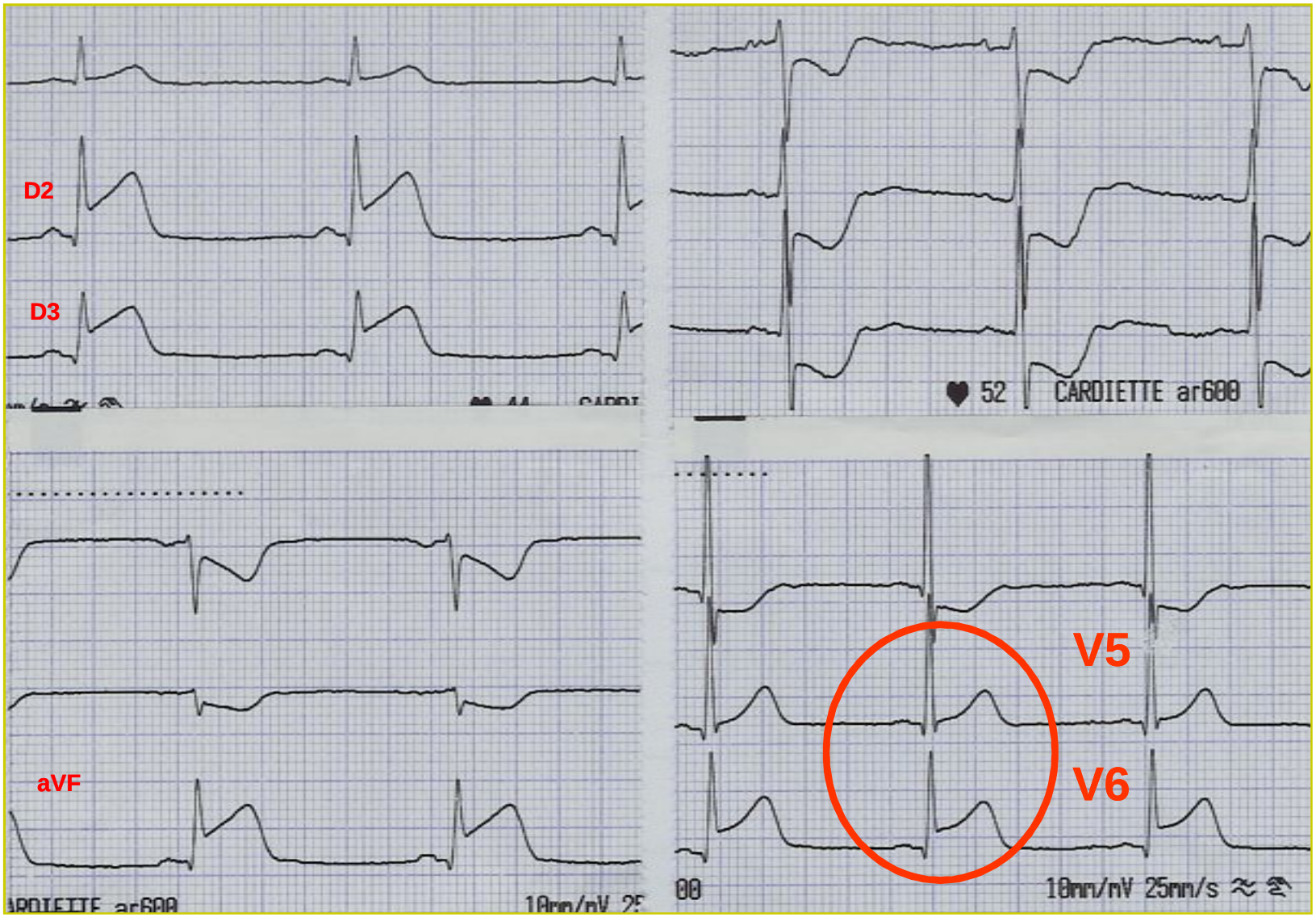

…saggio considerare la parete postero-laterale

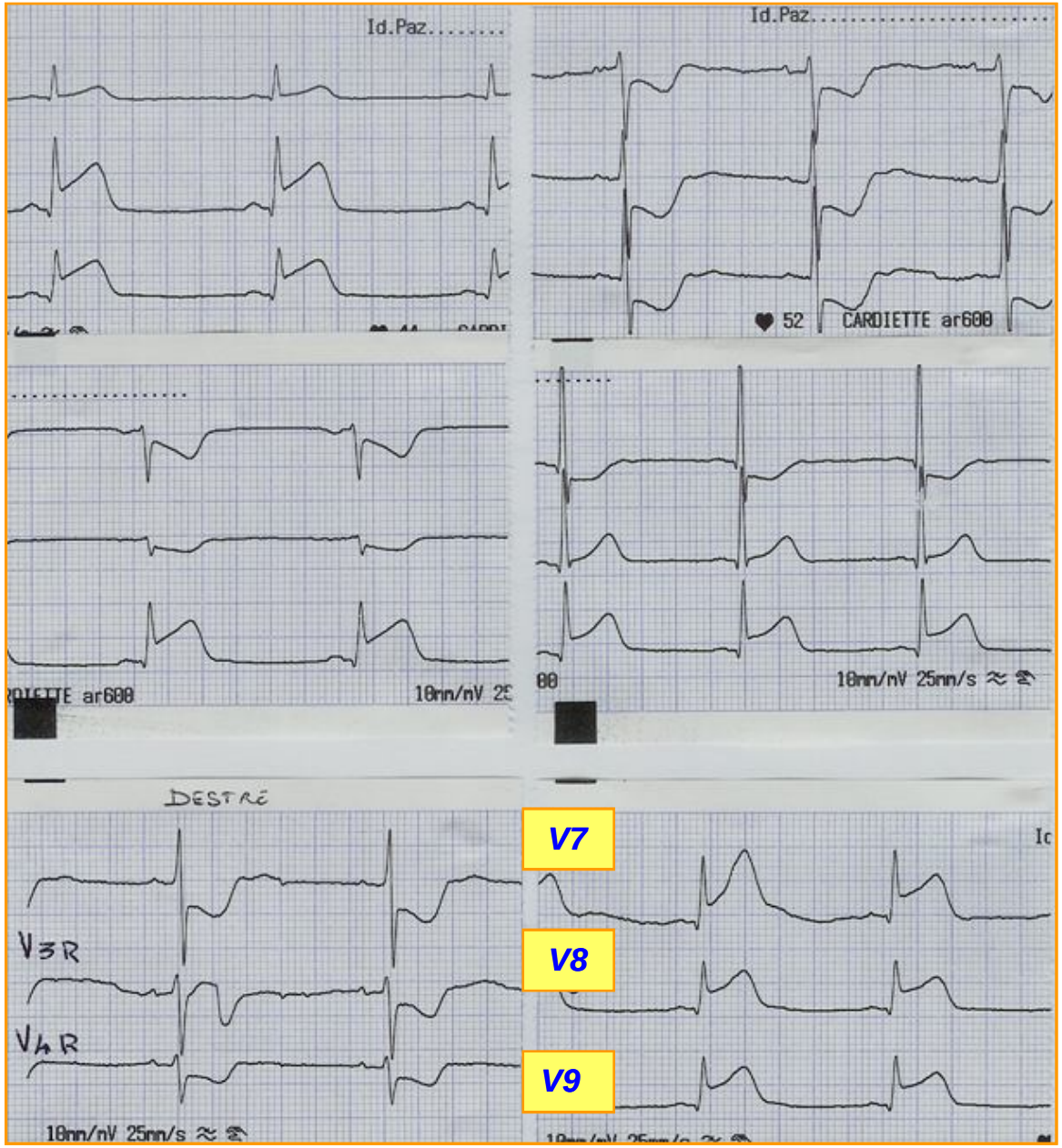

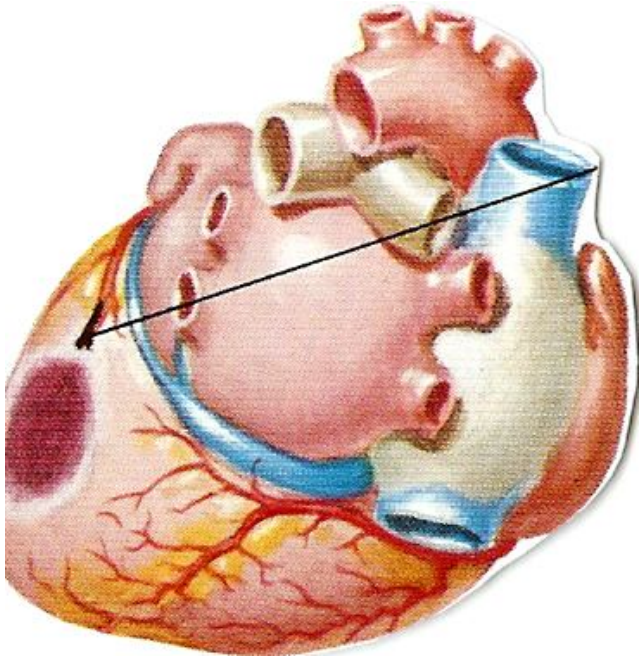

derivazioni V7 V8 V9

input conclusivo

derivazioni di studio

DICIOTTO

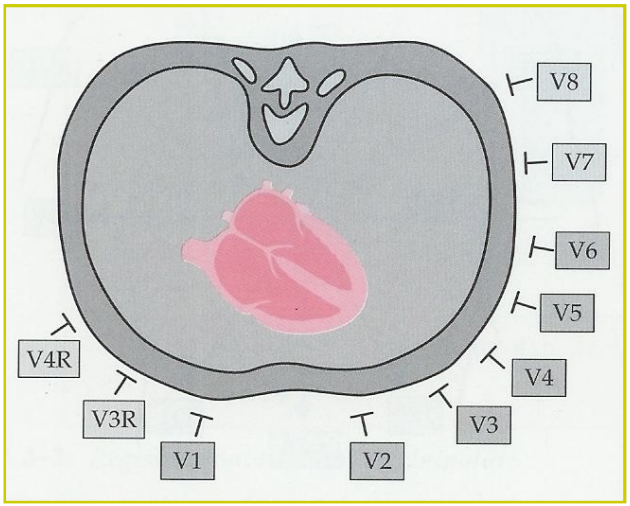

V 7-8-9

parete postero-laterale ventricolo sinistro

V 2-3-4 R

parete libera ventricolo destro

ALCUNI TARGET DI SEVERITA'

…utile, nella stratificazione del rischio, sarà ricordare

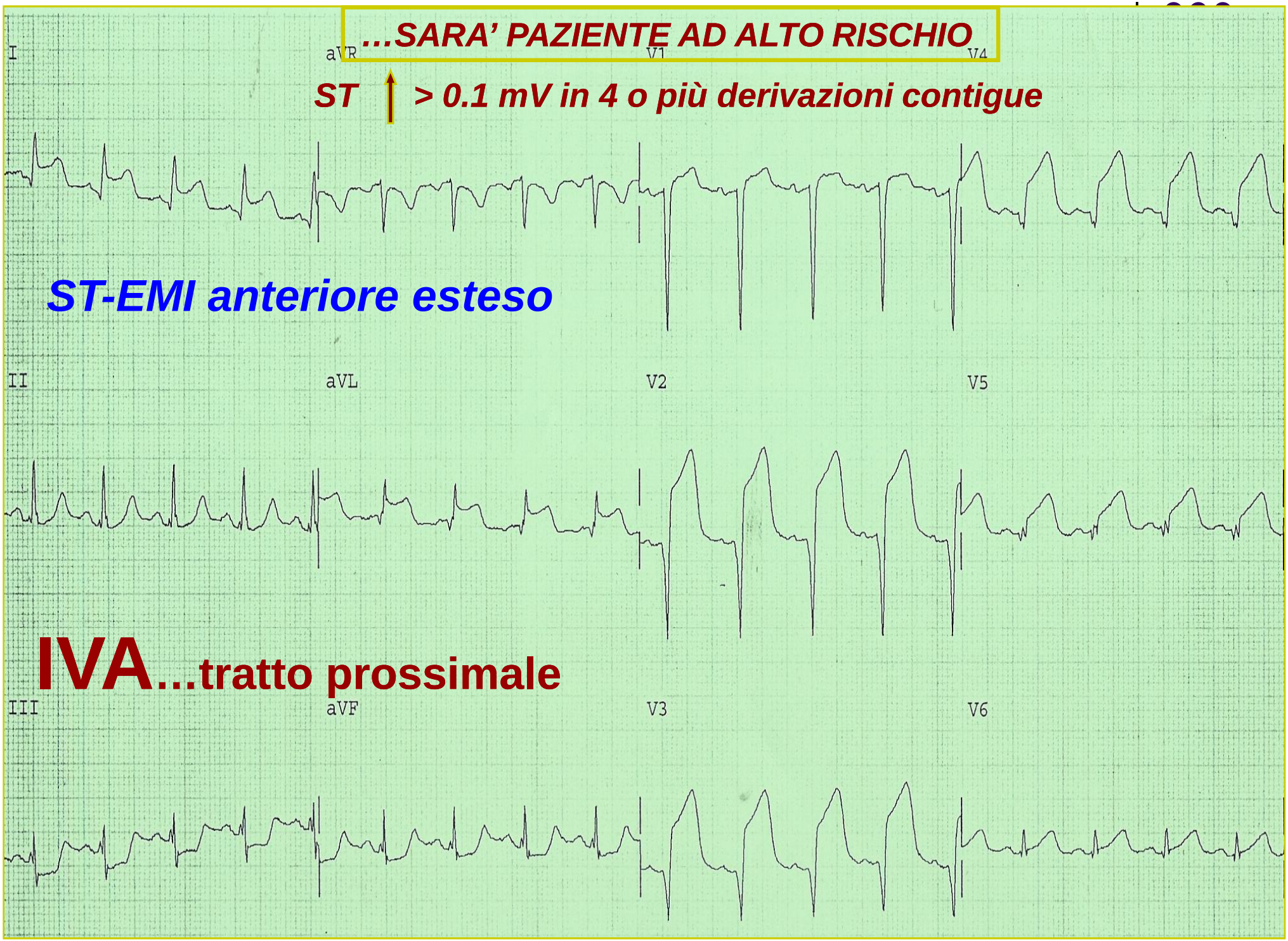
…SARA' PAZIENTE AD ALTO RISCHIO
ST ↑ > 0.1 mV in 4 o più derivazioni contigue
ST-EMI anteriore esteso
IVA…tratto prossimale
I
aVR
V1
V4
II
aVL
V2
V5
III
aVF
V3
V6

stenosi 90% IVA prossimale…

…dopo PTCA + stent

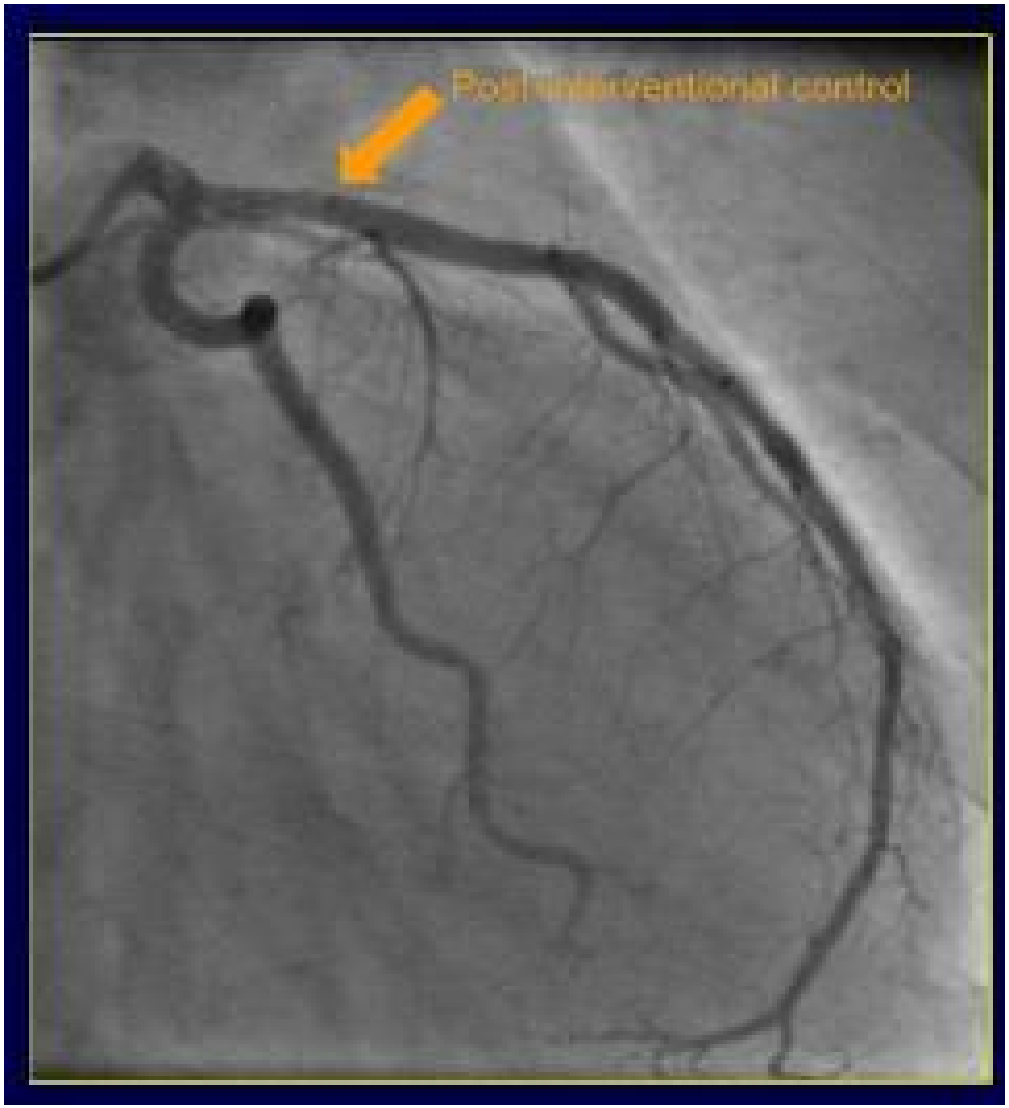

si ipotizza compromissione di una coronaria destra ***dominante***
…nel suo ***tratto prossimale***

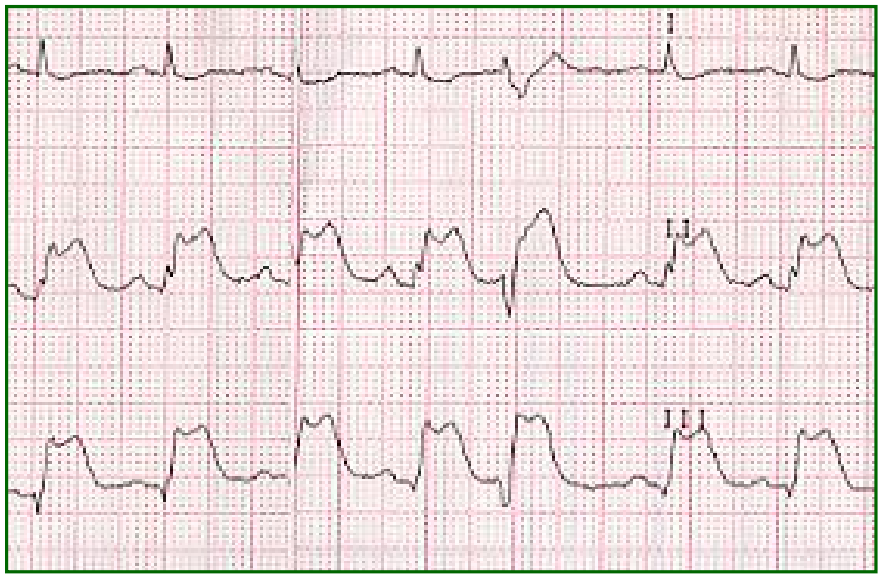

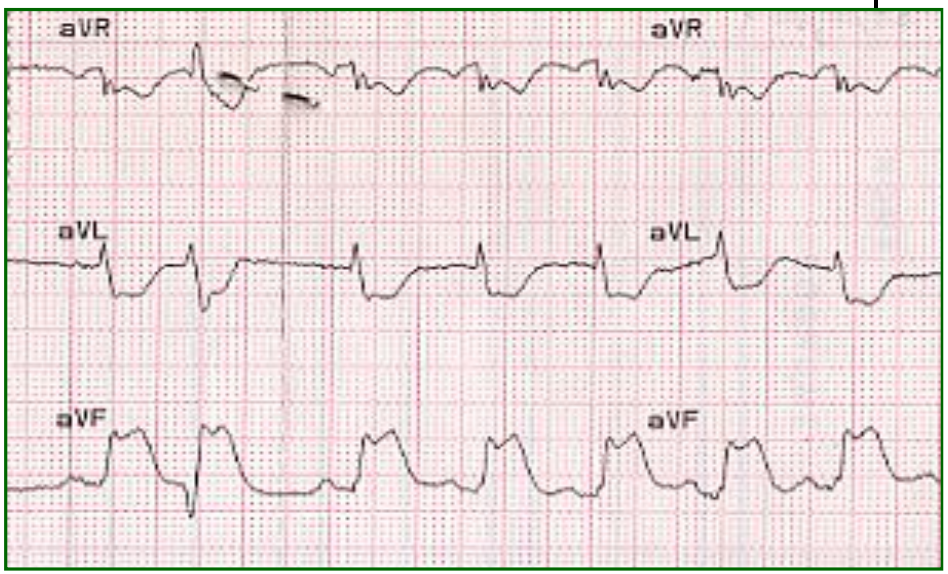

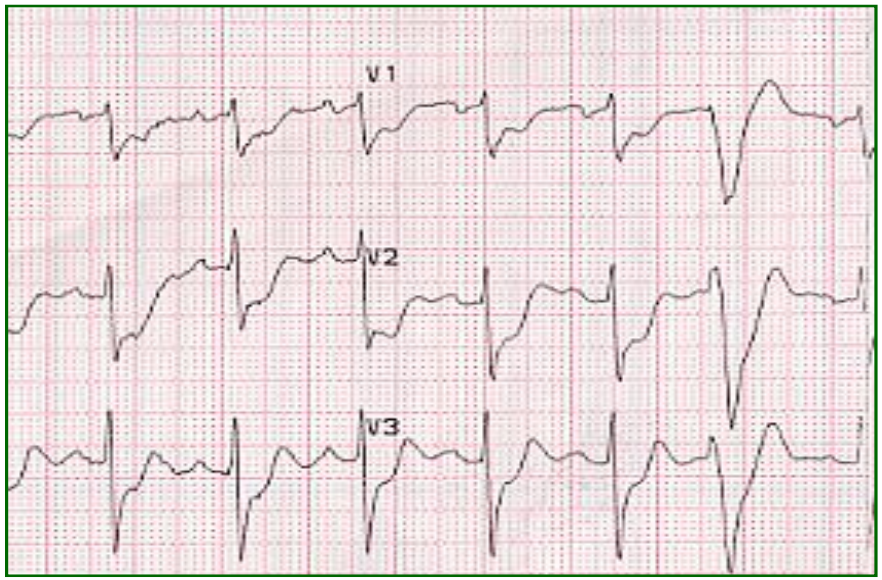

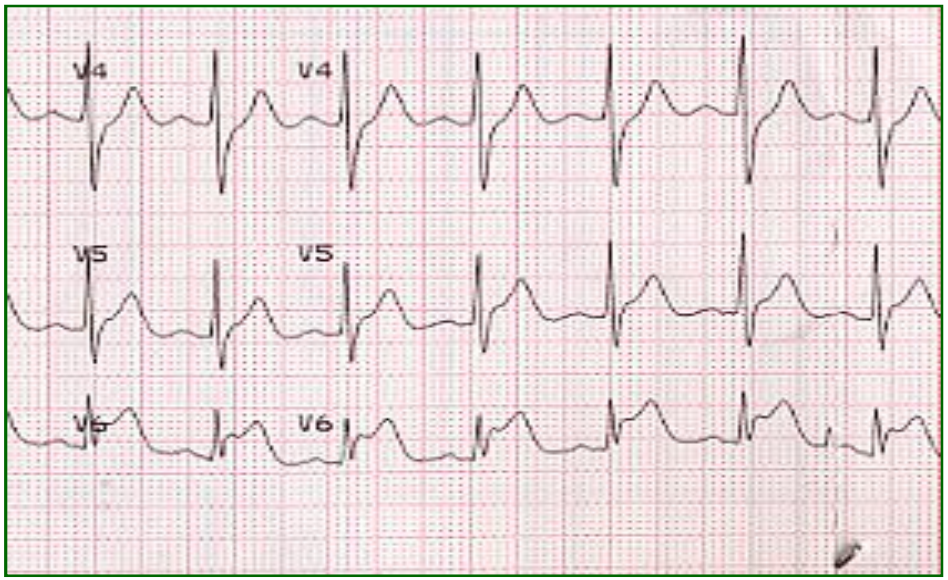

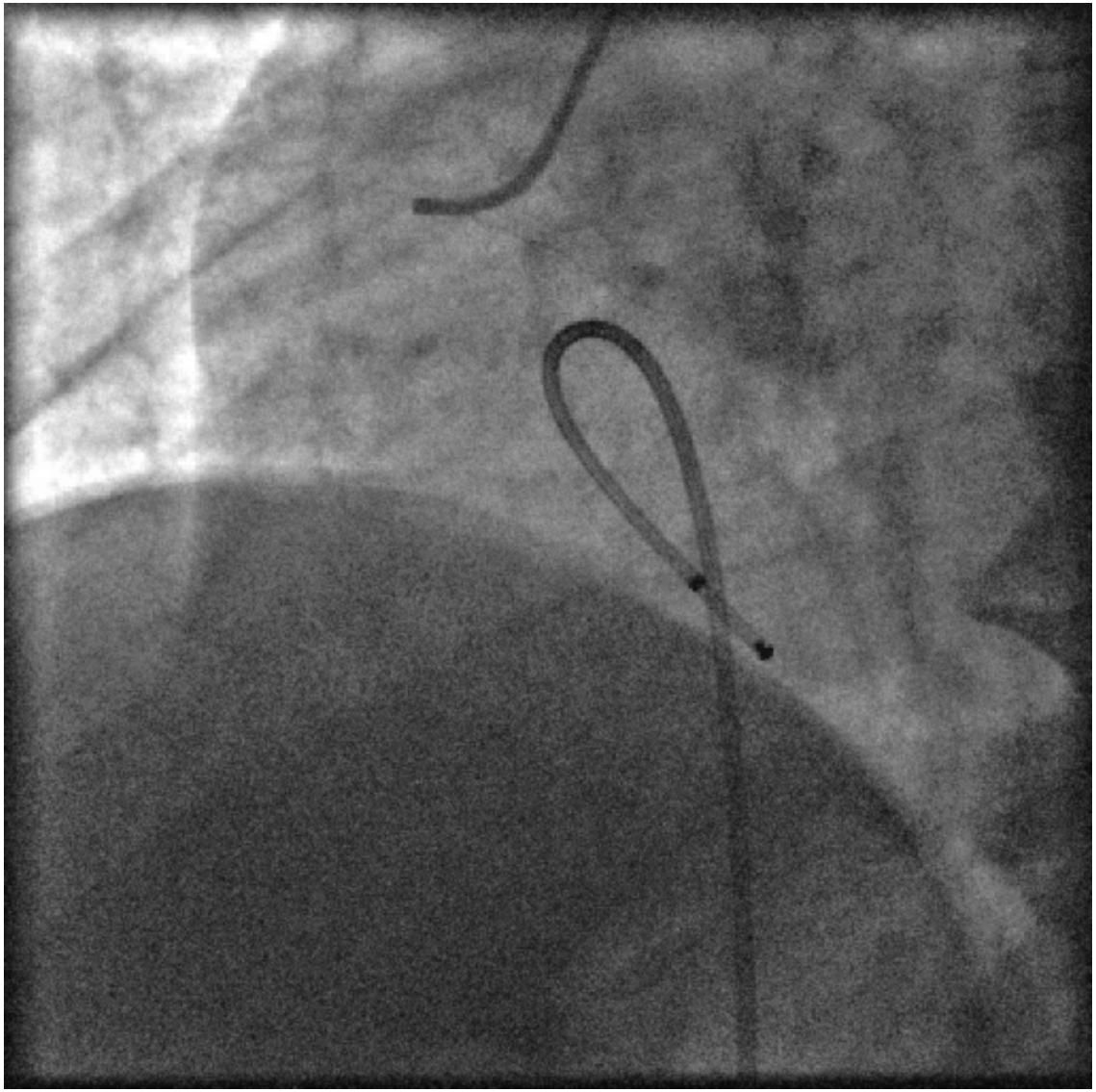

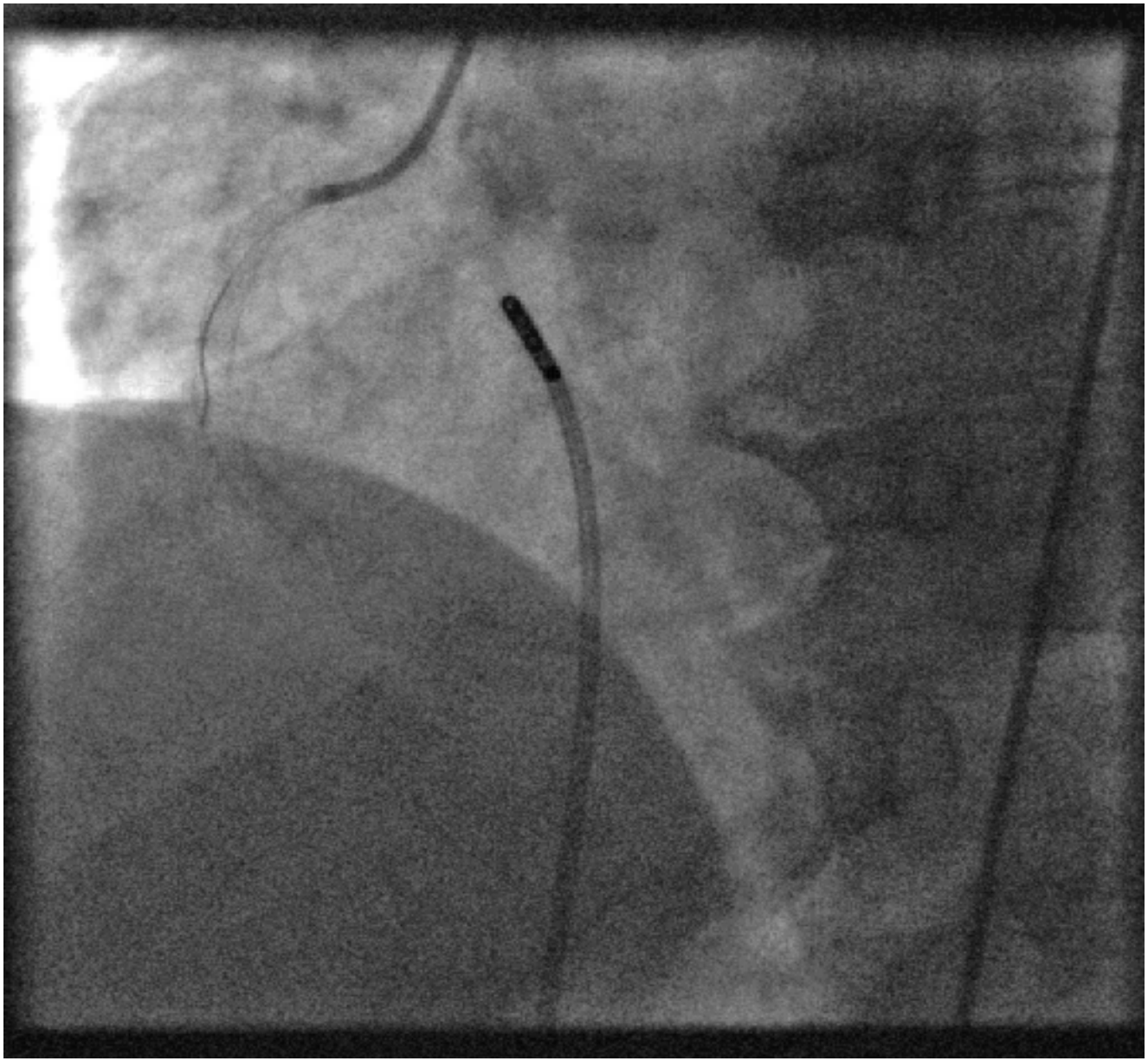

attenzione…tranello!

stenosi critica TRONCO COMUNE

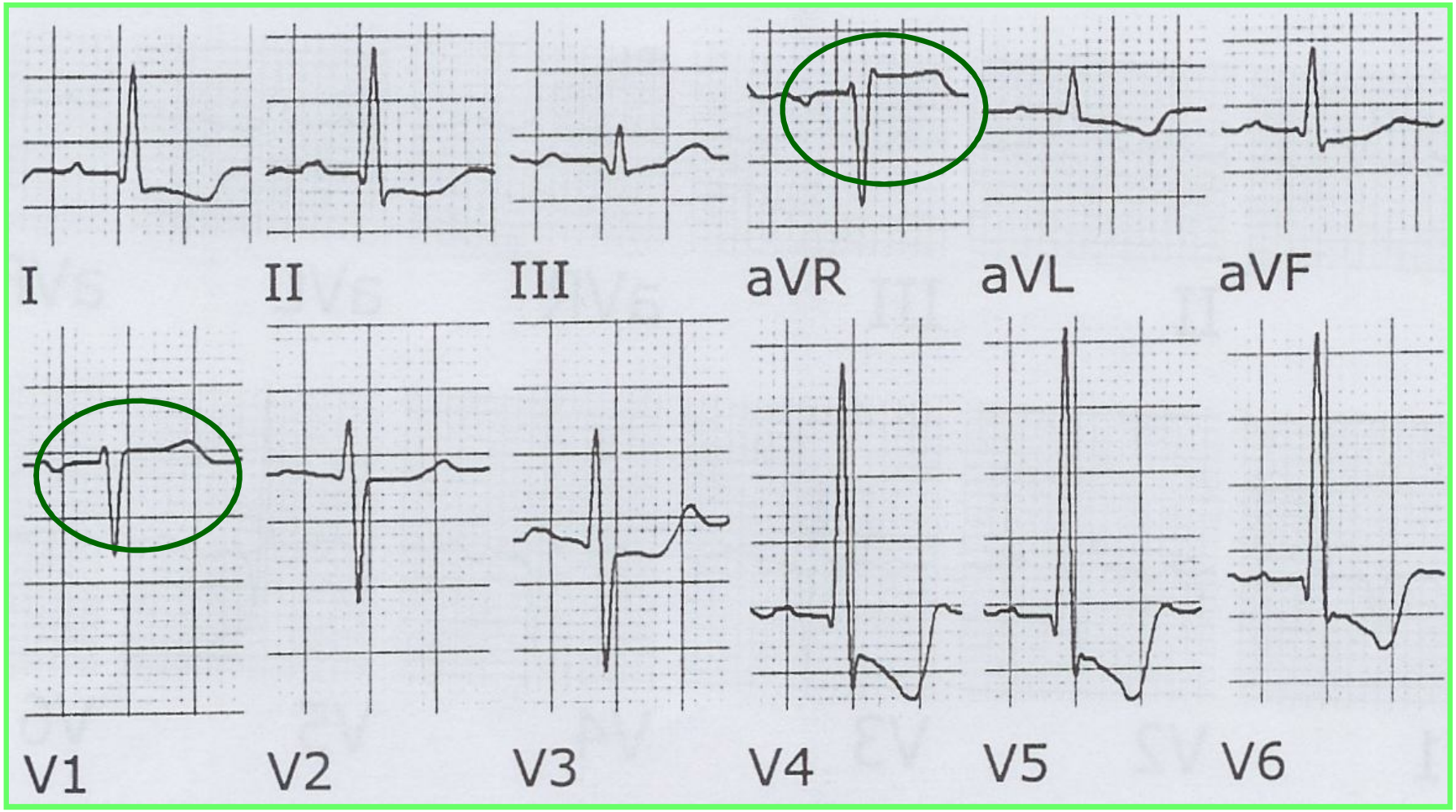

STsopra aVR – V1 (aVR > V1)

STsotto in almeno 8 derivazioni

somma STsotto > 12 mm

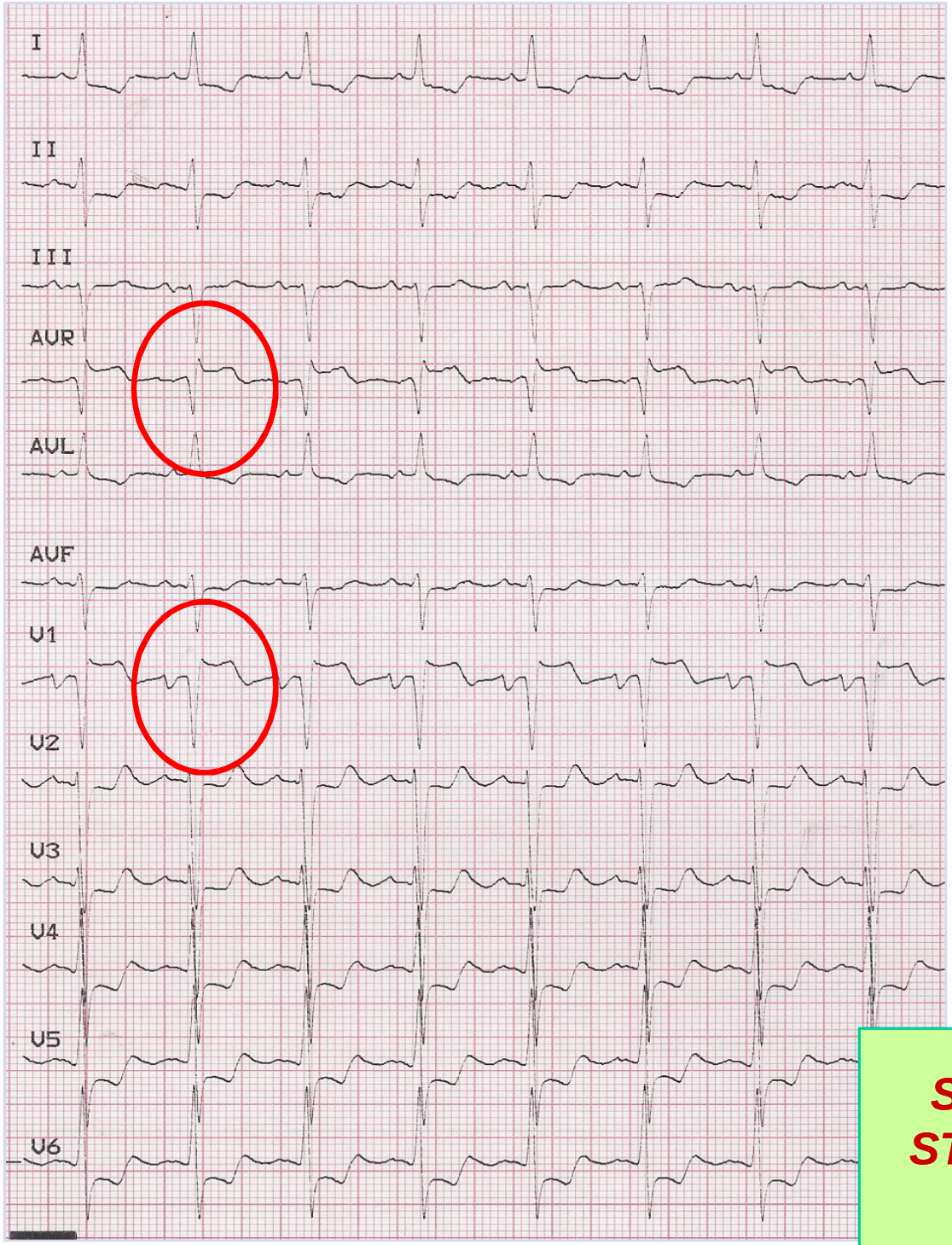

Salvatore M. a 68

dolore toracico e shock

STsopra aVR – V1 (aVR > V1)
STsotto in almeno 8 derivazioni
somma STsotto > 12 mm

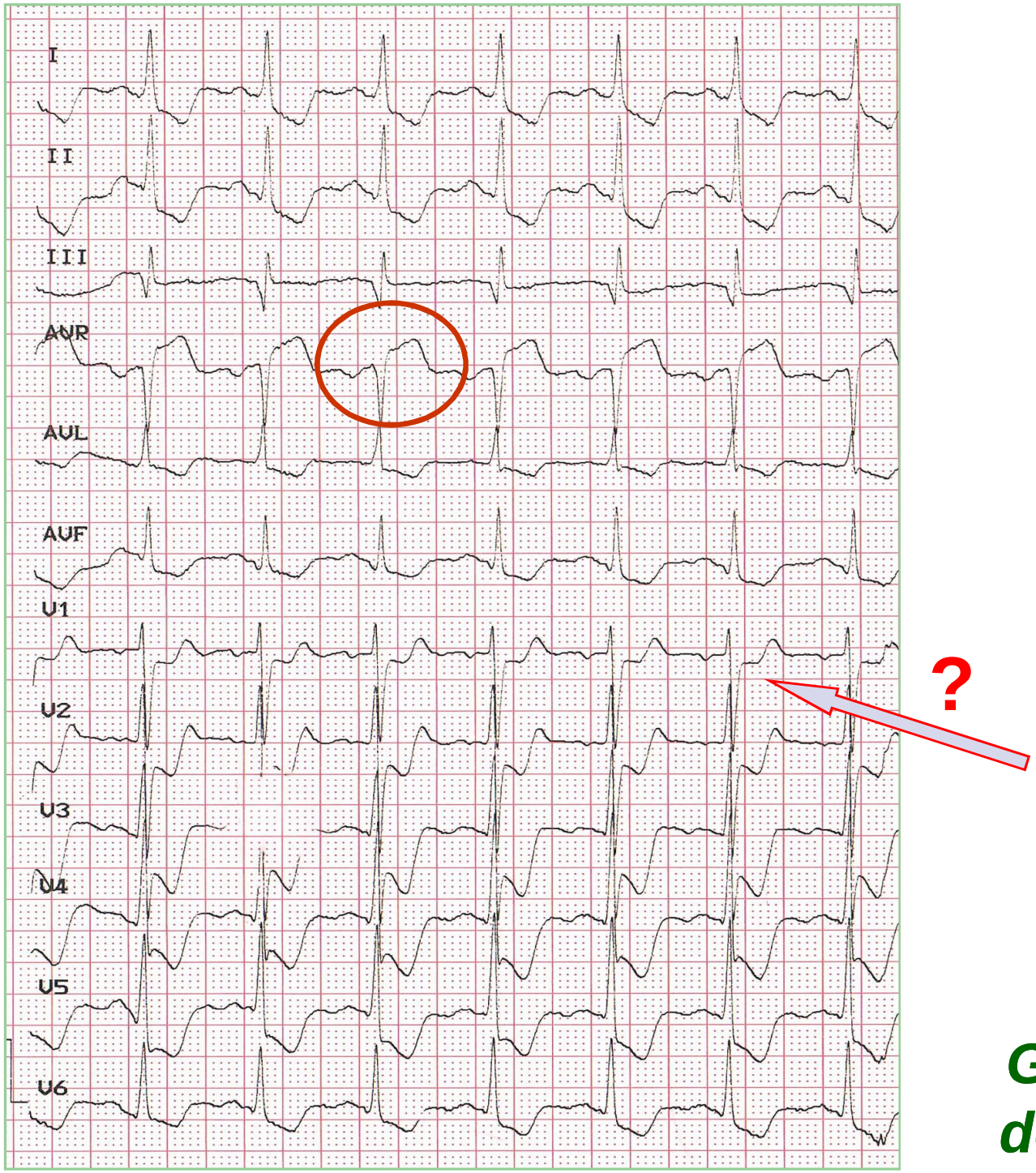

Giuditta a 59…
dolore toracico

N-ST EMI - angina instabile

tutti sanno che…

N-ST EMI Angina Instabile

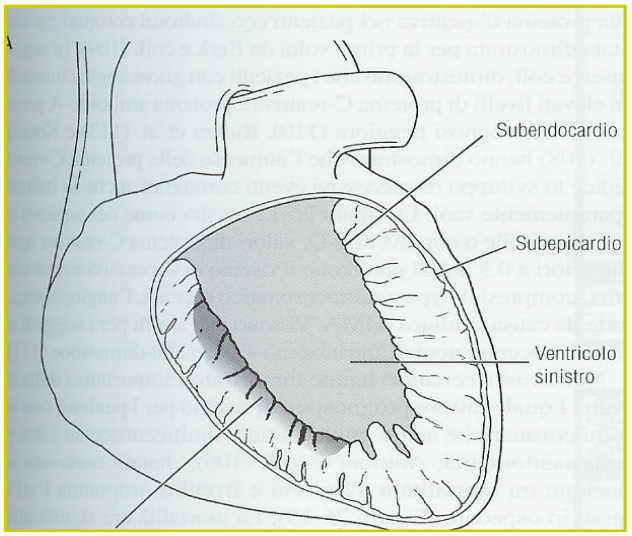

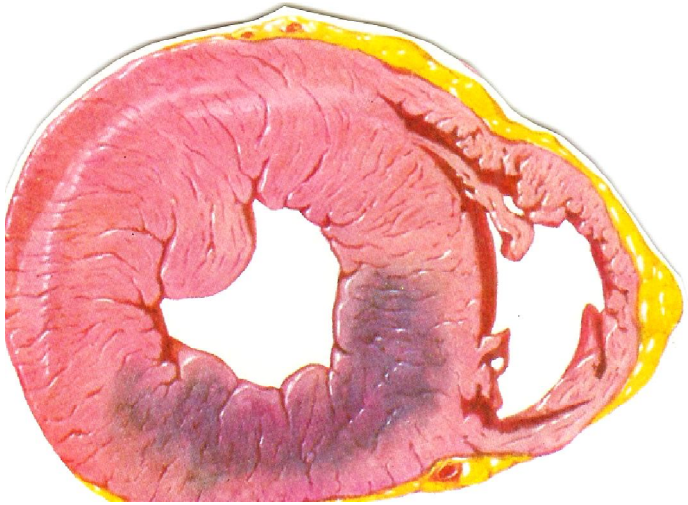

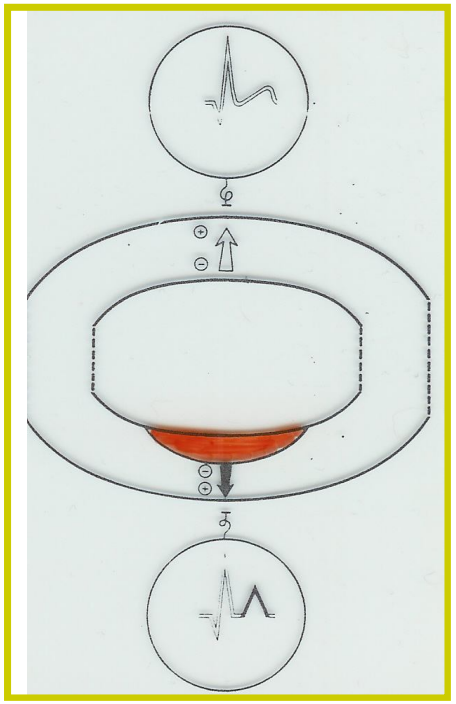

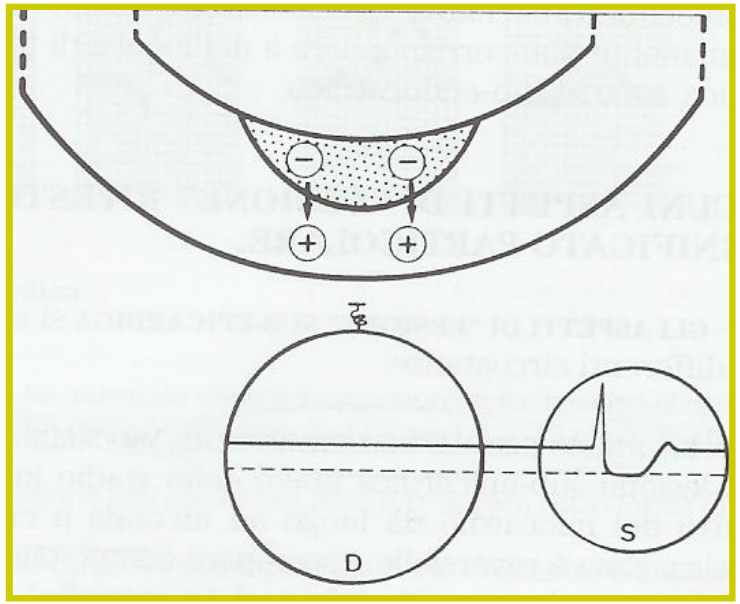

...segmento ST

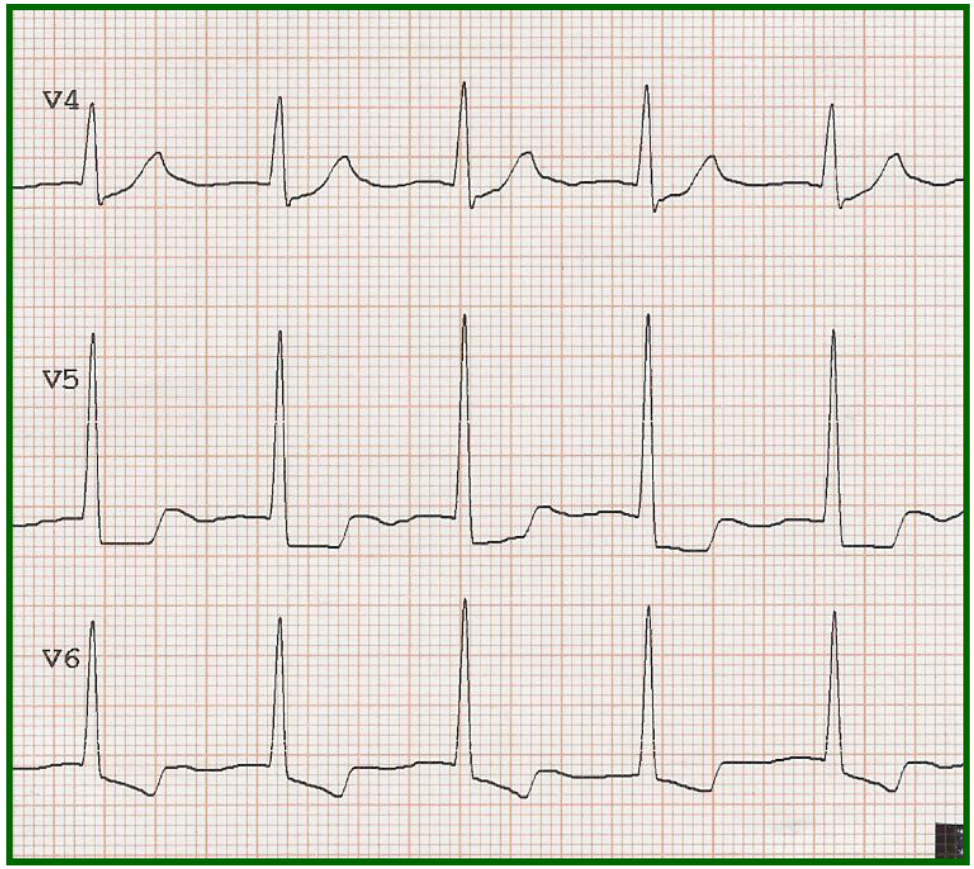

GOT/ASAT	24	
CPK	142	
TROPONINA T	1,130	*
CK-MB massa	15,0	*
MIOGLOBINA	156,3	*

onda T

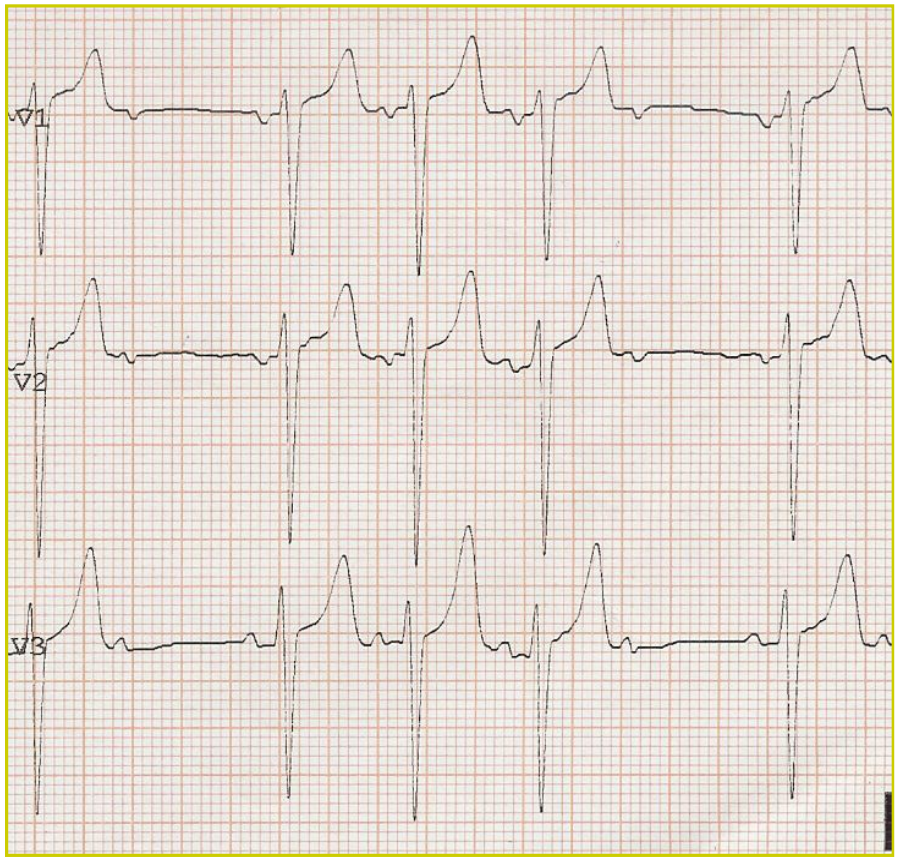

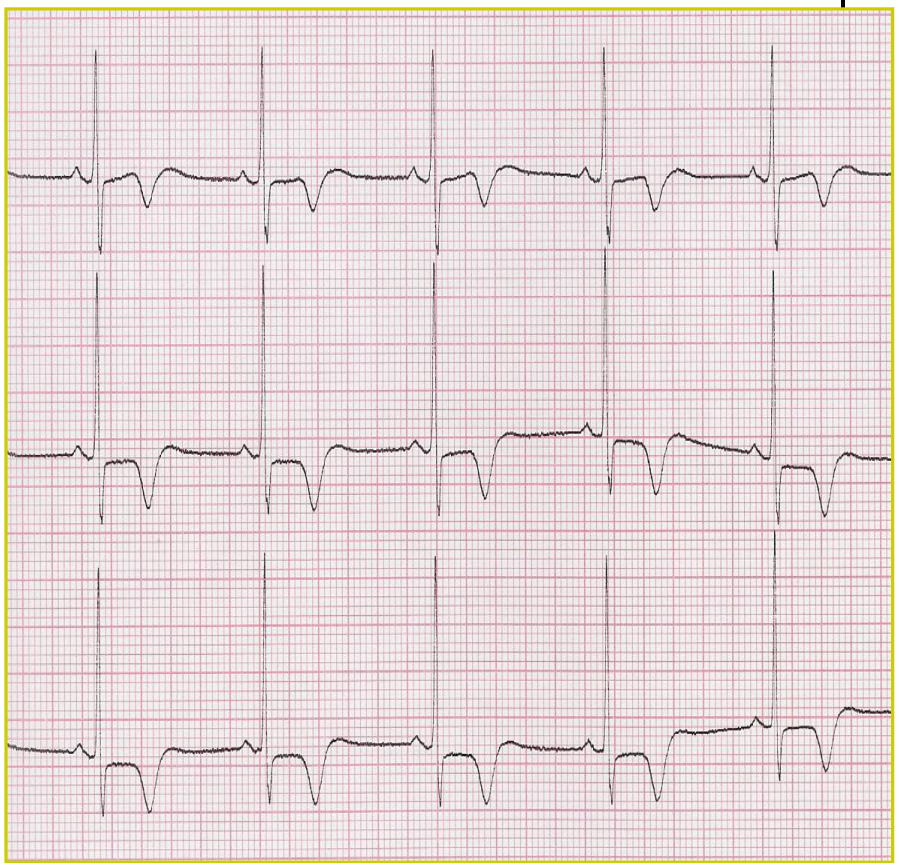

TROPONINA T	0,068	*
CK-MB massa	14,0	*
MIOGLOBINA	233,5	*

TROPONINA T	< 0.010
CK-MB massa	0,7
MIOGLOBINA	26,3

…riduzione di ampiezza onda R => 40%

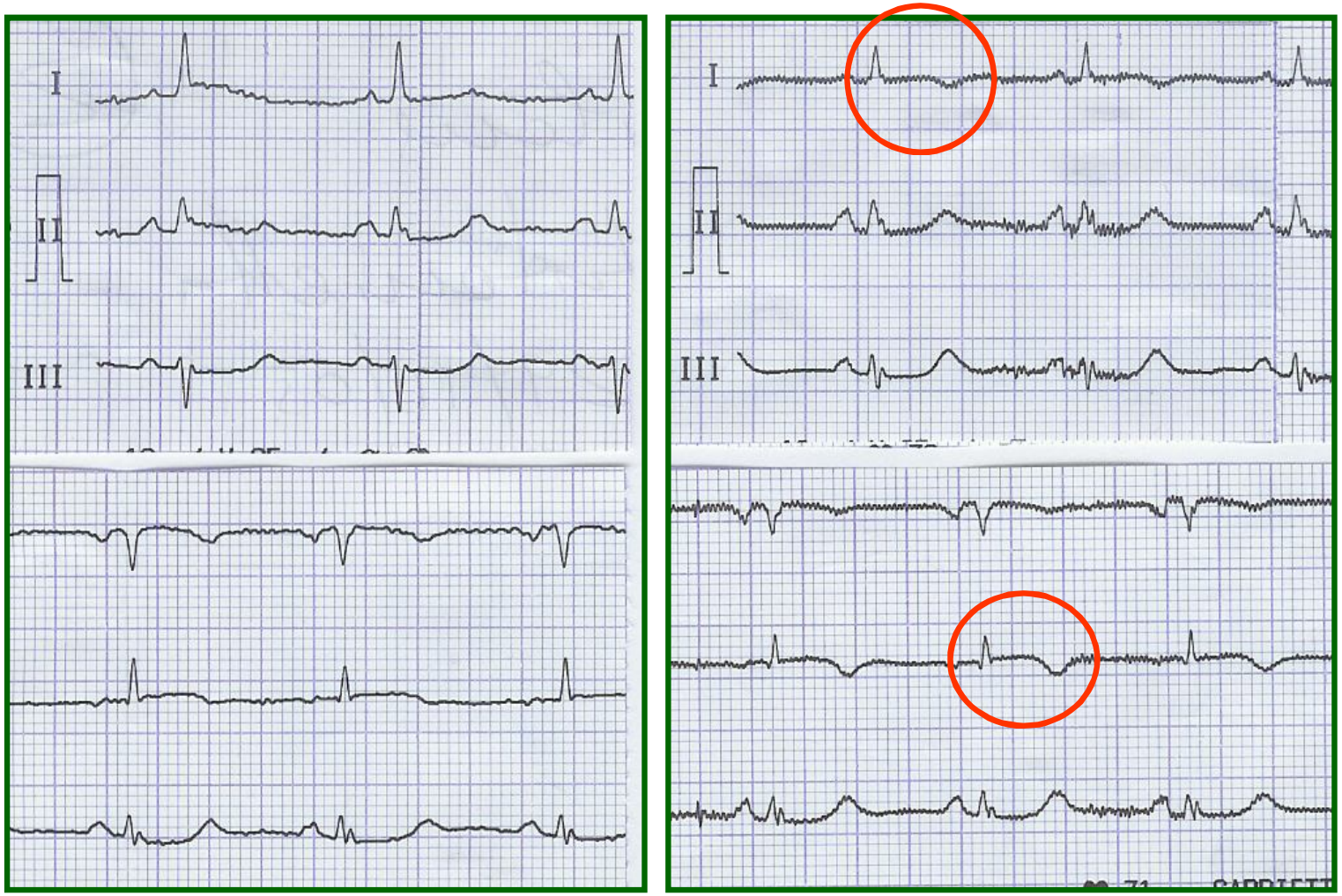

TROPONINA T	1,130	*
CK-MB massa	15,0	*
MIOGLOBINA	156,3	*



ma attenzione…
tranello

Alfredo P. anni 62 angor tipico

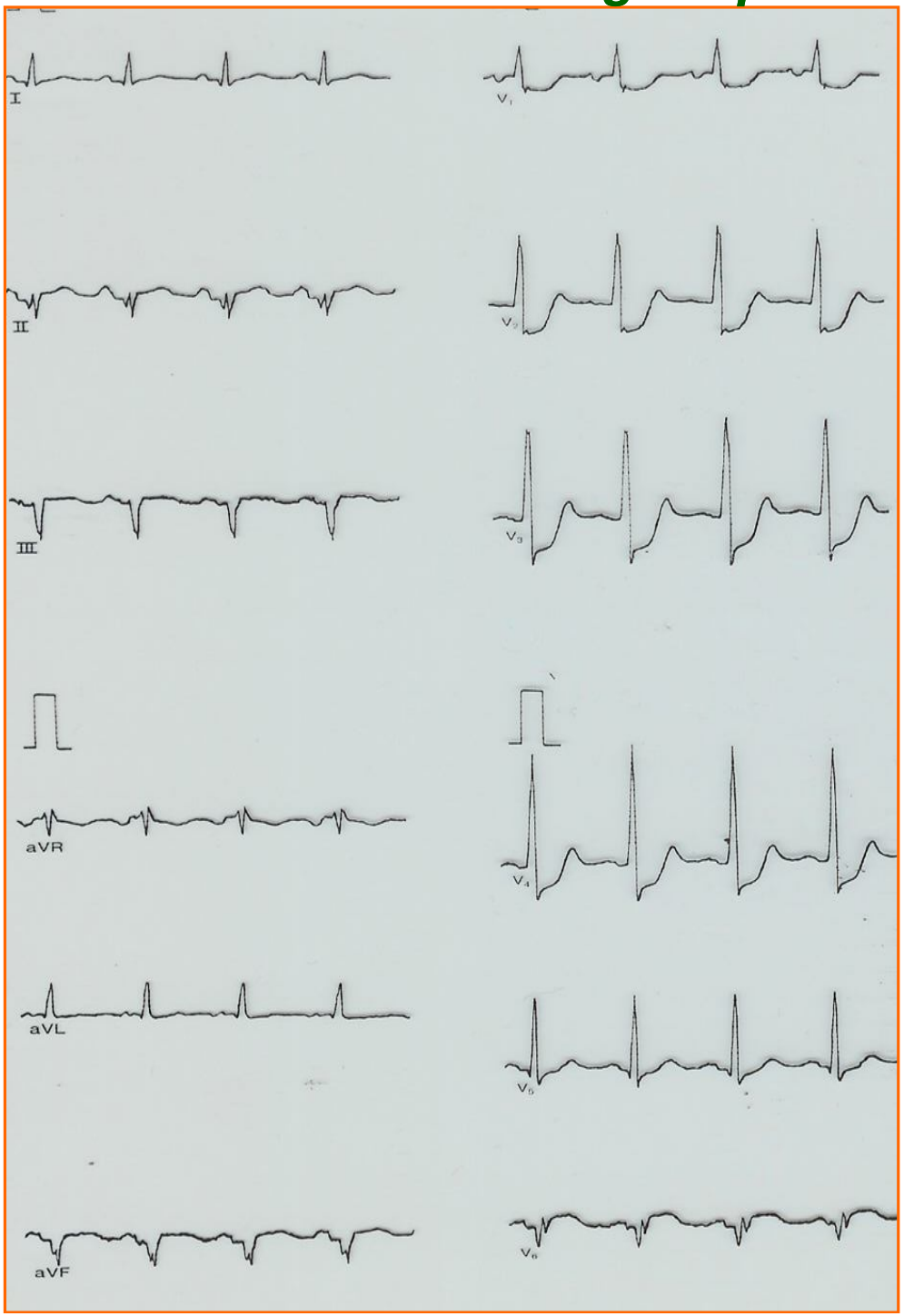

TROPONINA T	1,130	*
CK-MB massa	15,0	*
MIOGLOBINA	156,3	*

… sembra facile, senza insidia

N-ST EMI parete a/settale

Alfredo P. anni 62 angor tipico

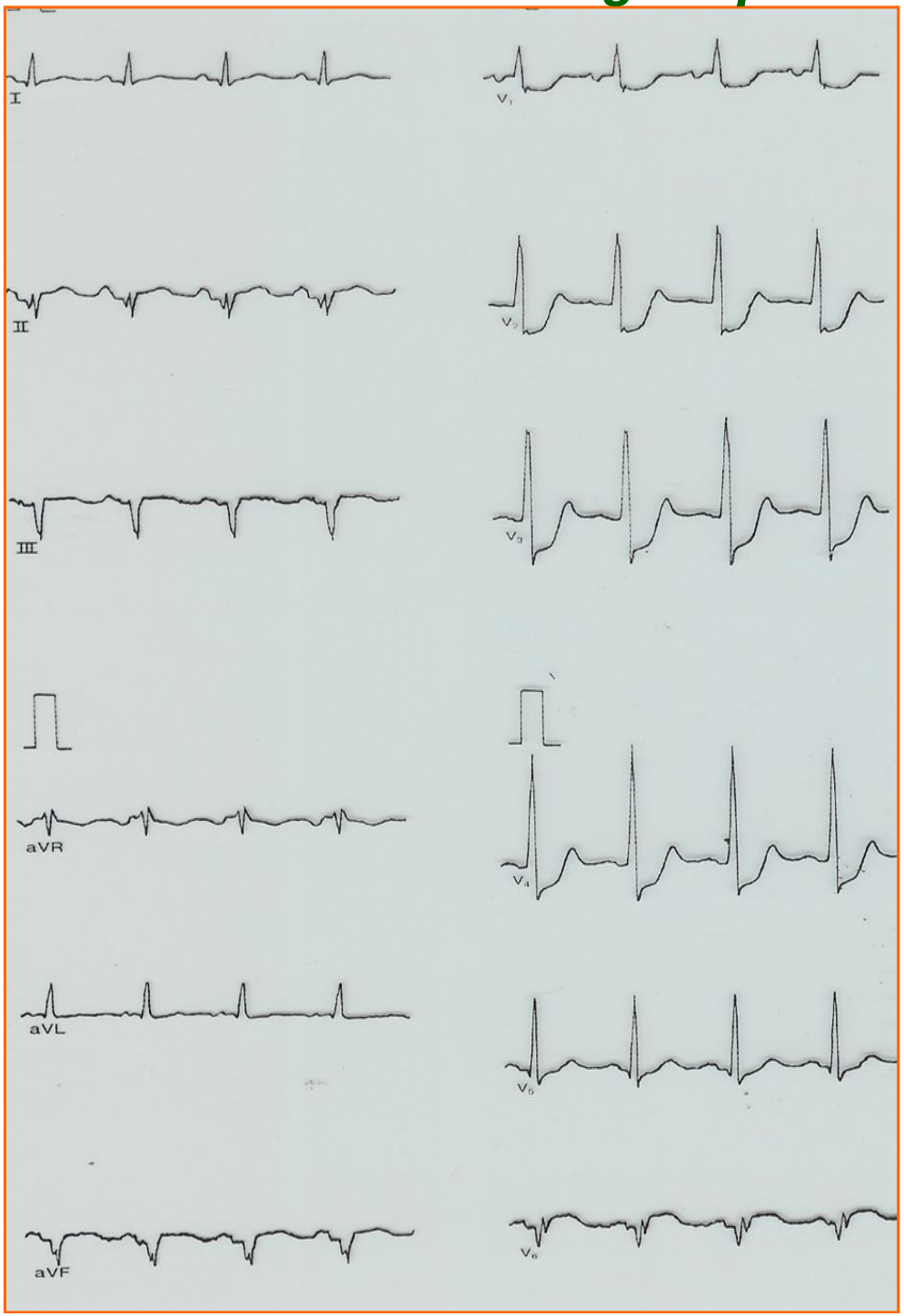

TROPONINA T	1,130	*
CK-MB massa	15,0	*
MIOGLOBINA	156,3	*

… sembra facile, senza insidia

N-ST EMI parete a/settale

ATTENZIONE…sempre considerare la possibilità di un

ST EMI …ma di quale parete?

ST EMI parete posteriore …sempre trascurata !!!

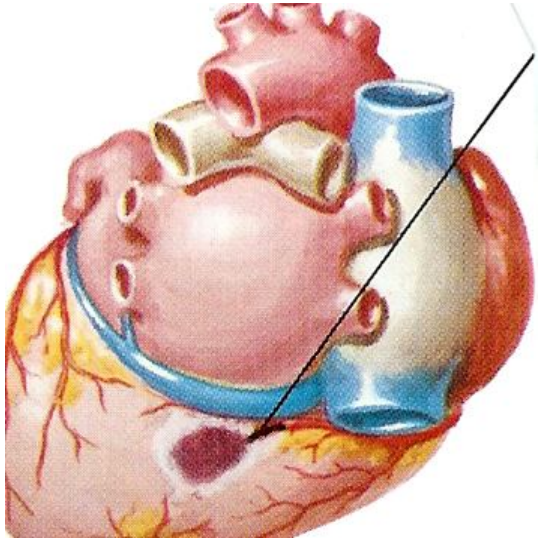

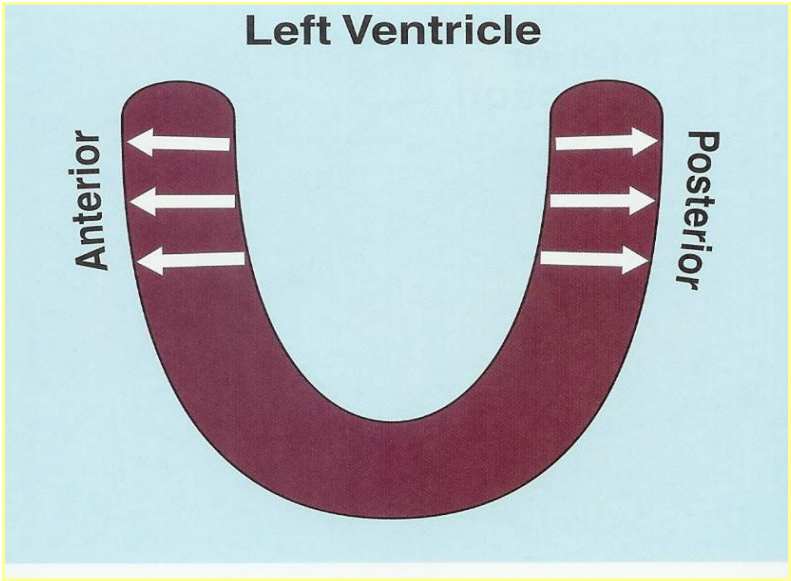

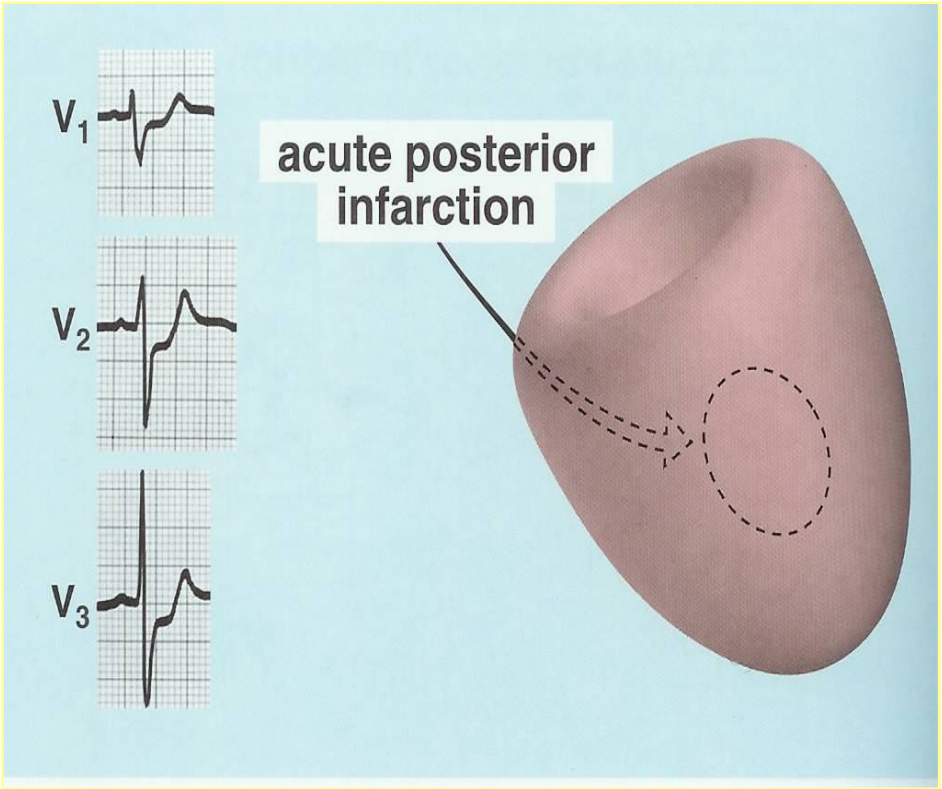



Posterior Infarction

…derivazione anteriore

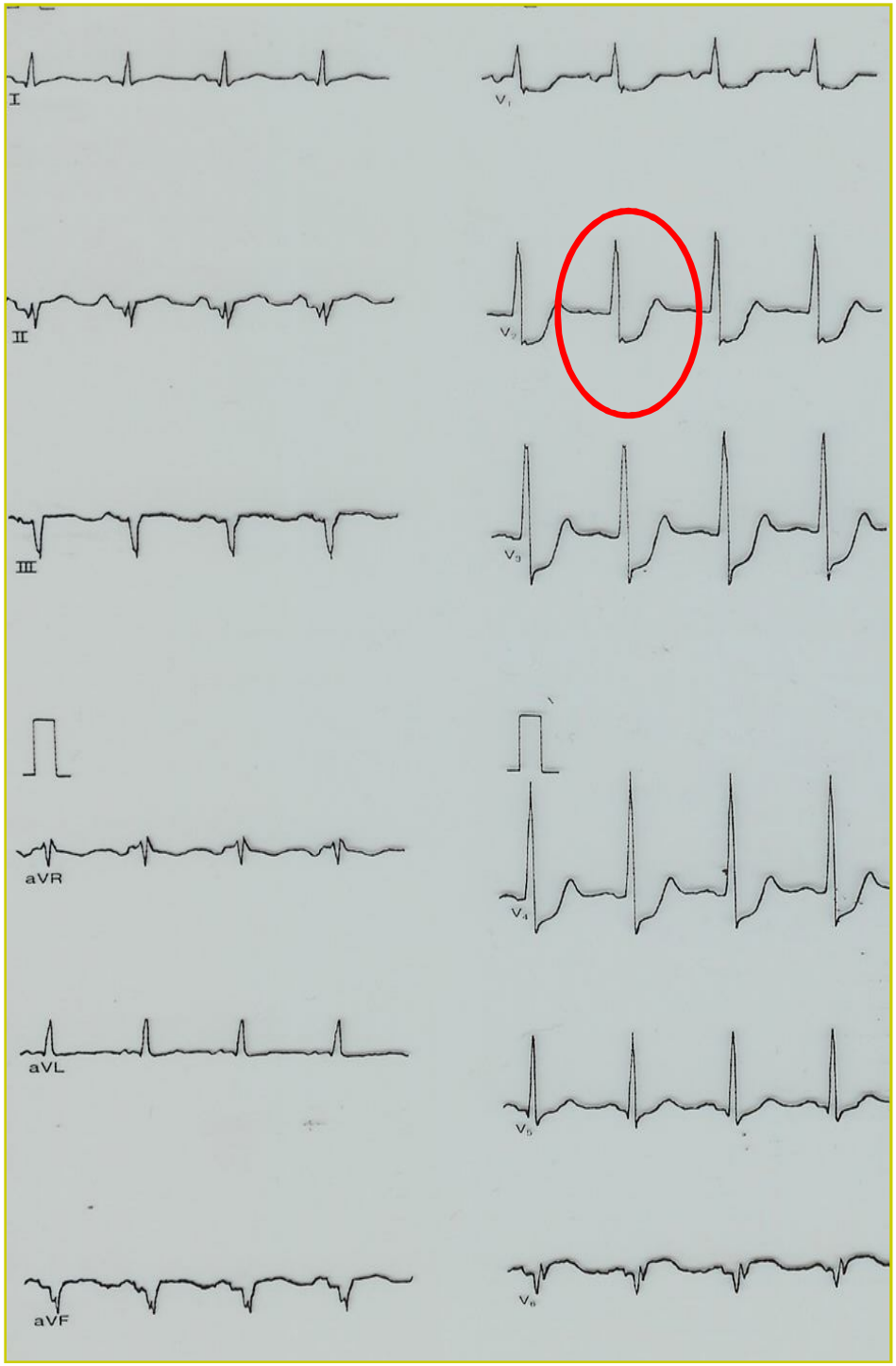

ST-EMI

parete posteriore

<u>V1 V2</u>

onda R alta e rapporto R/S = > 1
ST sottolivellato

Gaetano M. anni 58 in P.S. per angor tipico

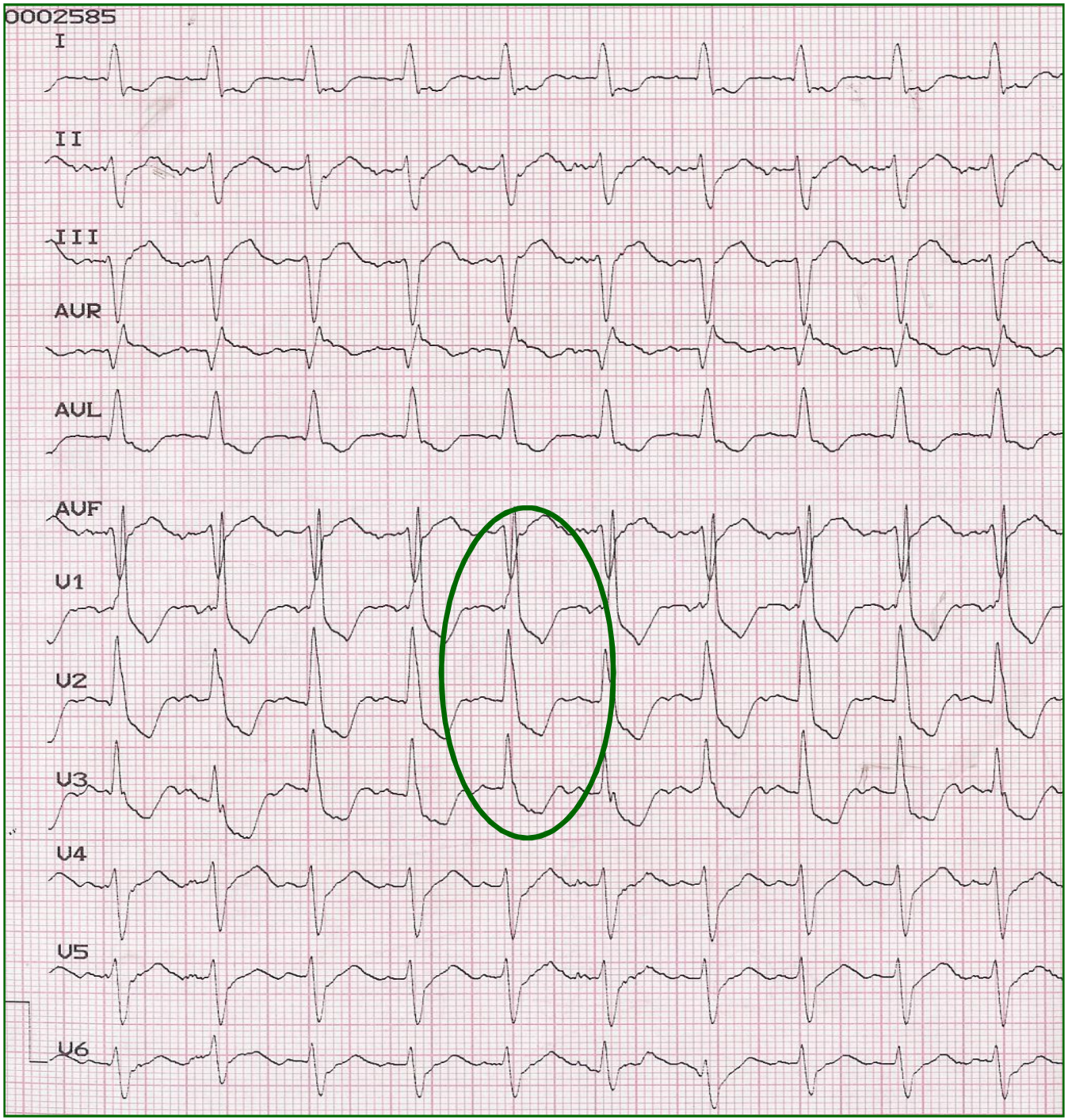

Gaetano M. anni 58 in P.S. per angor tipico

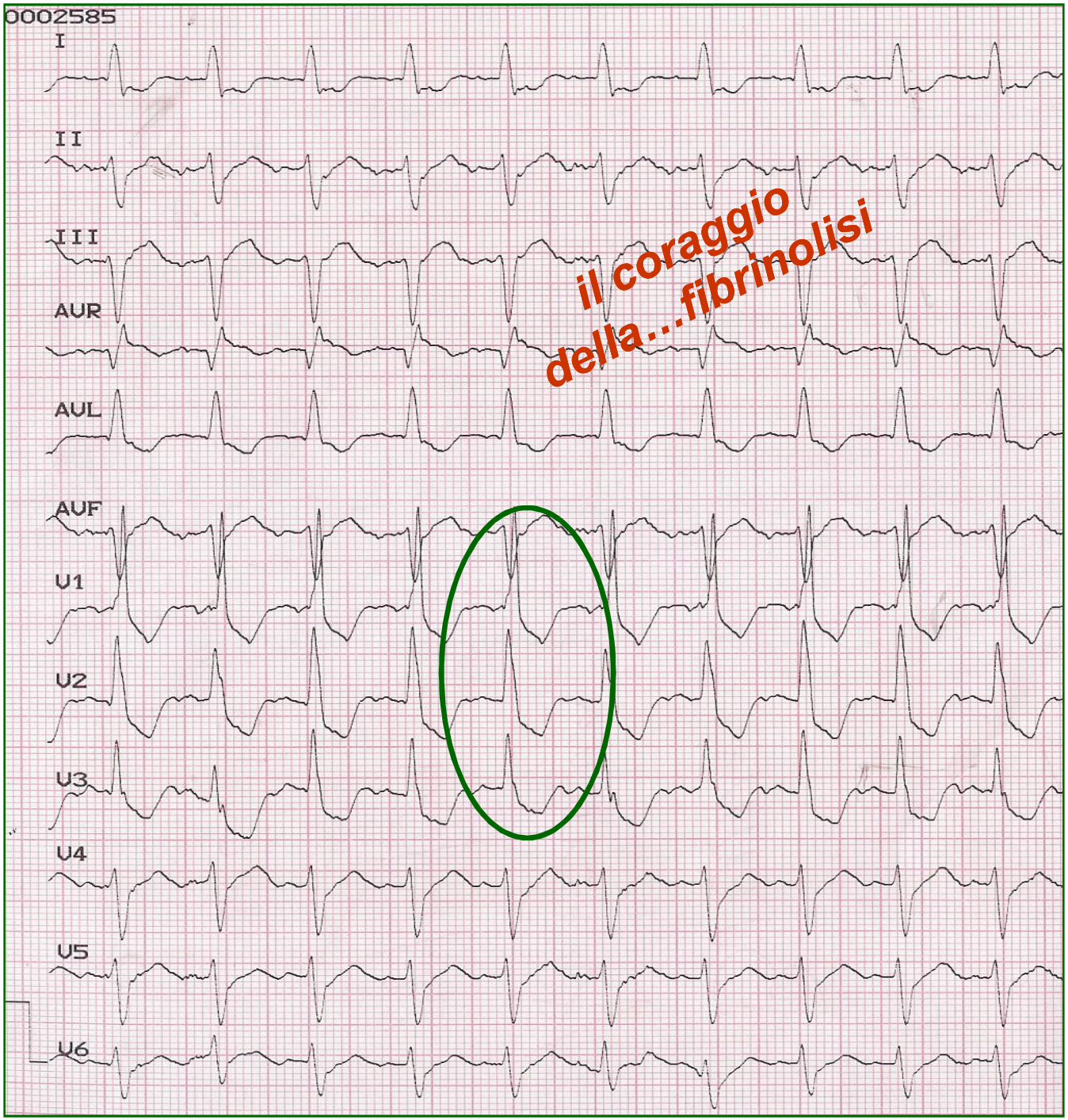

…i tranelli continuano



segmento ST sopra…!
chi dice che è
sempre ischemico?

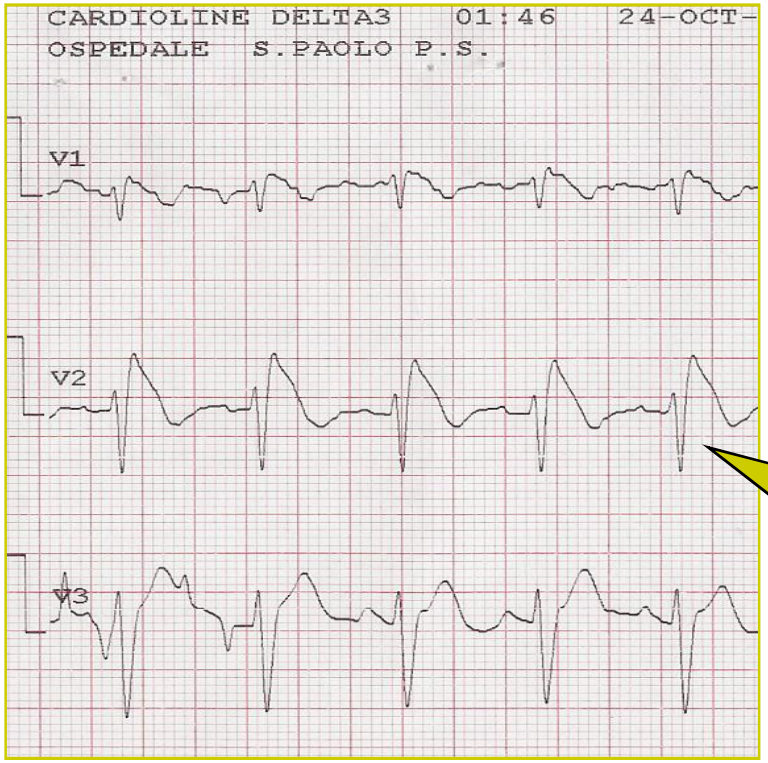
CARDIOLINE DELTA3 01:46 24-OCT-
OSPEDALE S.PAOLO P.S.
V1
V2
V3

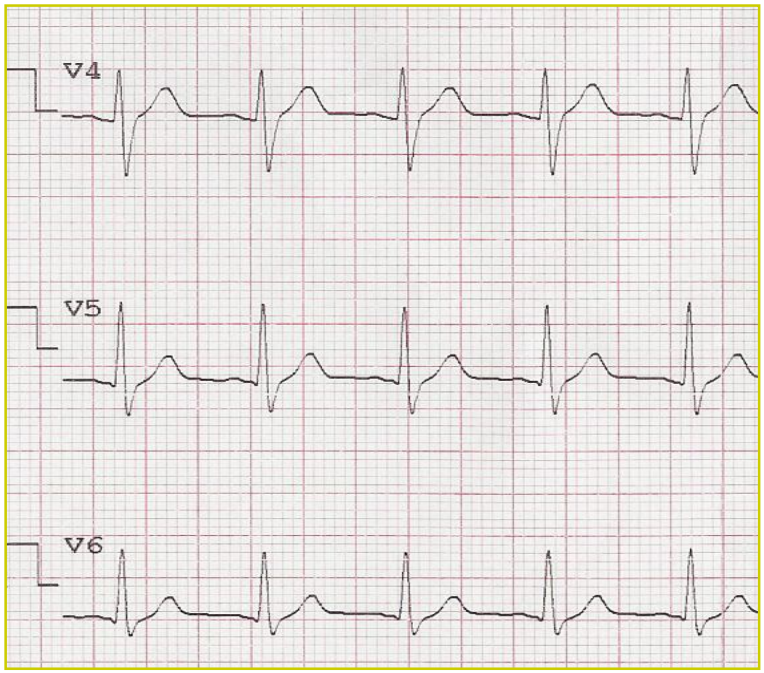
V4
V5
V6

S. di Brugada

Tipo 1

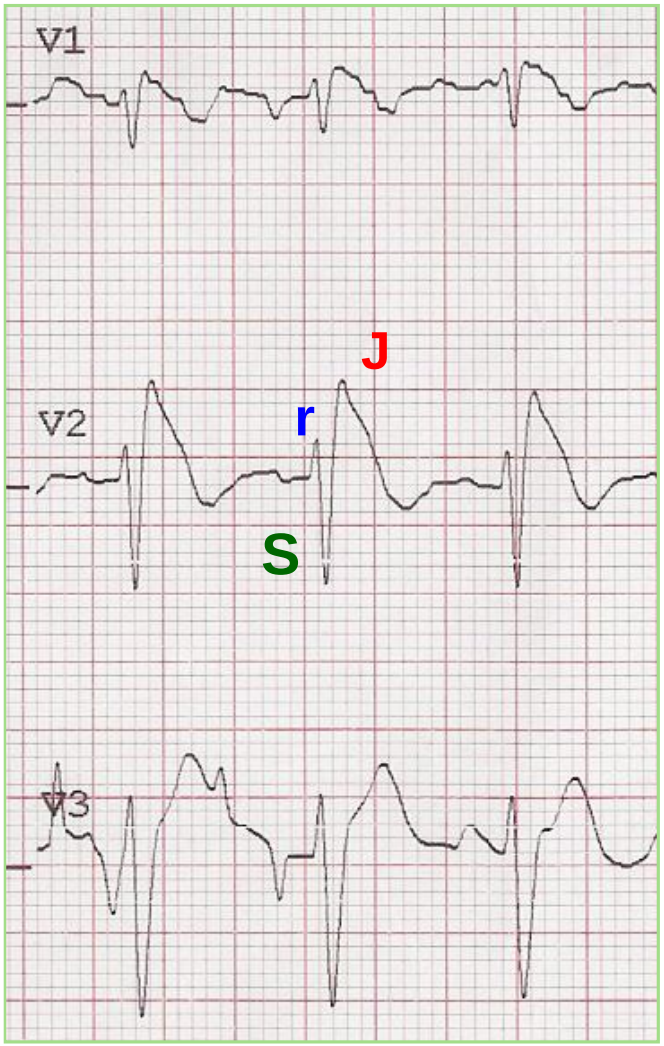

pattern-ST a tenda

Tipo 2

Tipo 3

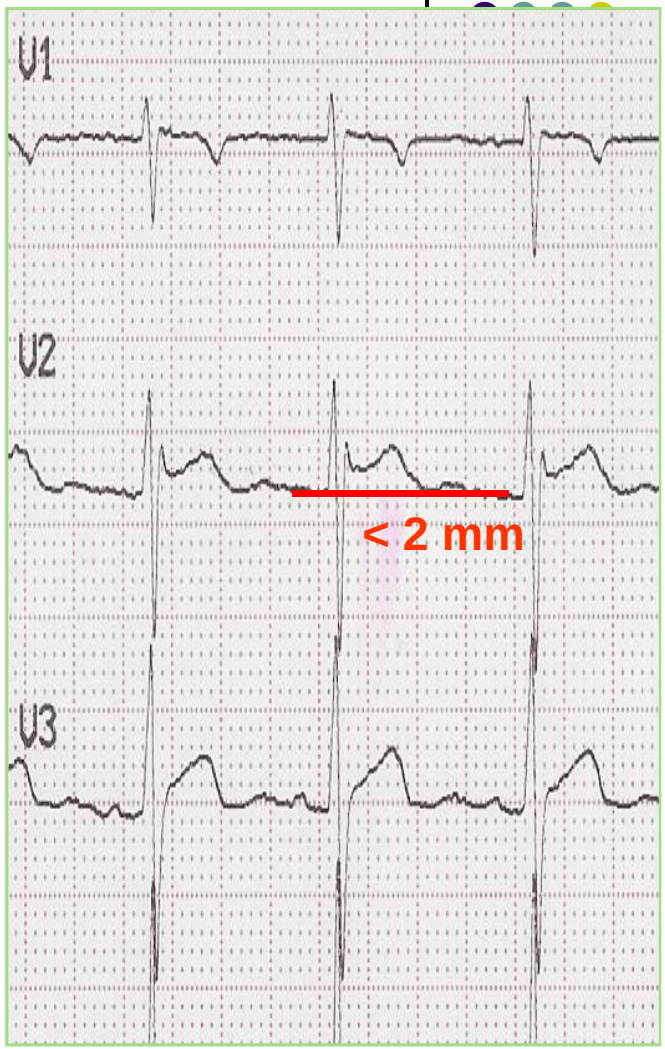

pattern-ST a sella

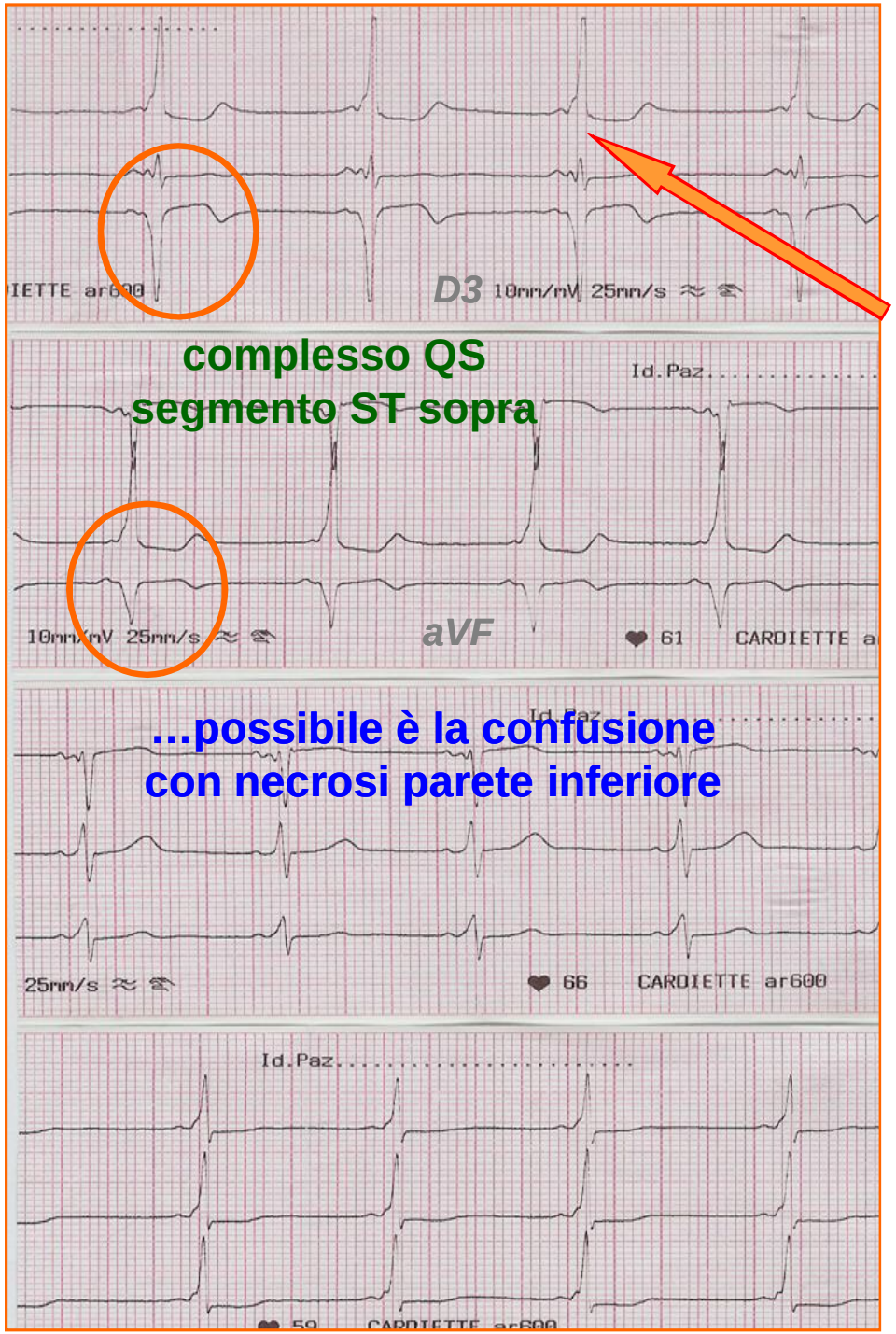

onda delta

... fascio di Kent postero-settale

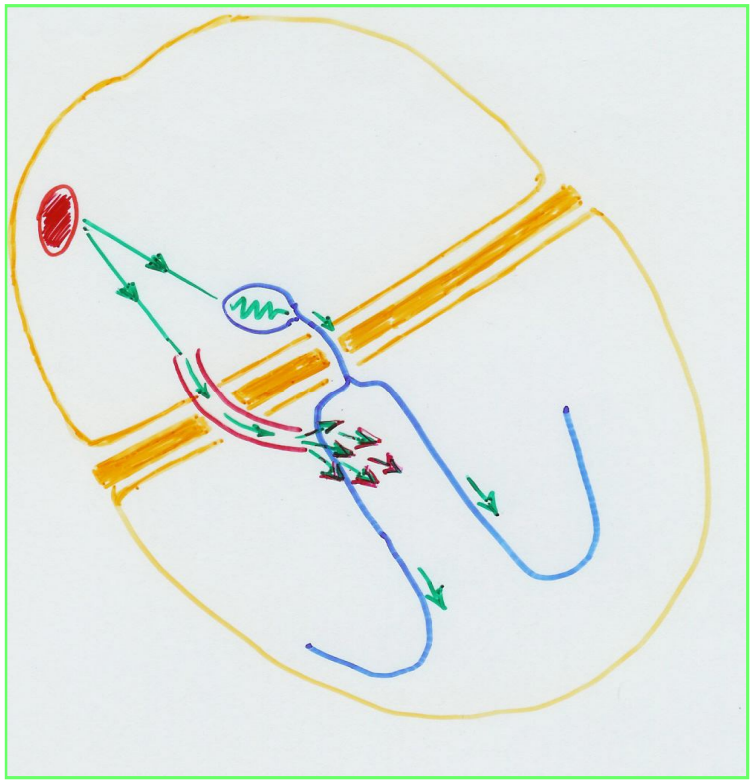

Sandro V. anni 29 polipnea modesta dopo stress psico-fisico

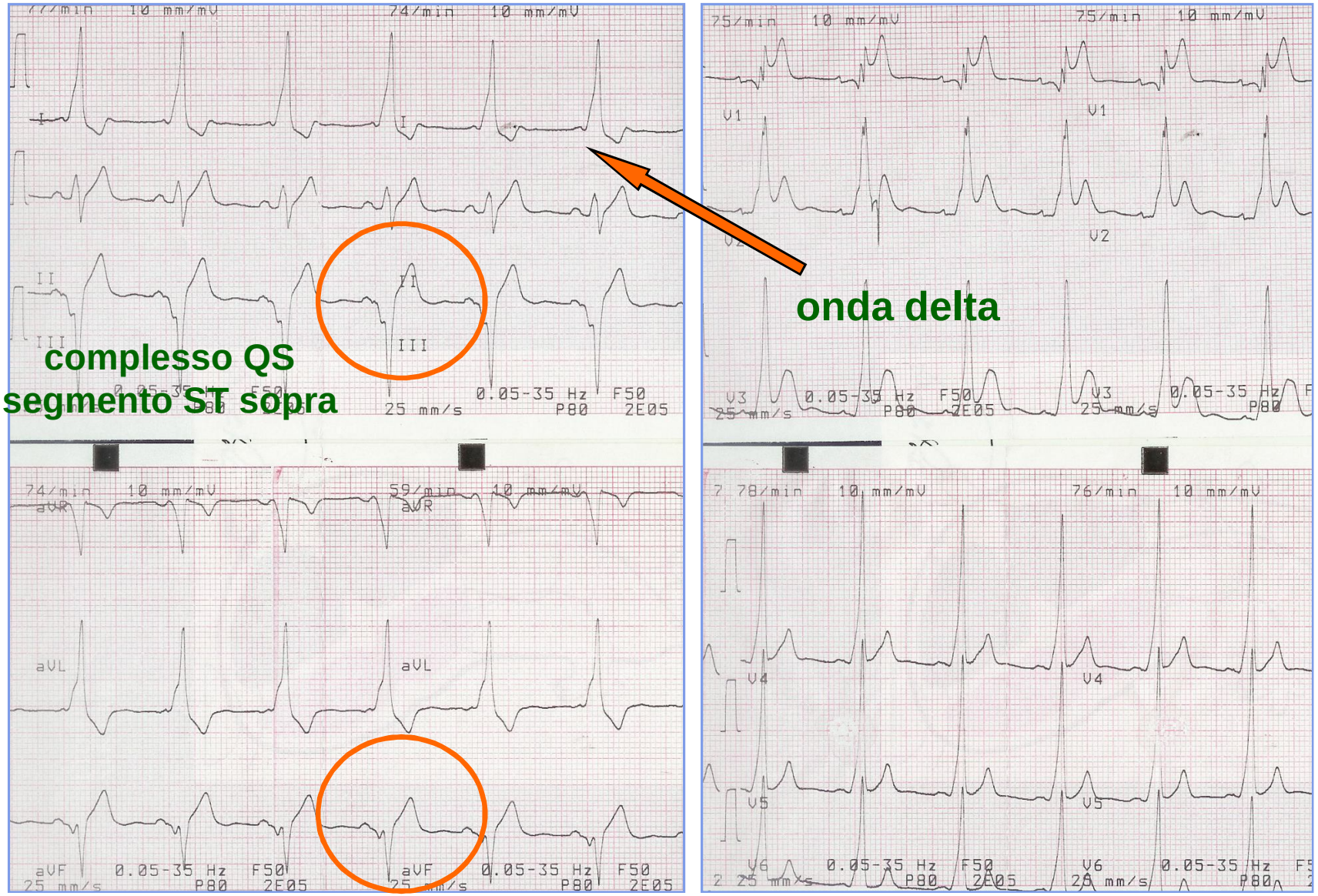

Kent…postero-settale sinistro

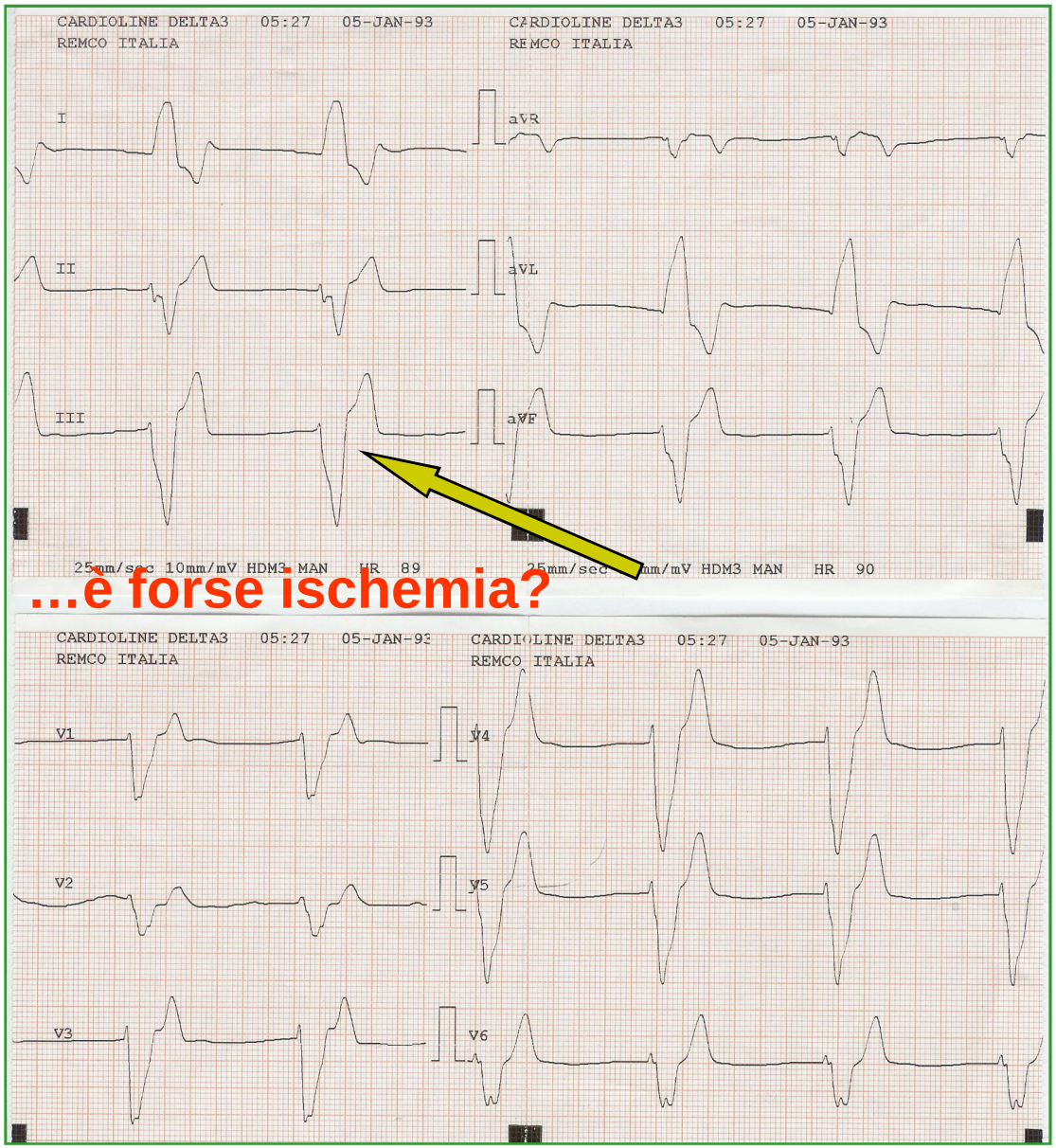

...è forse ischemia?

CREATININA	9,11	*
SODIO	141	
POTASSIO	10,2	*

iperKaliemia

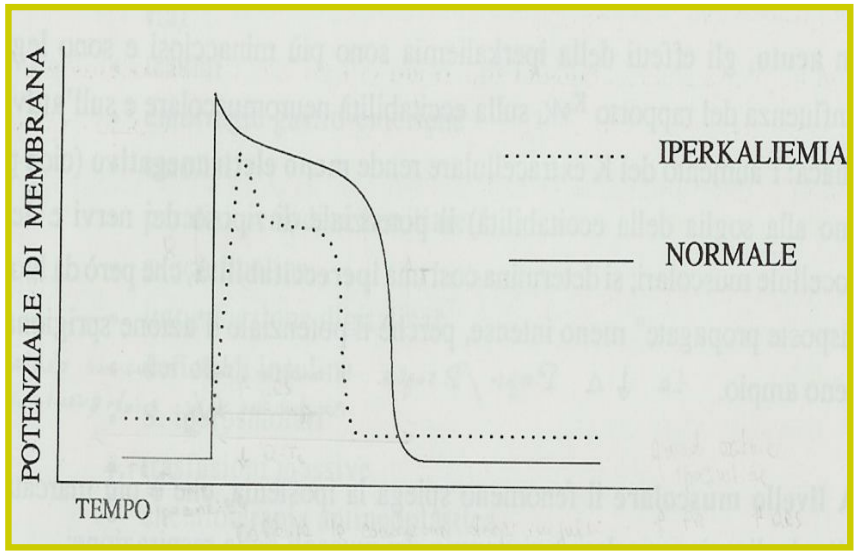

QRS largo QT corto T aguzza

alterata attivazione atriale

Circulation 2005 172; 295-296

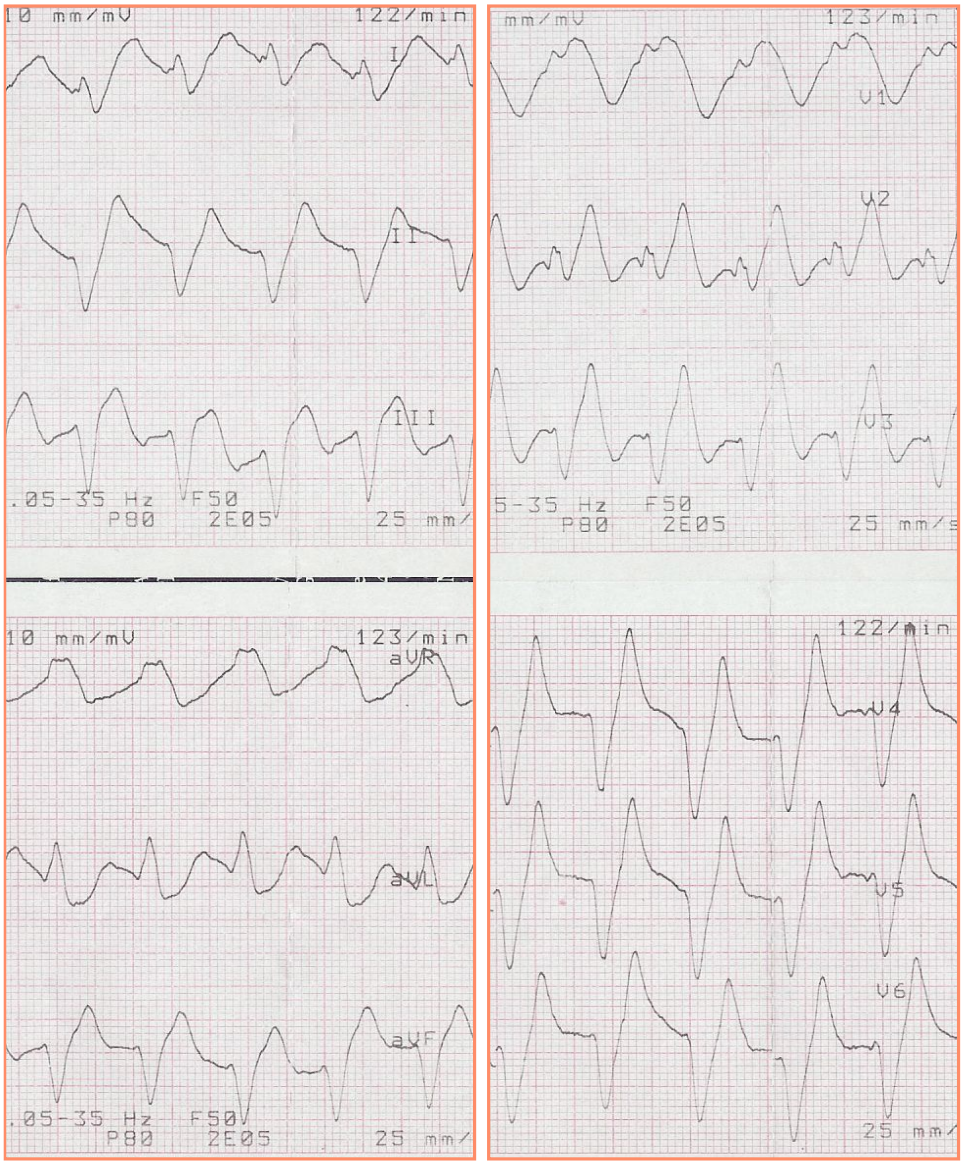

K = 10.2 mEq/l

K = 4.2 mEq/l

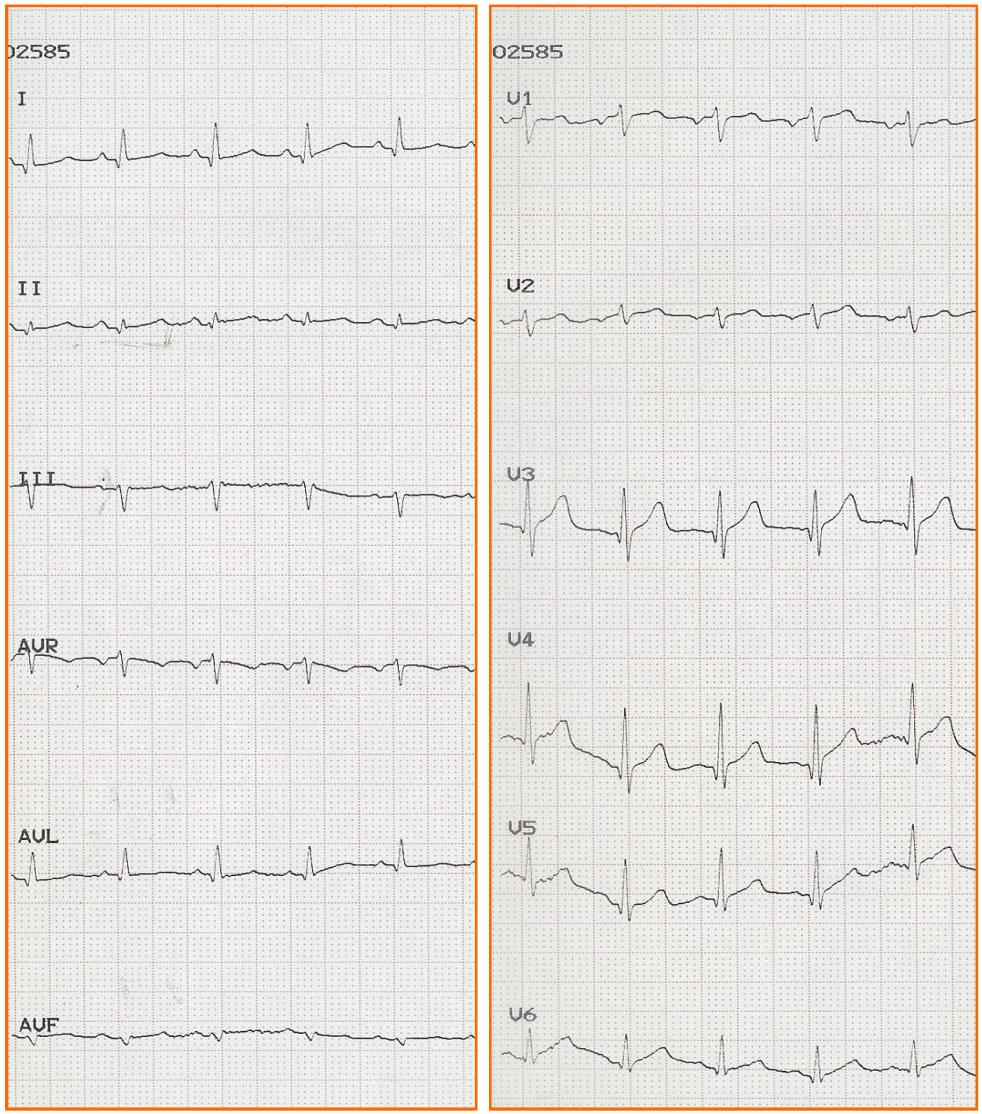

Flora D. a 46

in P.S. per insufficienza renale acuta

…variante normale con ST-sopra

early-repolarization

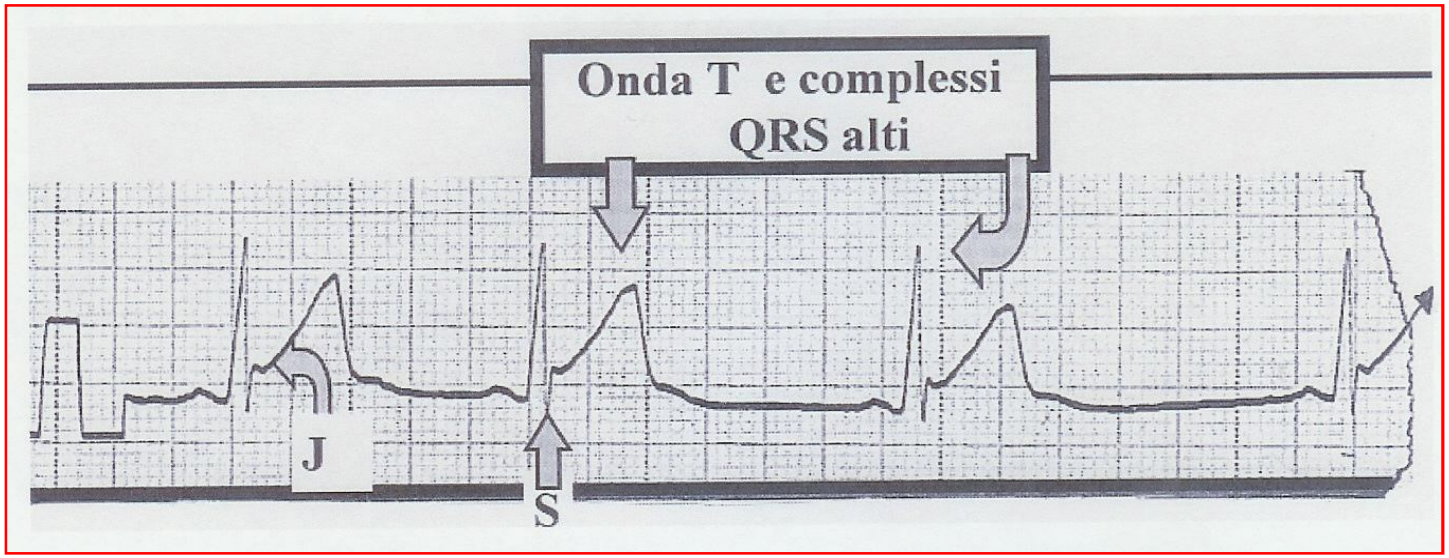

giovane sano vagotonico

complesso QRS e onda T di alto voltaggio nelle precordiali

evidente presenza di onda S a cui segue innalzamento del punto J

K.Wang R.W.Asinger-and H.J.L.Marriott the New England Journal of Medicine november 27, 2003 vol 349 no. 22

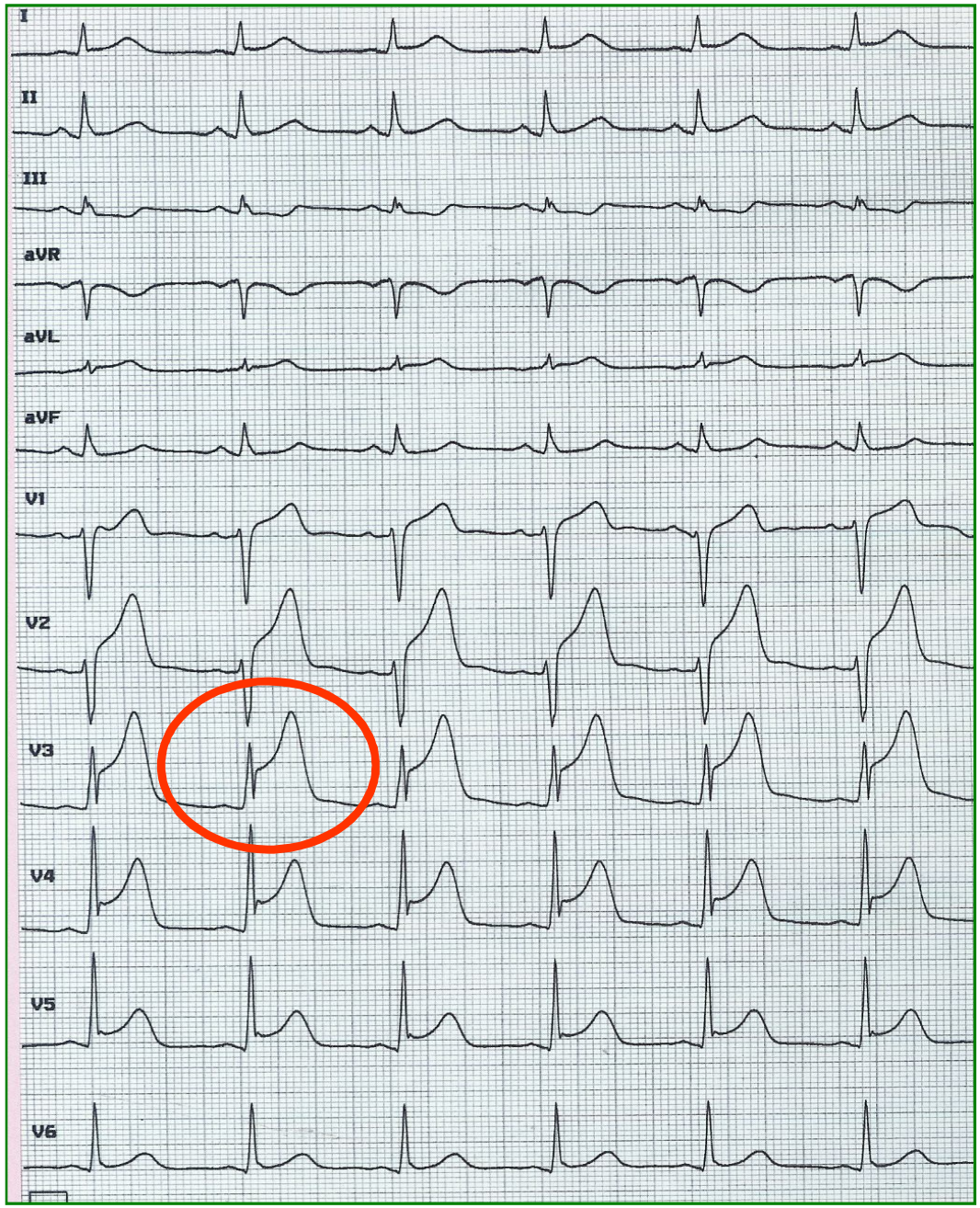

Stefania D. anni 34

in P.S. per epigastralgia violenta
parametri vitali conservati
equilibrio metabolico

aumentata eterogeneicità transmurale
della ripolarizzazione ventricolare

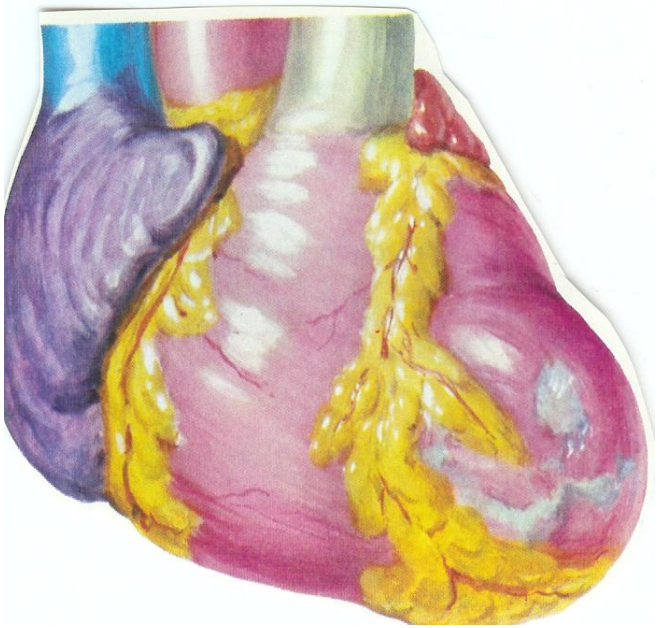

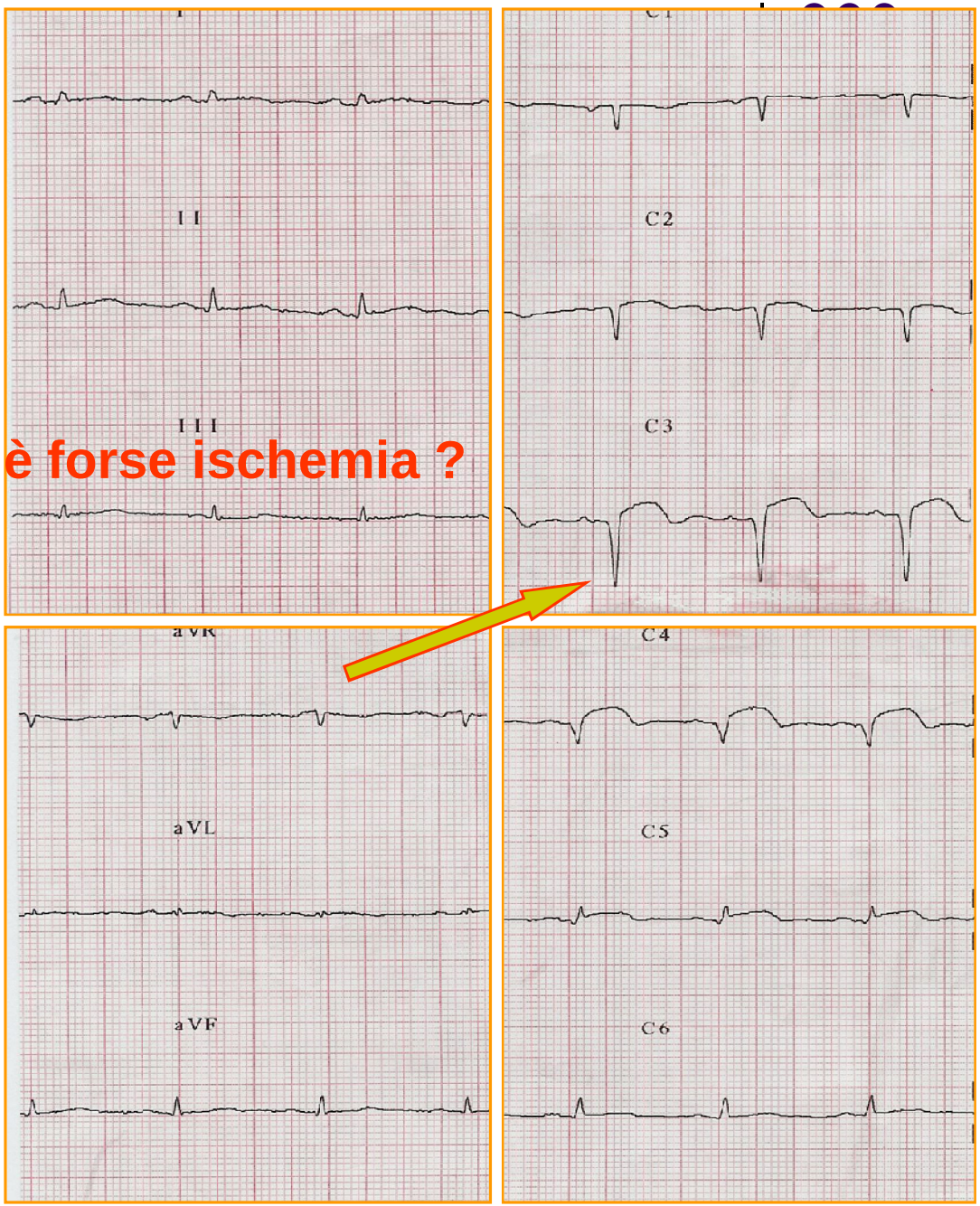

…è forse ischemia ?

…e l'aneurisma post-ischemico?

Armando pregressa necrosi transmurale parete anteriore rilievo eco di aneurisma setto-punta

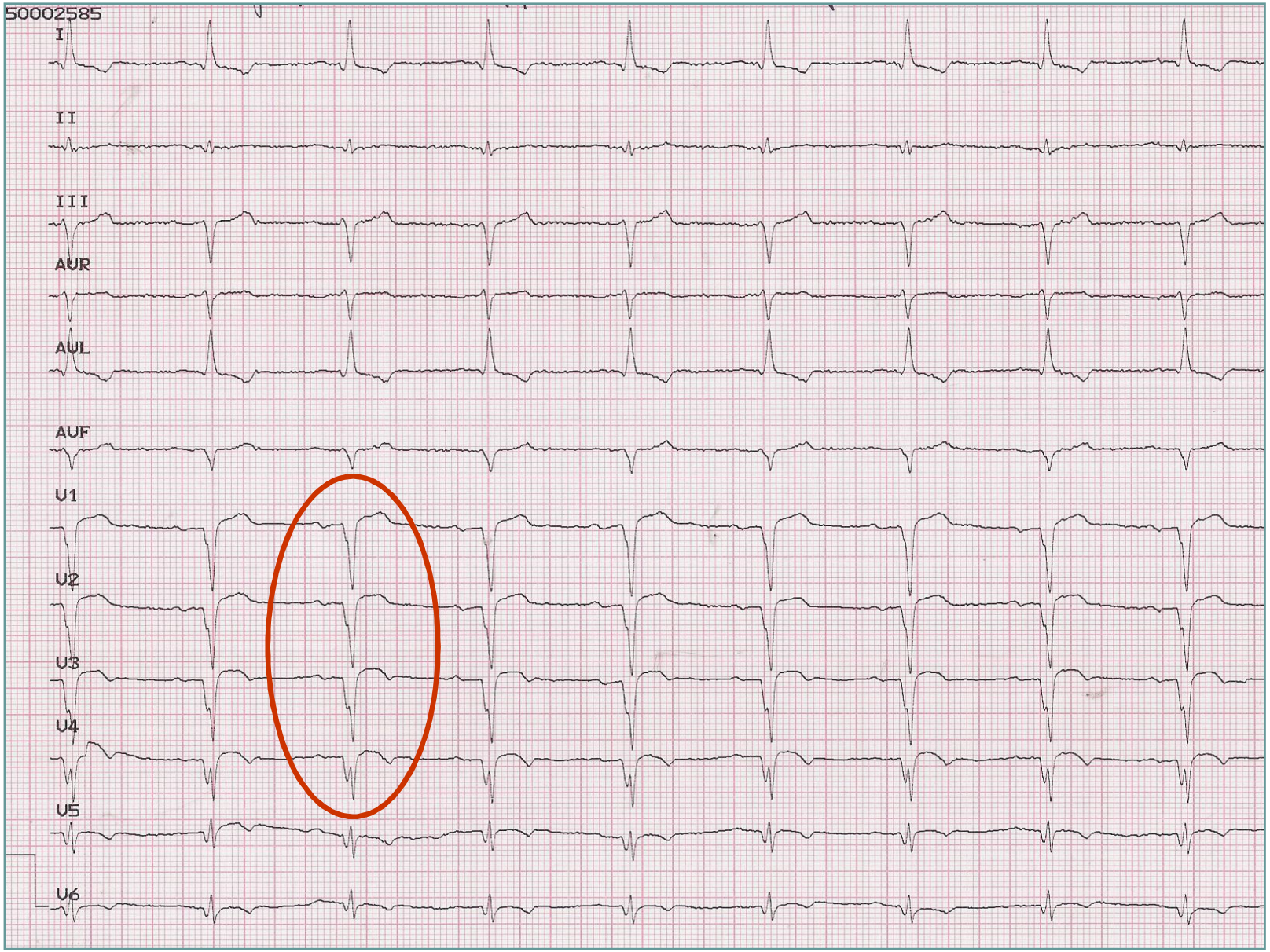

Paola a 43 in p.s. per febbre e dolore toracico trafittivo

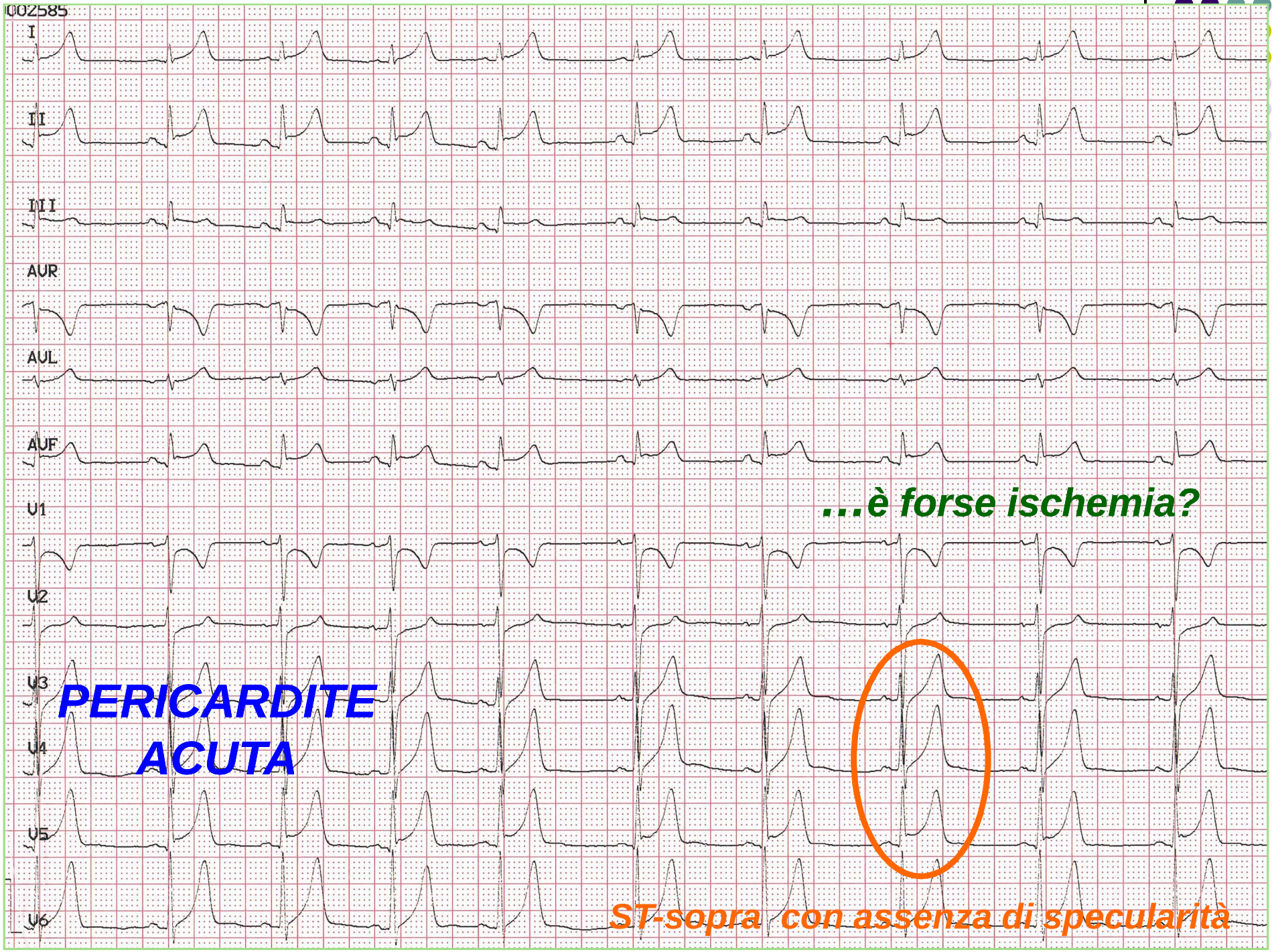

Paola a 43 in p.s. per febbre e dolore toracico trafittivo

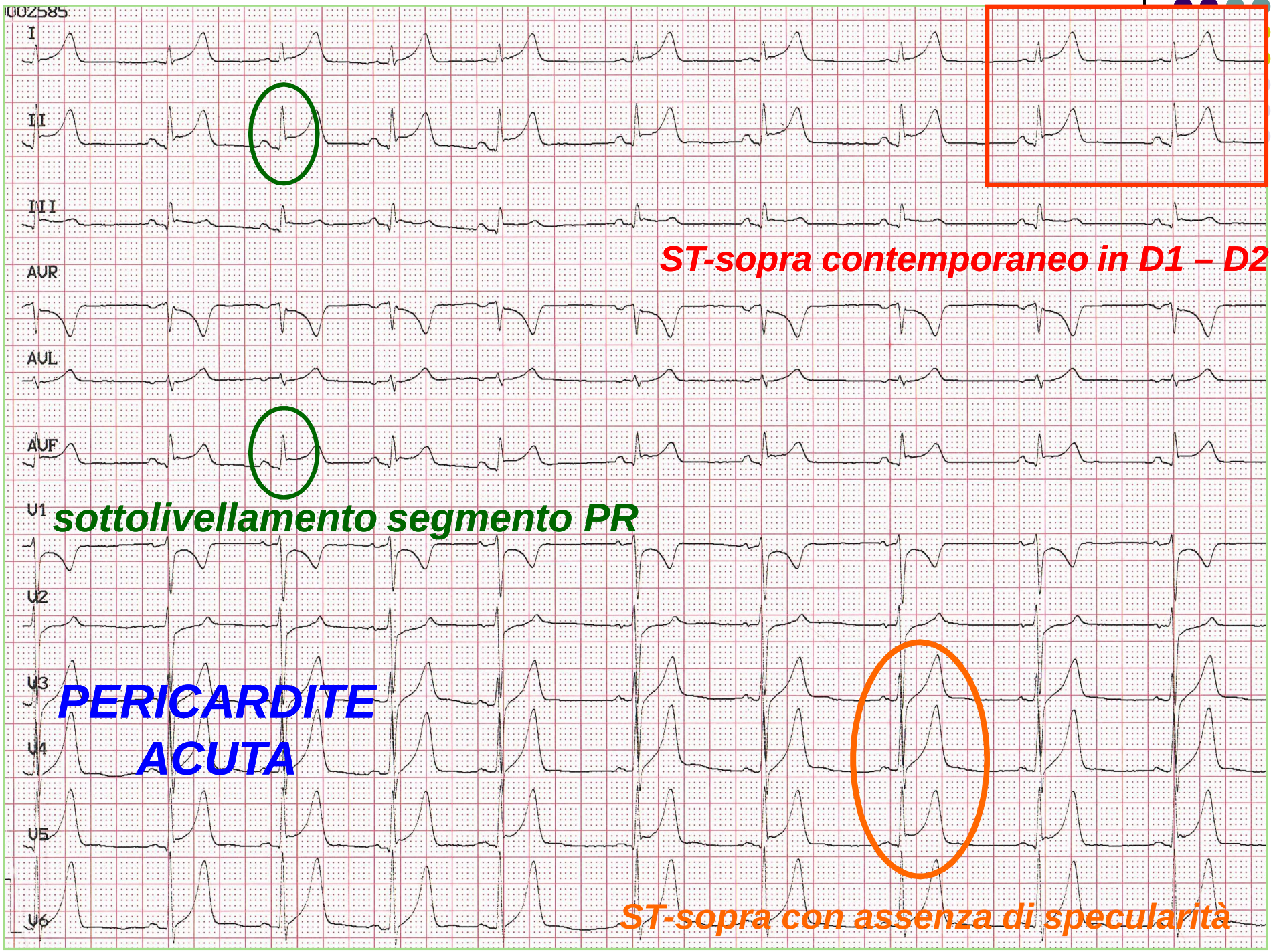

Esempi di artefatti ecg.fici da non corretto utilizzo del filtro anti-instabilità della linea di base

G. Slavich, L. Di Benedetto, R. Sbrojavacca, E. Bocin

Ital. Heart J Suppl. 2003; 4 (6): 515-517

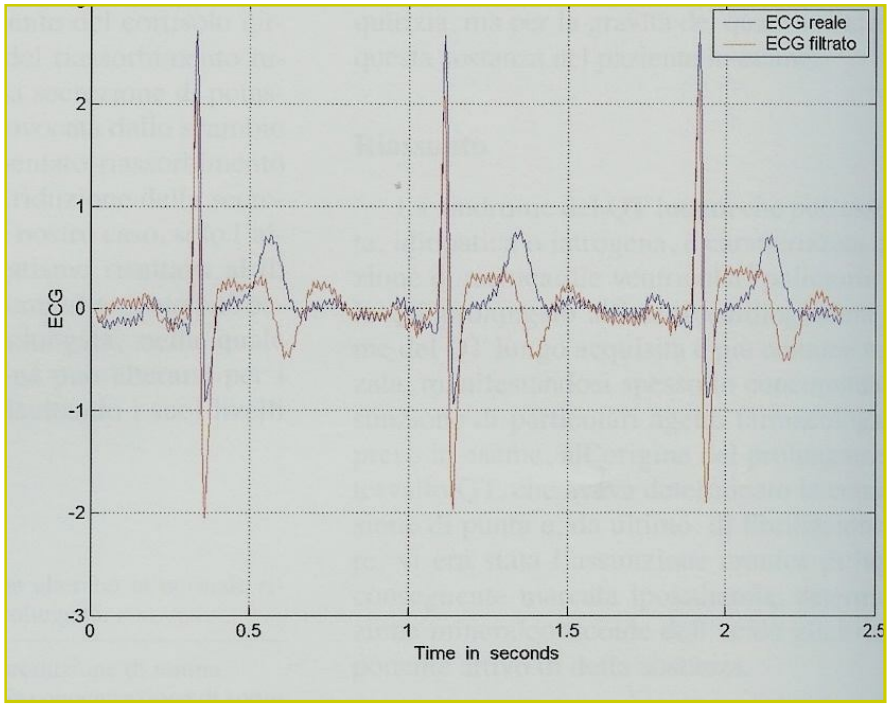

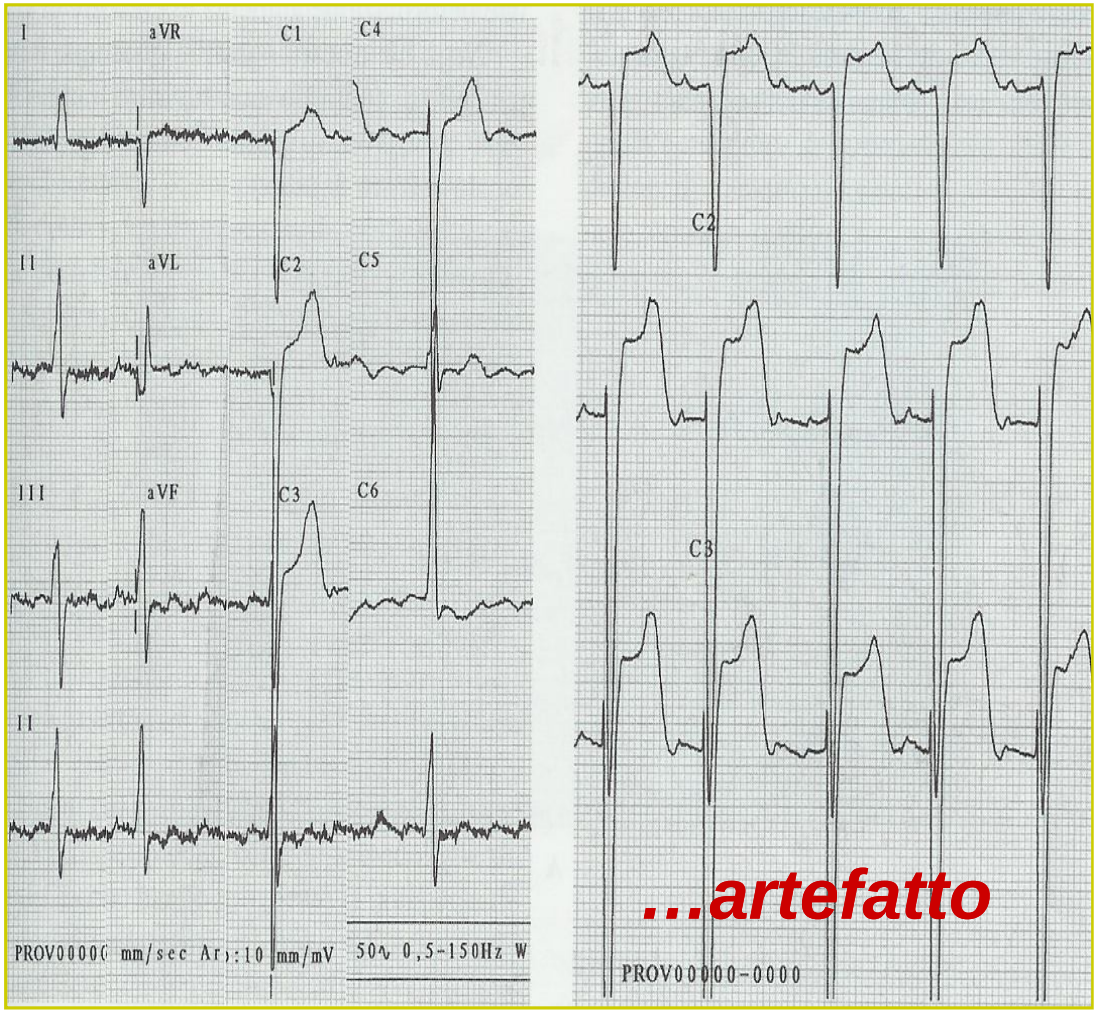

…e l'angina variante di Prinzmetal ?

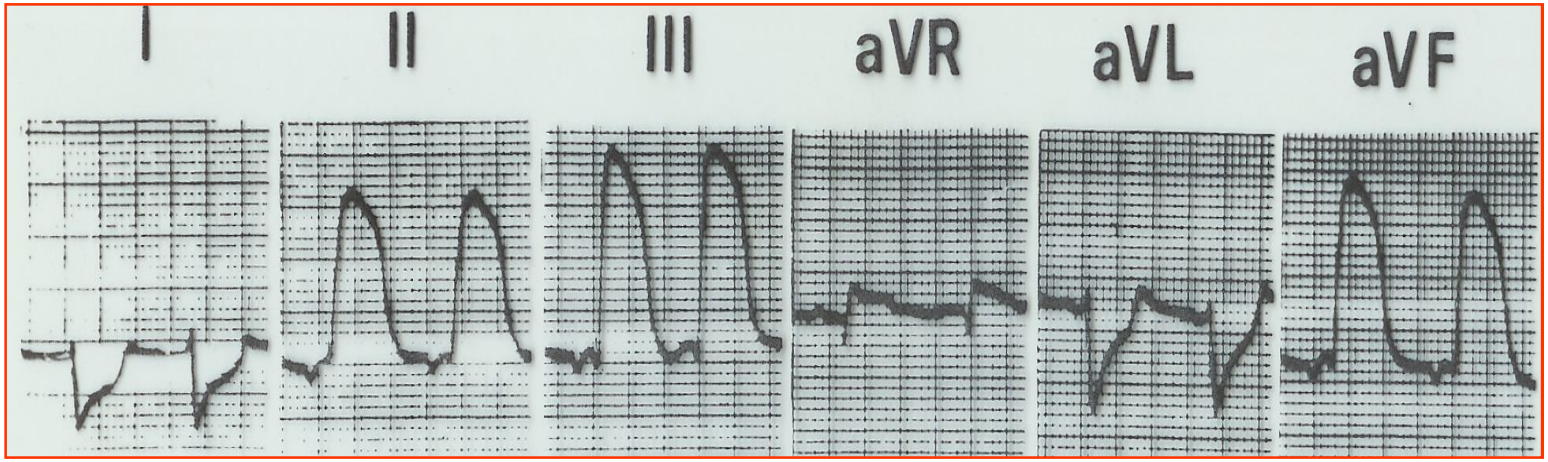

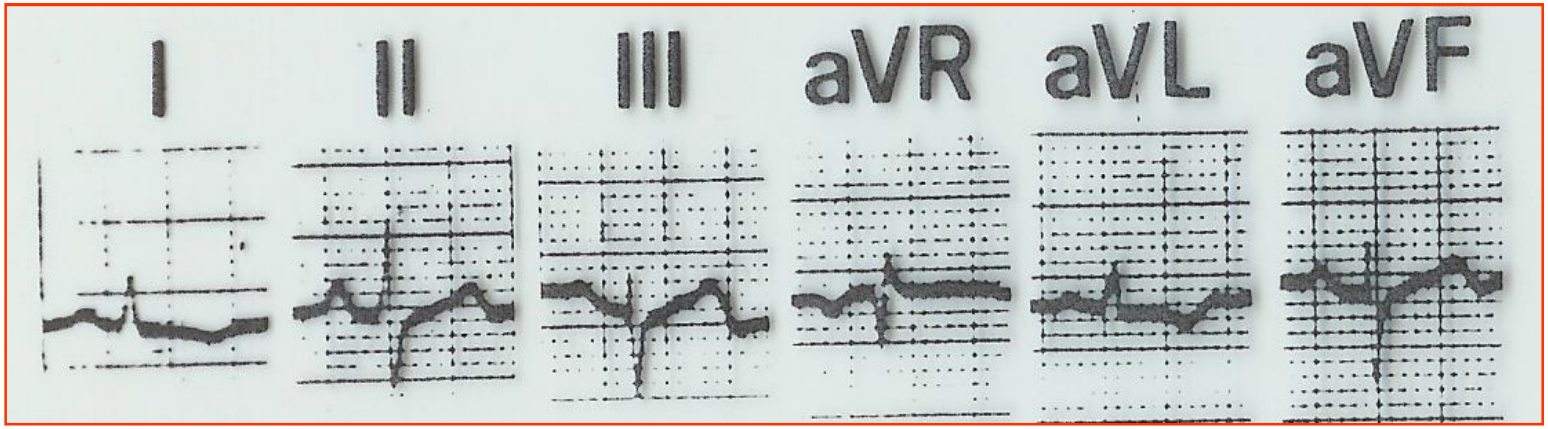

…dopo alcuni minuti

TROPONINA T	< 0.010
CK-MB massa	1,2
MIOGLOBINA	42,7

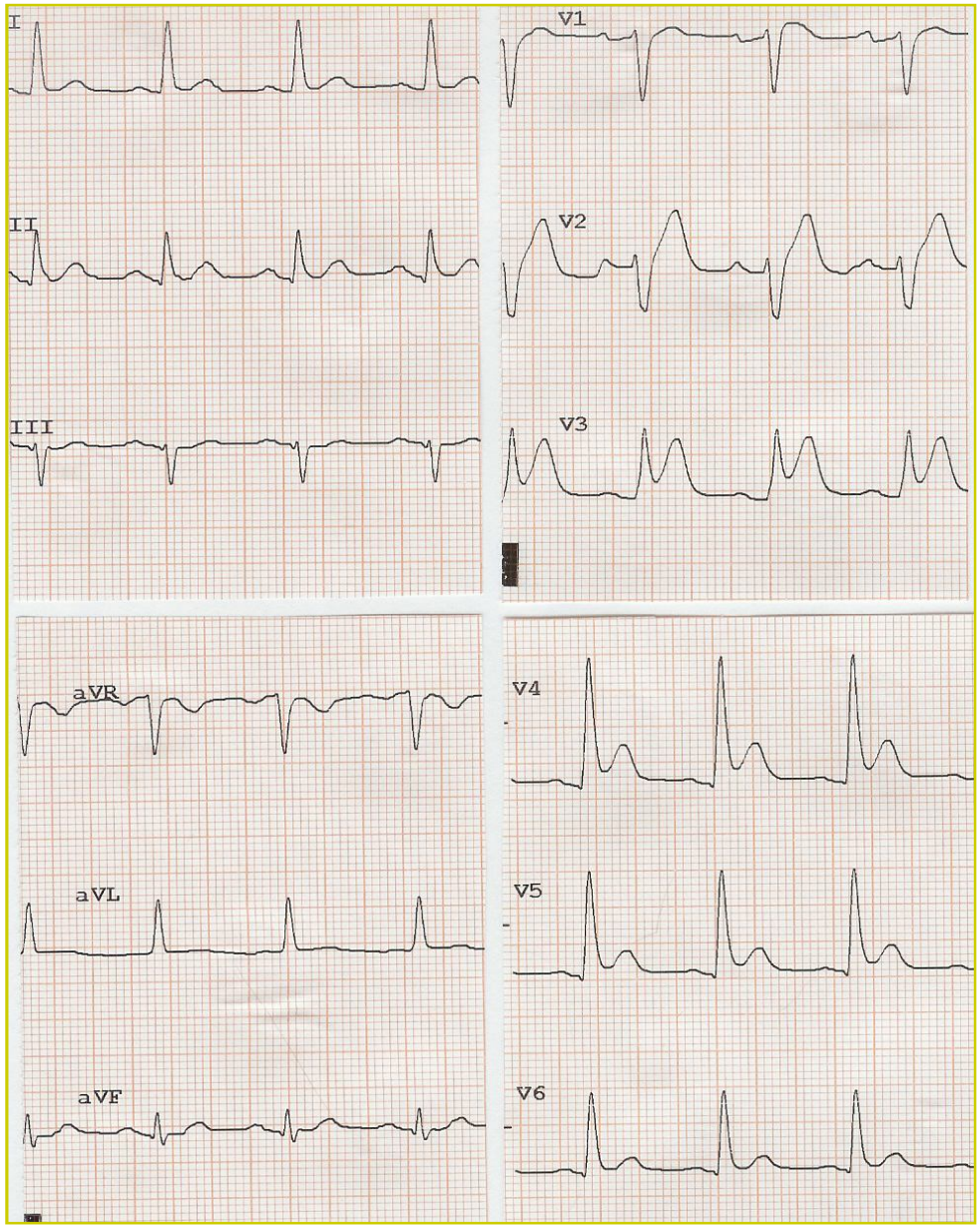

LUCA angor tipico

anni 57 diabete mellito

dopo alcuni minuti…spontaneamente

…altri tranelli,
ma anche altre perle !

ipertrofia ventricolare sx

blocchi di branca sx

pace-maker



attenzione al… blocco di branca sinistra

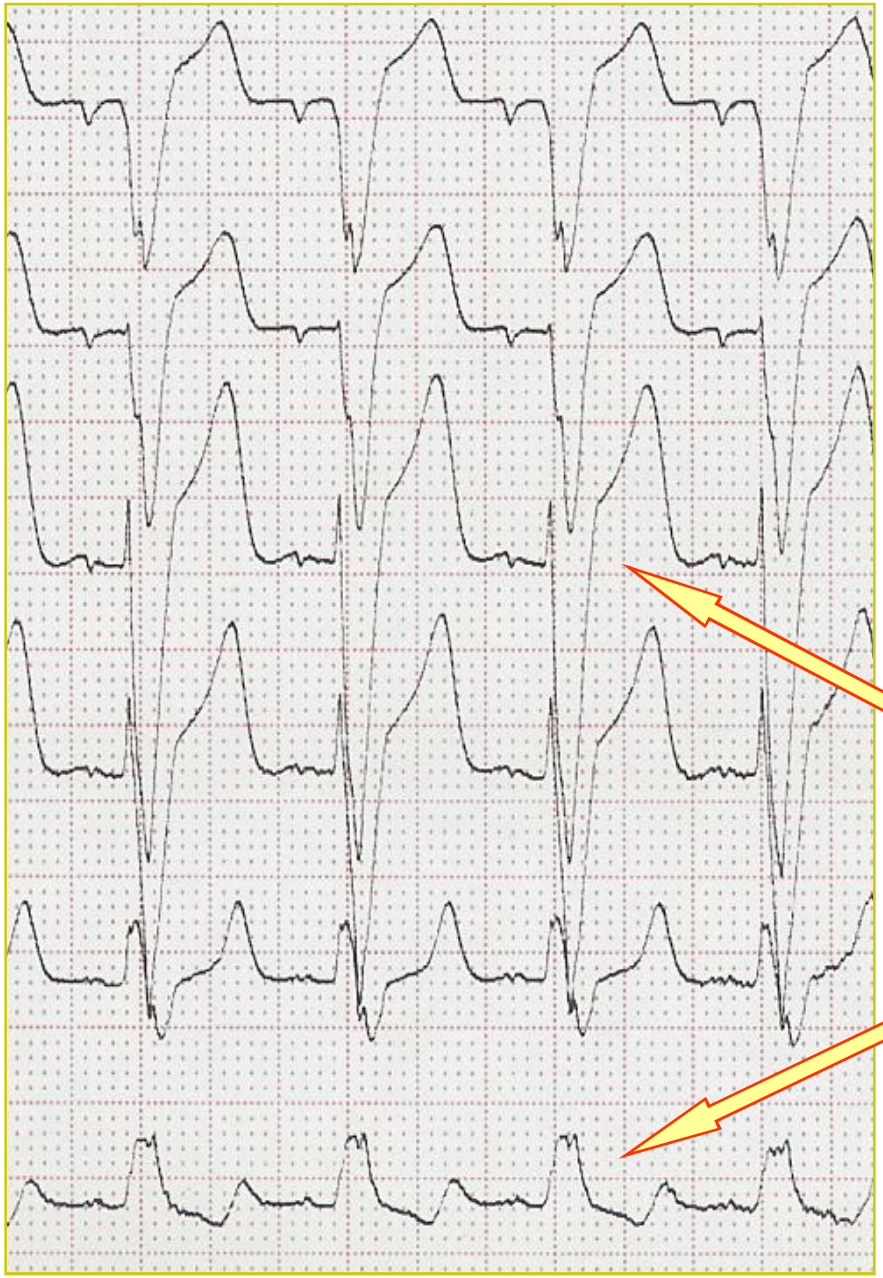

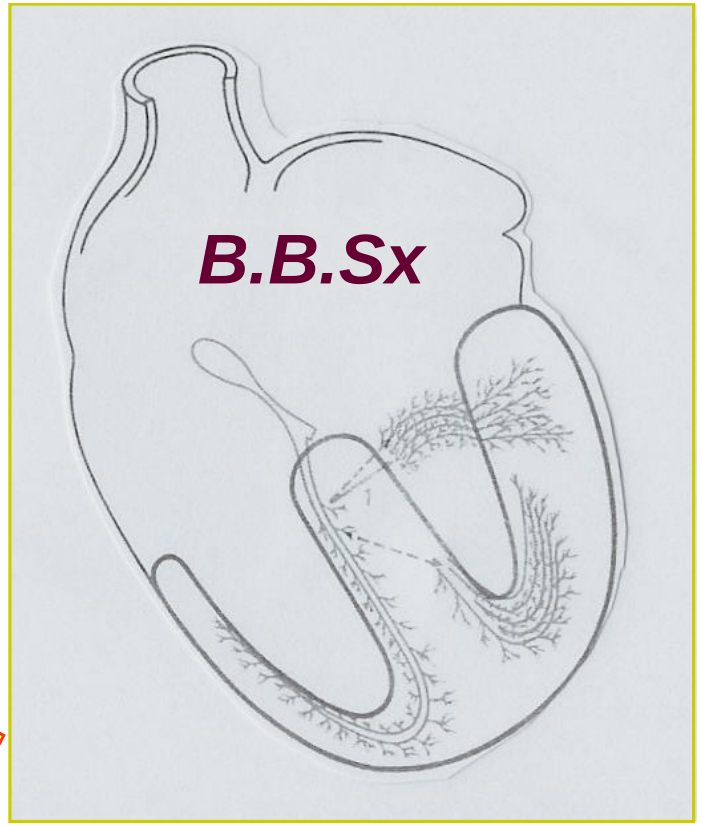

The NEW ENGLAND JOURNAL of MEDICINE

VOL. 349 NO. 22

ESTABLISHED IN 1812 NOVEMBER 27, 2003 WWW.NEJM.ORG

ma attenzione anche alle …
ipertrofie ventricolari Sx

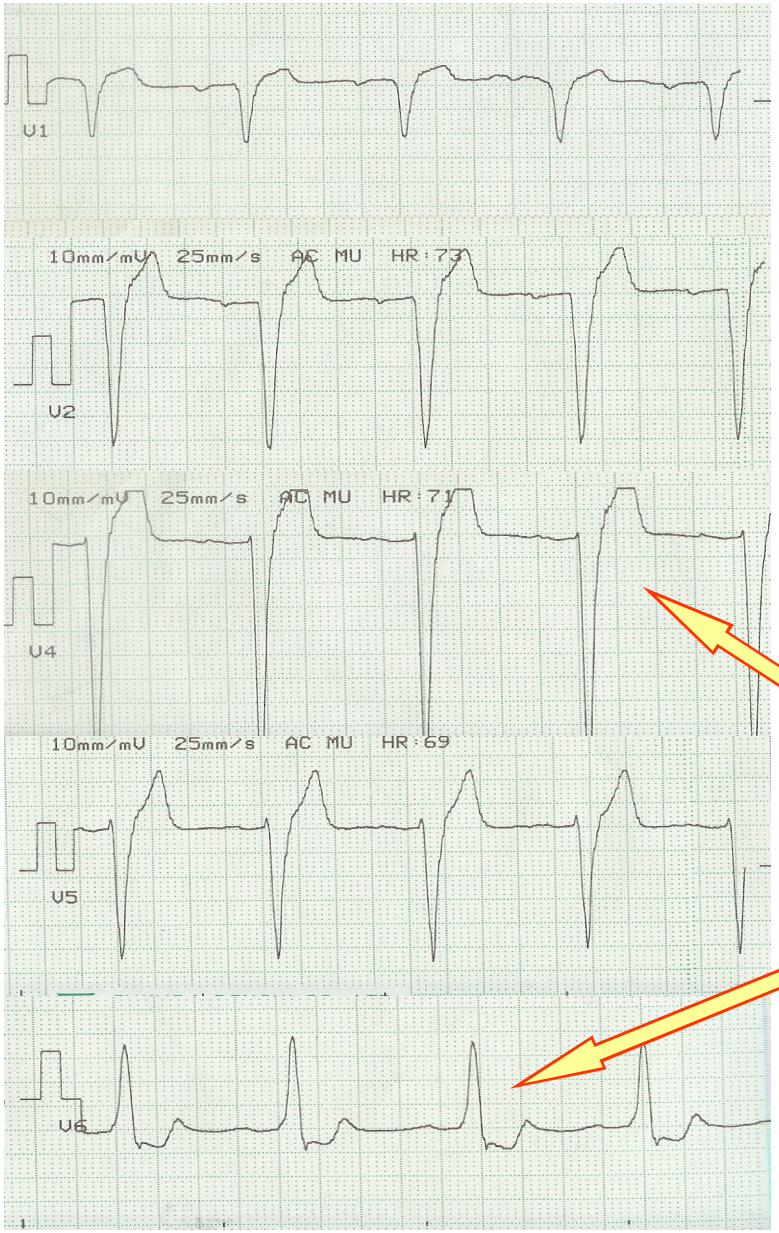

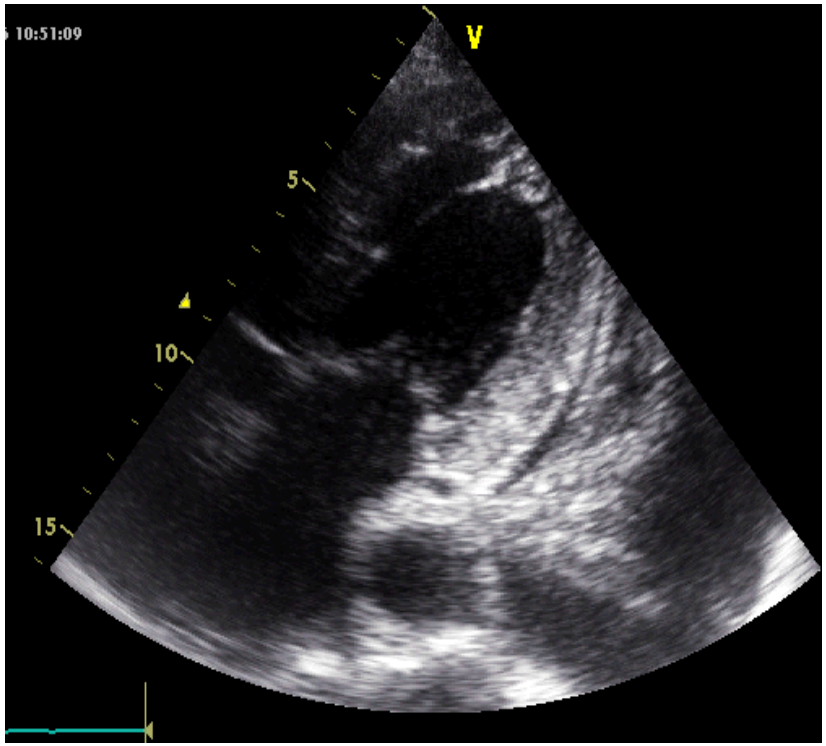

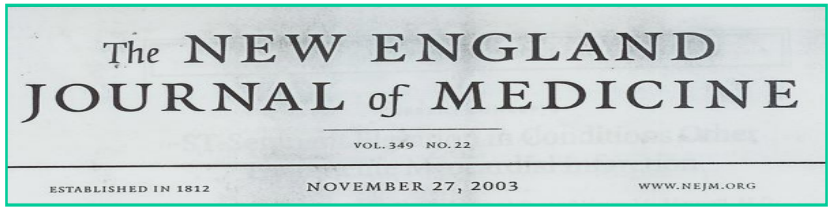
The NEW ENGLAND JOURNAL of MEDICINE

VOL. 349 NO. 22

ESTABLISHED IN 1812 NOVEMBER 27, 2003 WWW.NEJM.ORG

…e ai ritmi elettrocondotti

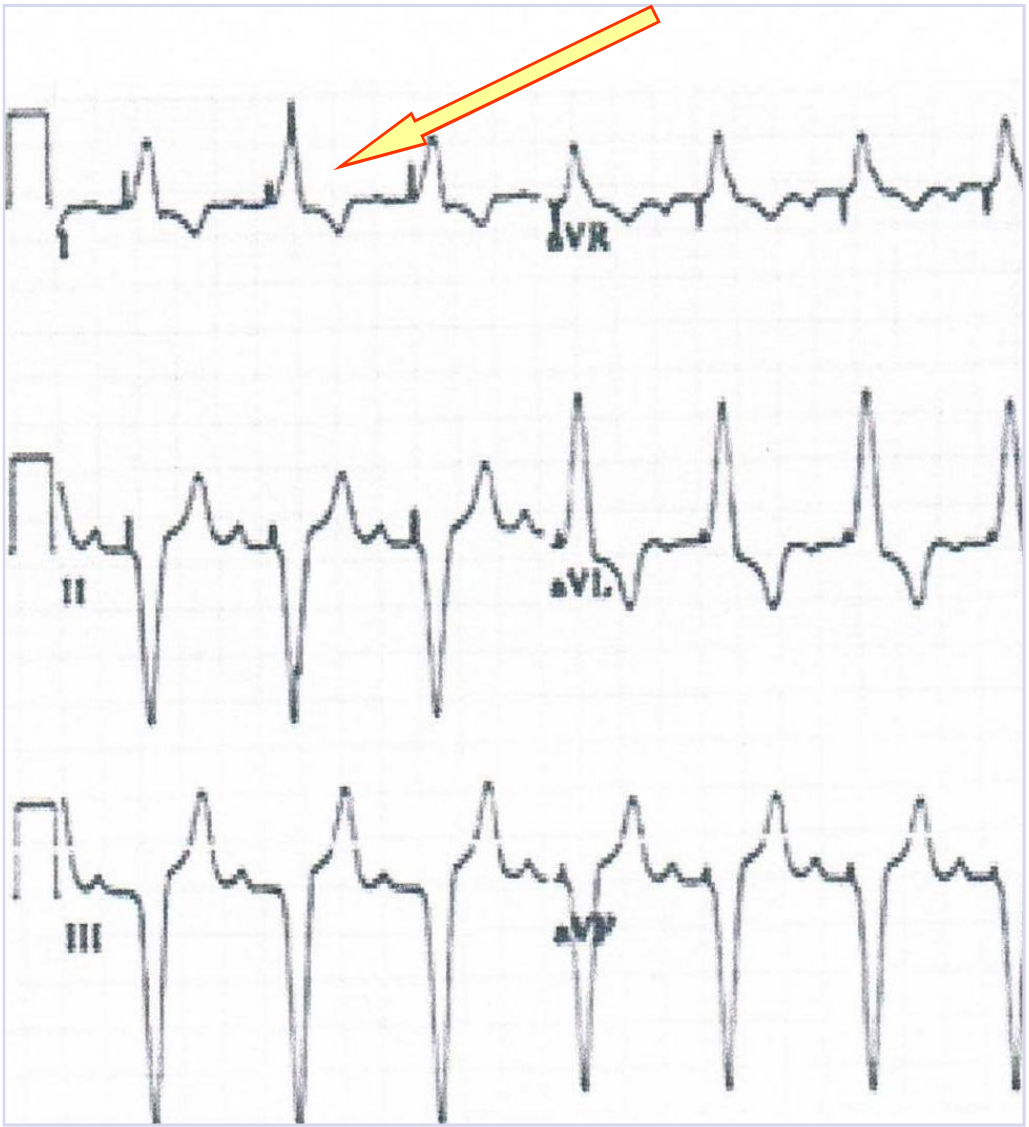

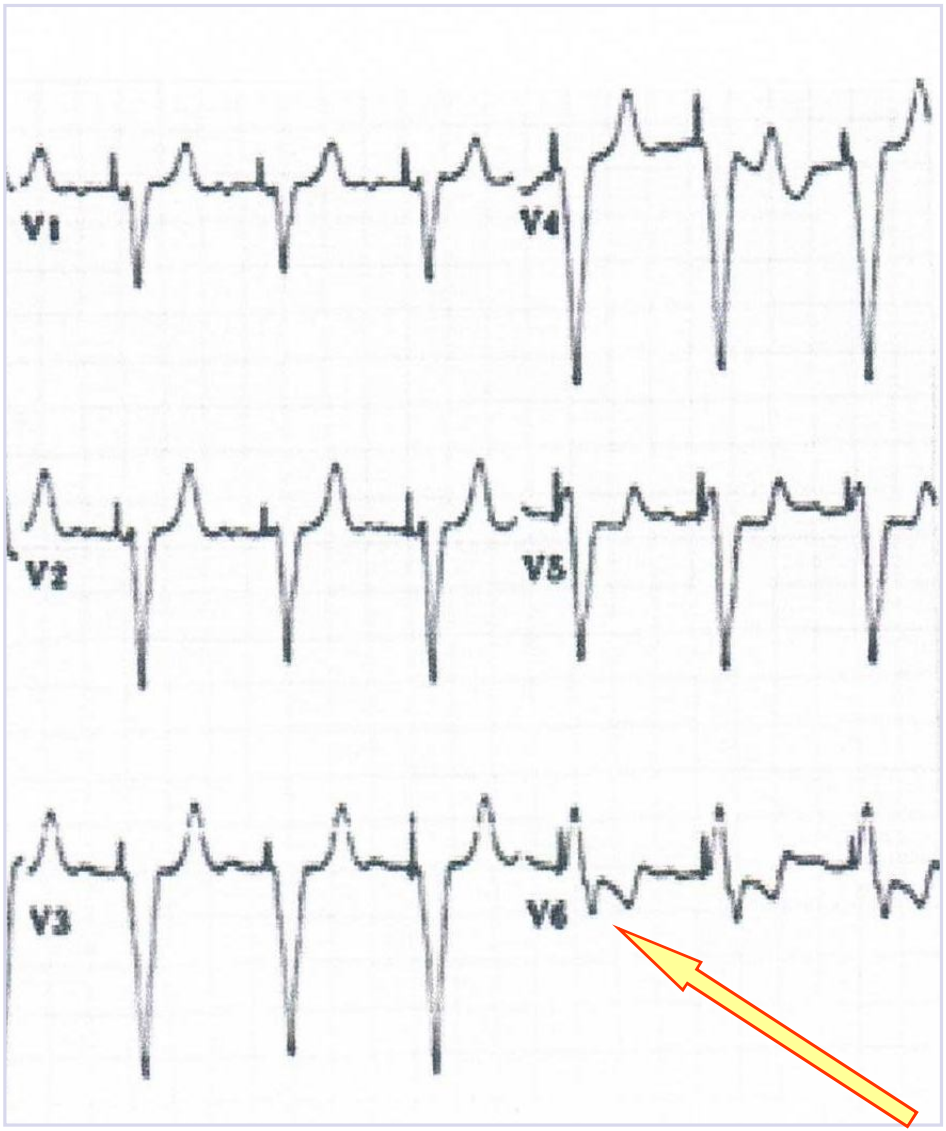

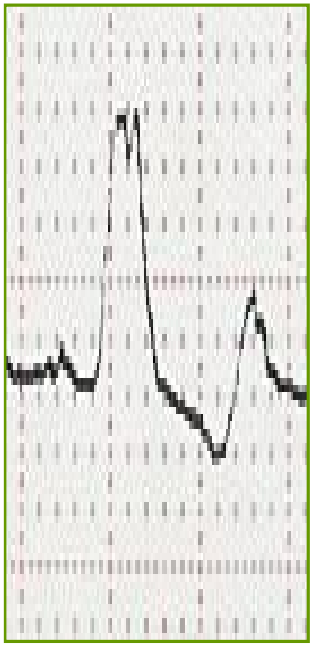

normale...

discordanza appropriata

Am J Emerg Med 2002; 20: 35-38

precordiali destre

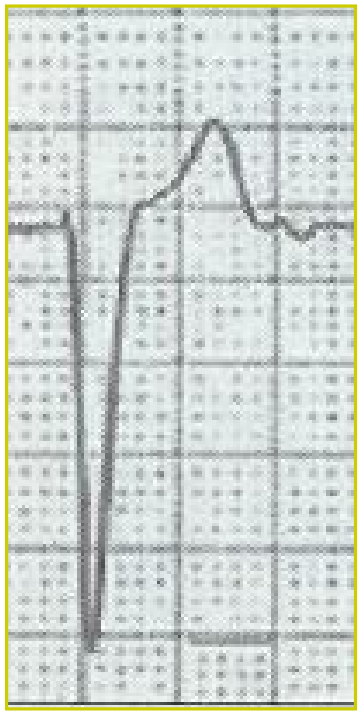

precordiali sinistre

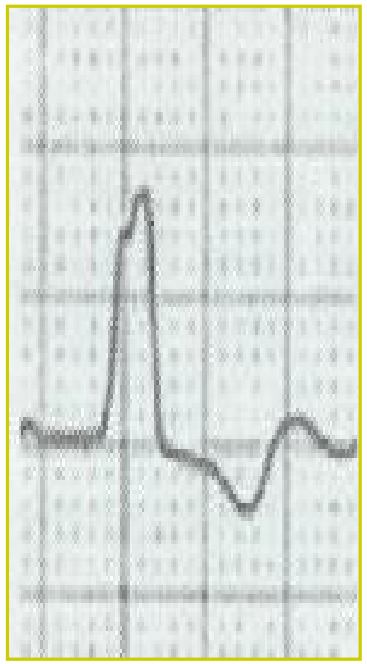



S.C.A.



normale discordanza appropriata…

durante dolore…

…concordanza disappropriata

S.C.A.

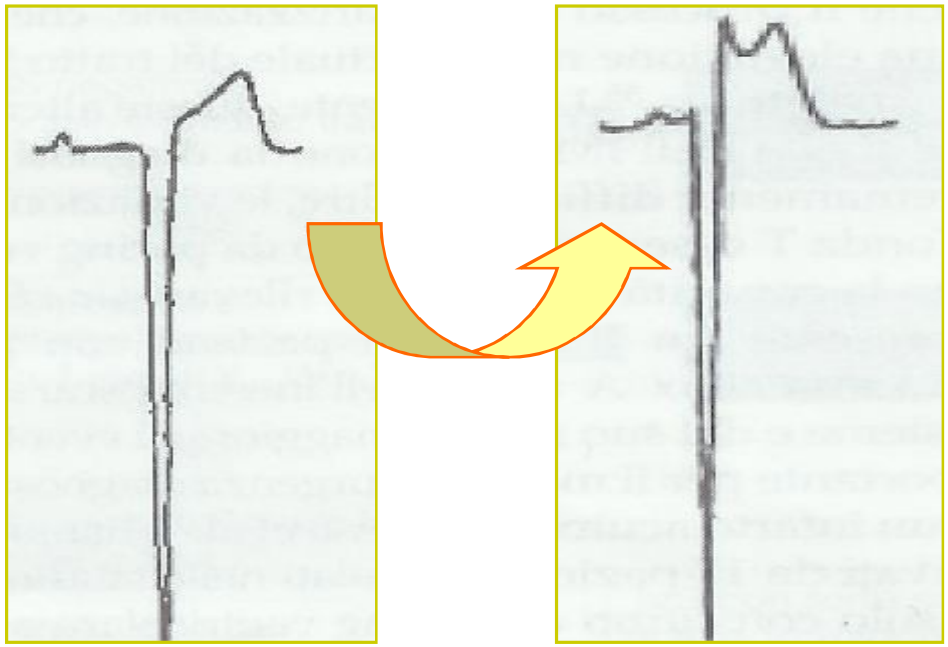

…eccessivo sopralivellamento discordante > 5 mm nelle precordiali destre

bassa sensibilità (31%)

alta specificità (92%)



Am J Emerg Med 2002; 20: 35-38

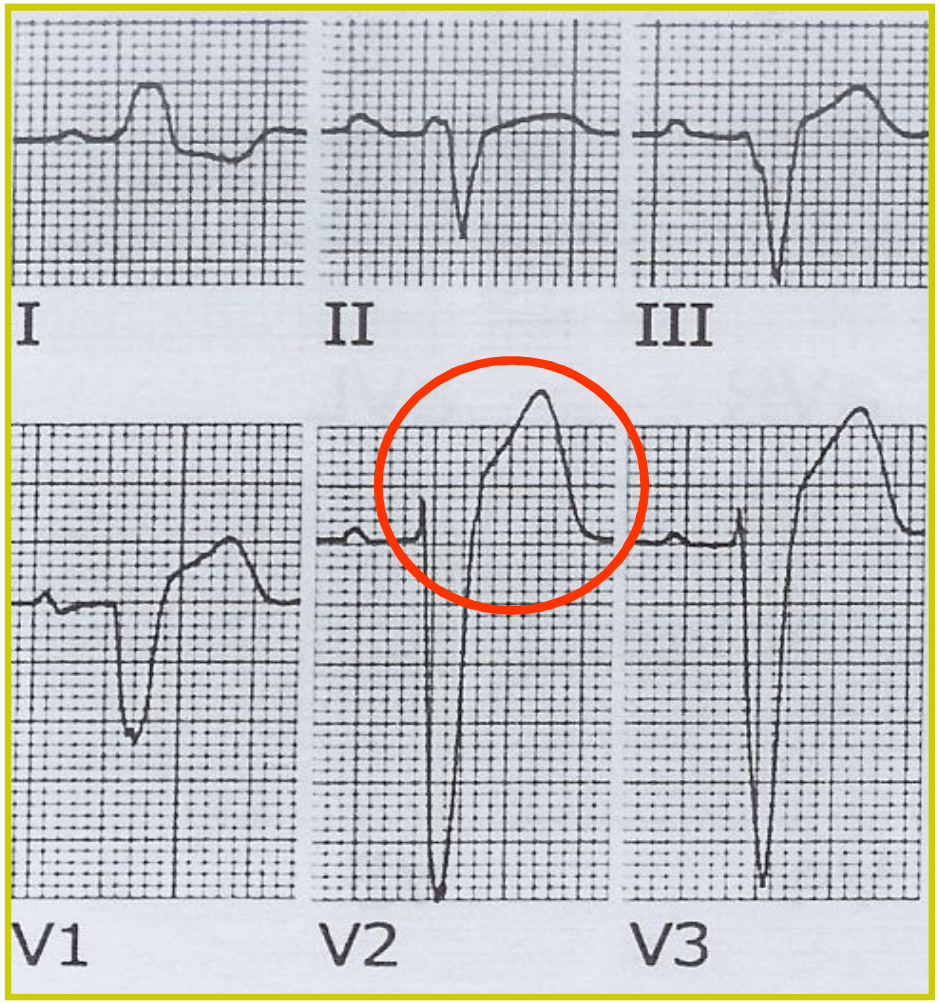

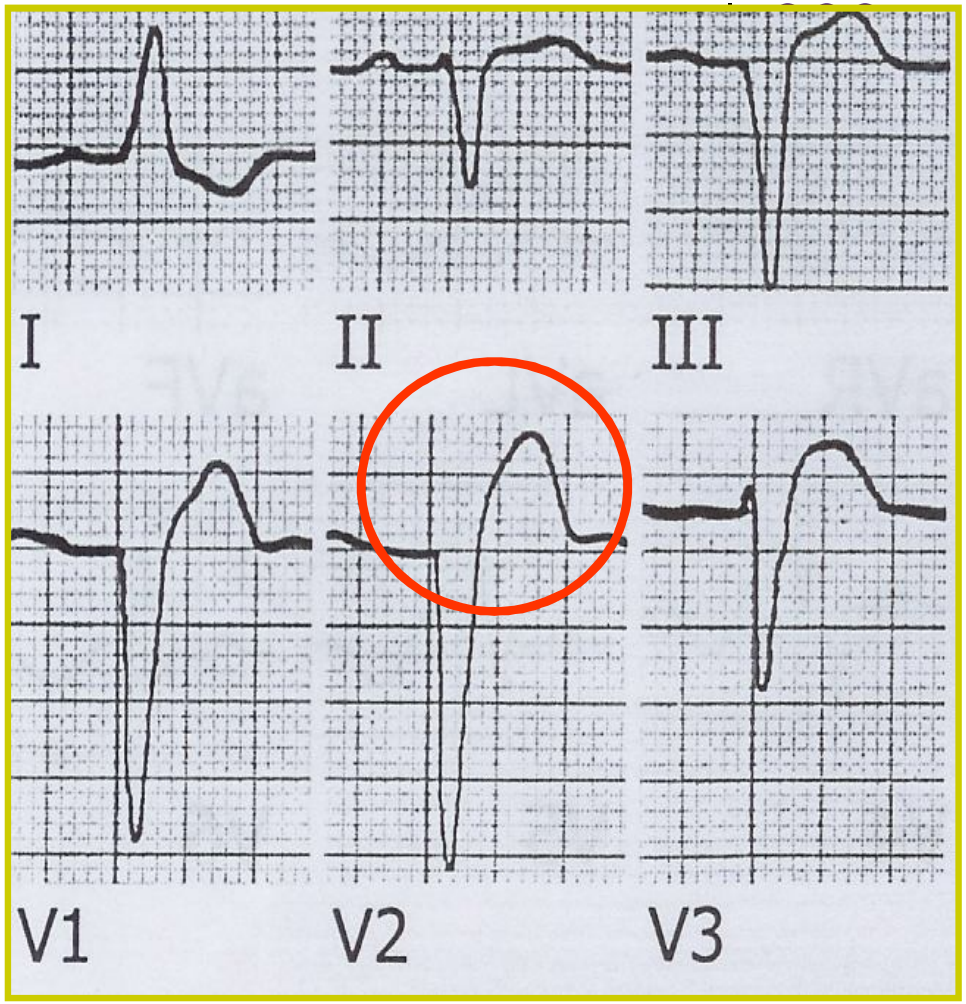

S.C.A.



TROPONINA T	0,323	*
CK-MB massa	11,6	*
MIOGLOBINA	181,1	*

Am J Emerg Med 2002; 20: 35-38

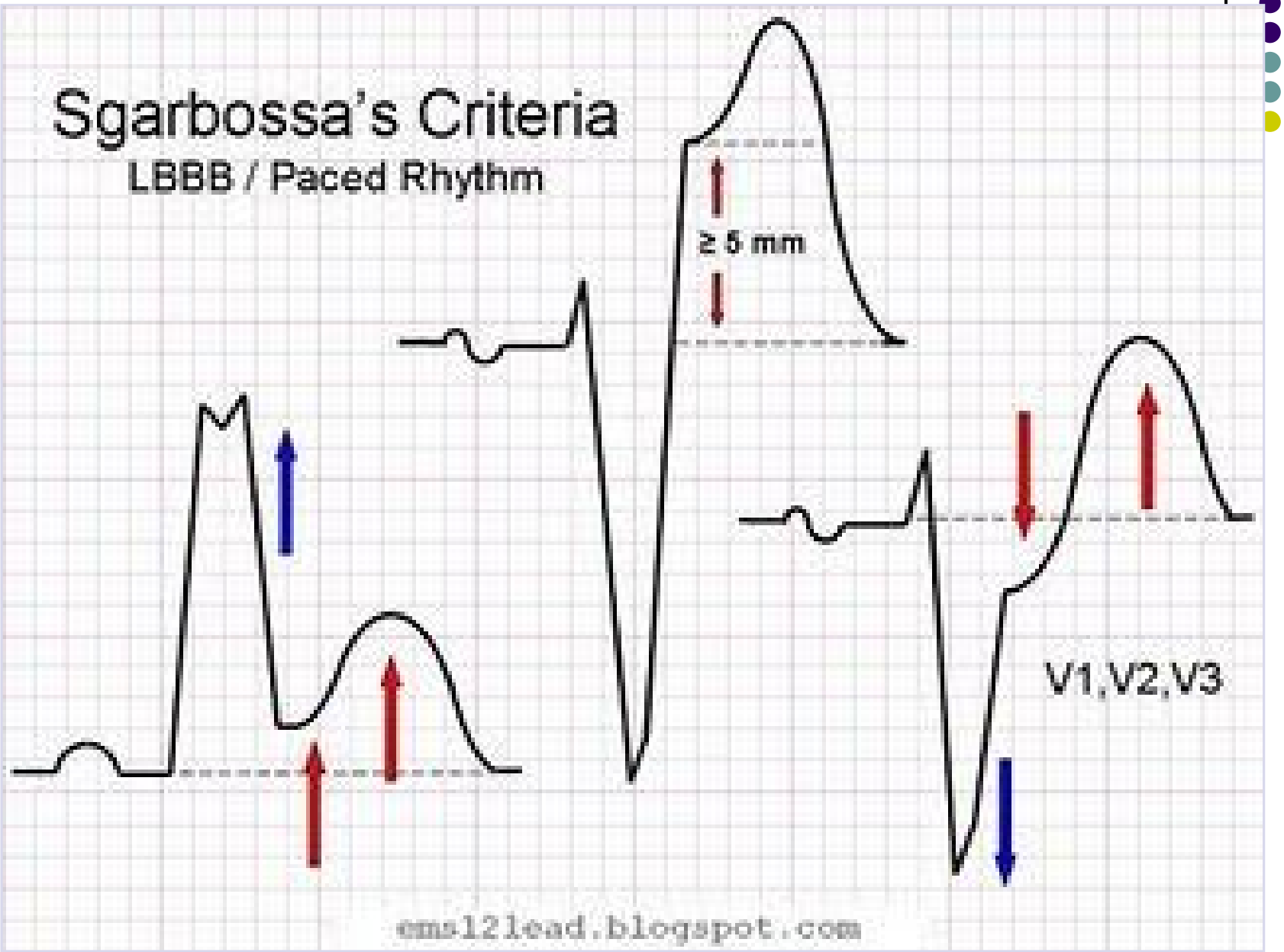
Sgarbossa's Criteria
LBBB / Paced Rhythm
≥ 5 mm
V1,V2,V3
ems12lead.blogspot.com

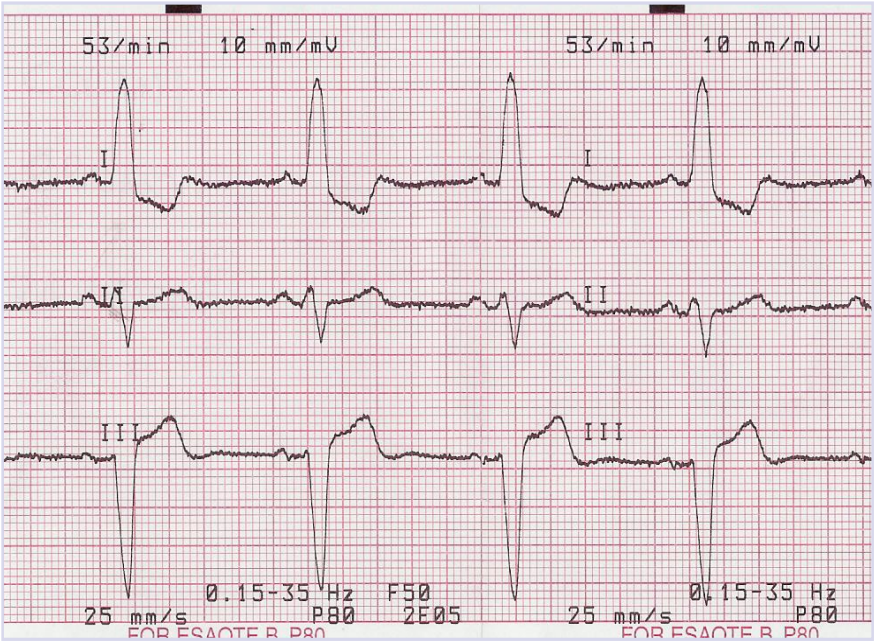

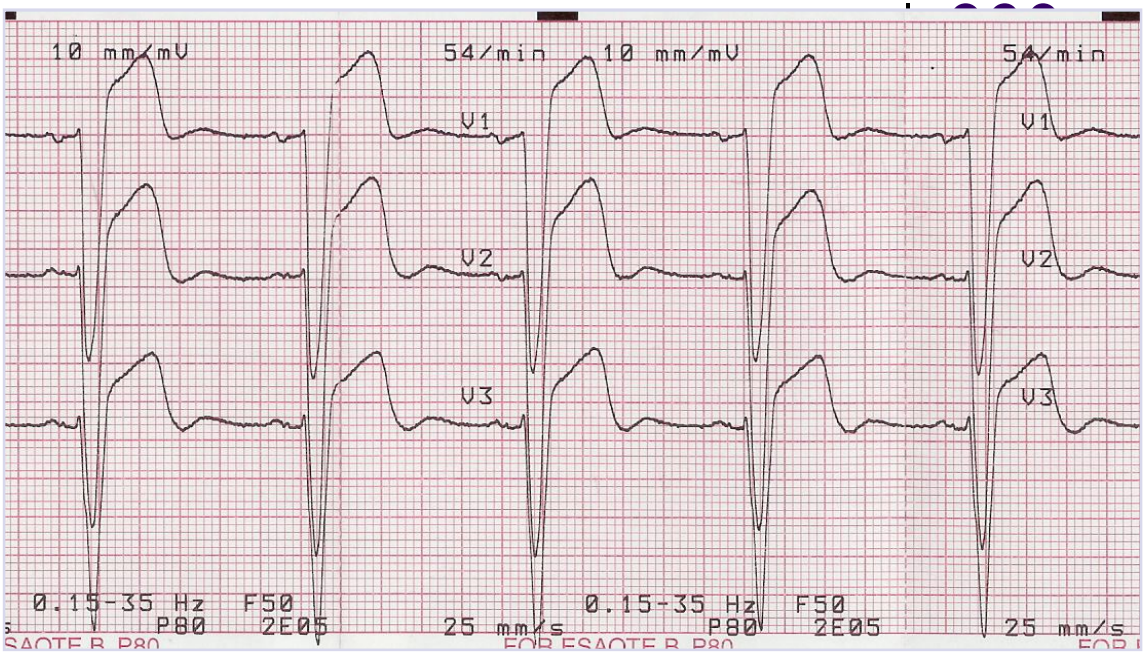

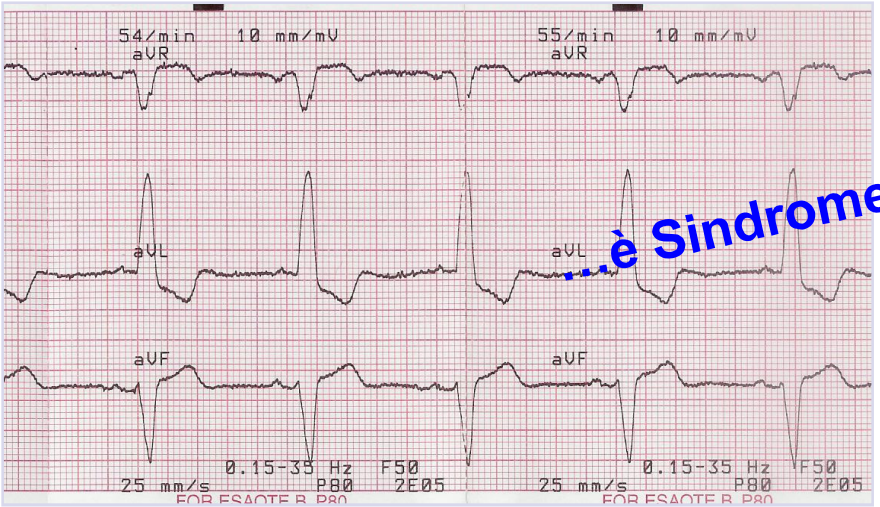

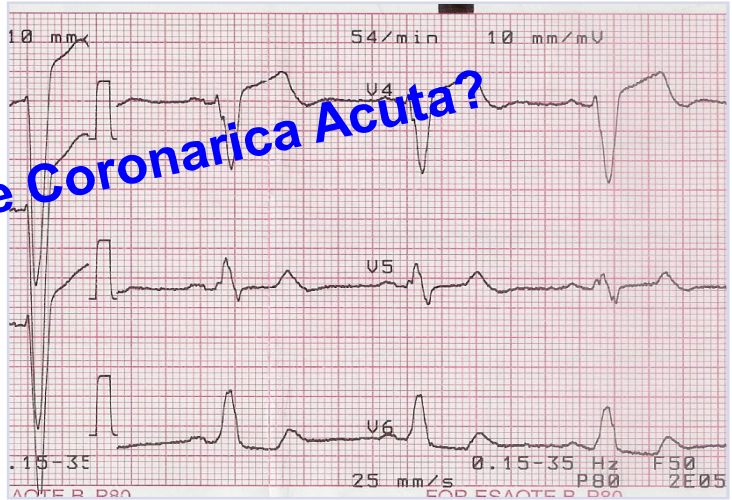

...è Sindrome Coronarica Acuta?

Gesualdo F. anni 51

Dolore toracico tipico.Stato ipotensivo

Sindrome metabolica

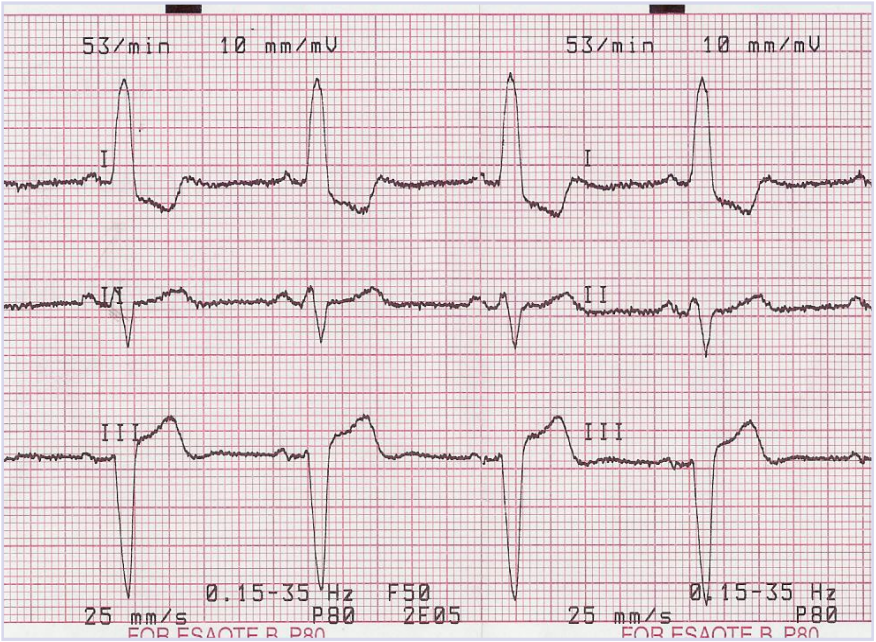

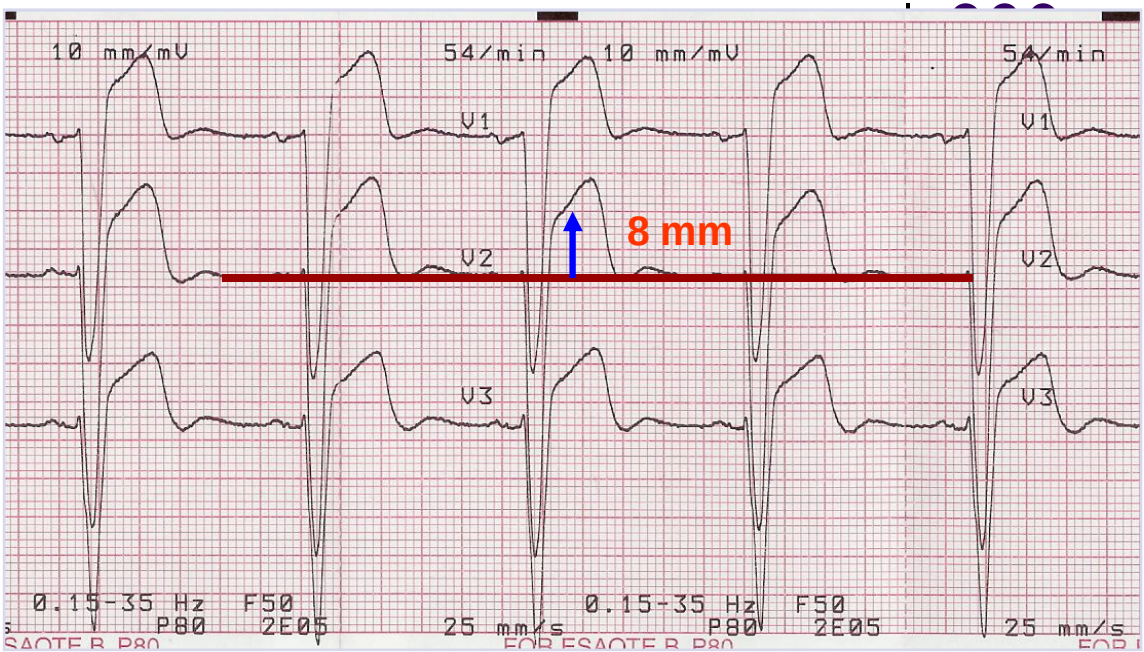

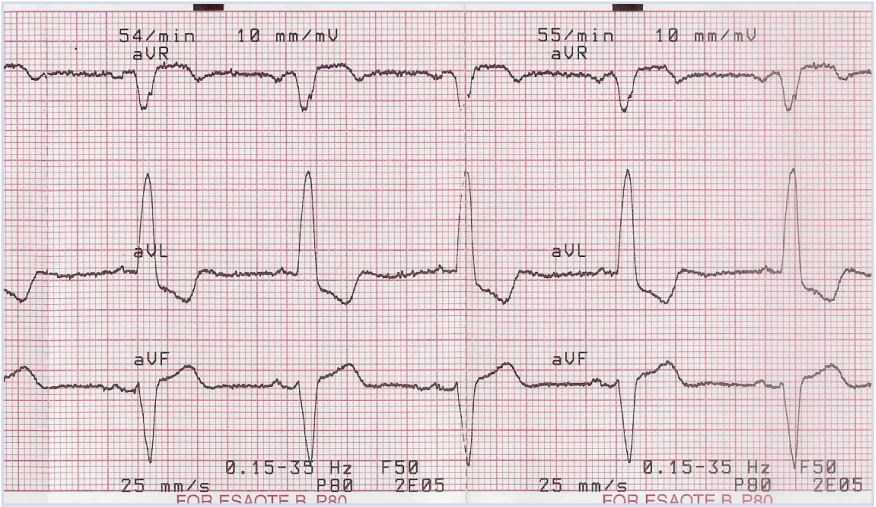

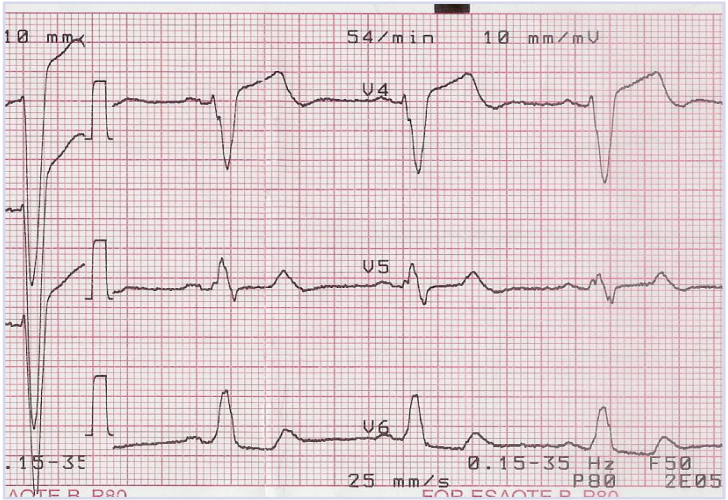

Gesualdo F. anni 51

Dolore toracico tipico.Stato ipotensivo

Sindrome metabolica

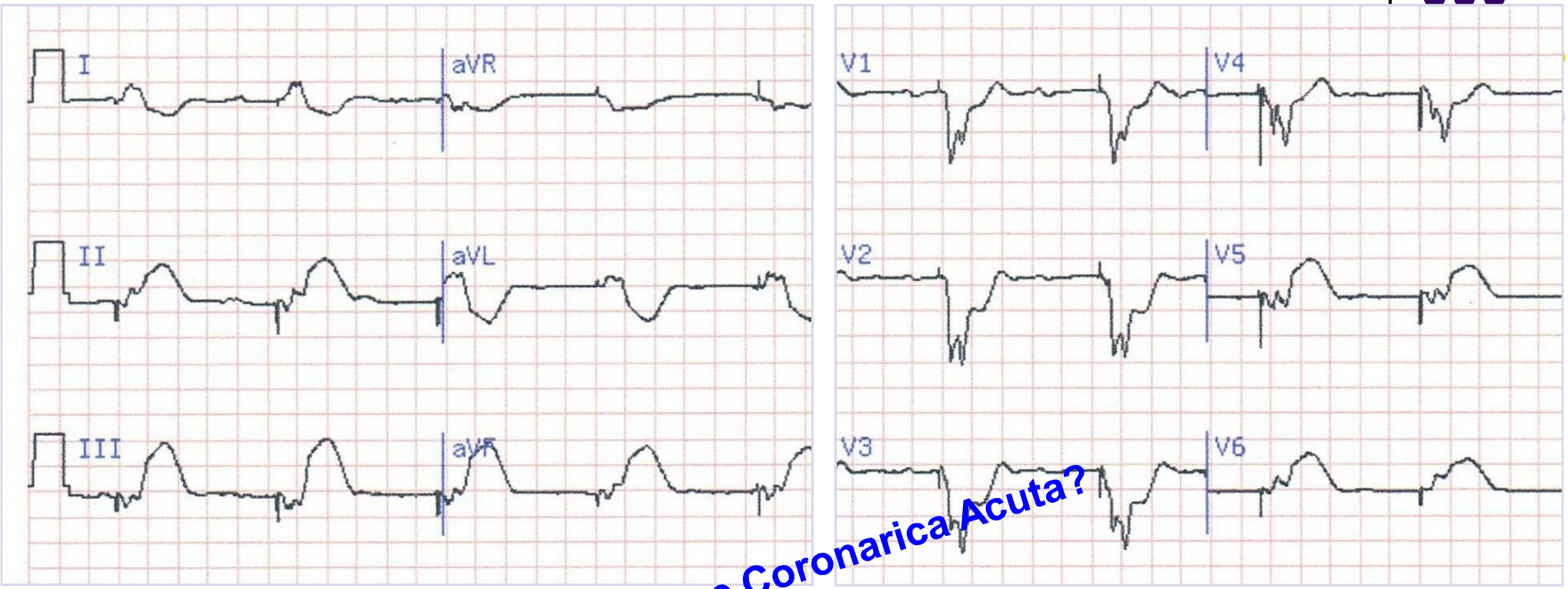

…è Sindrome Coronarica Acuta?

Fernandez S. anni 82

dispnea durante dolore toracico

In P.S. per asma cardiaco

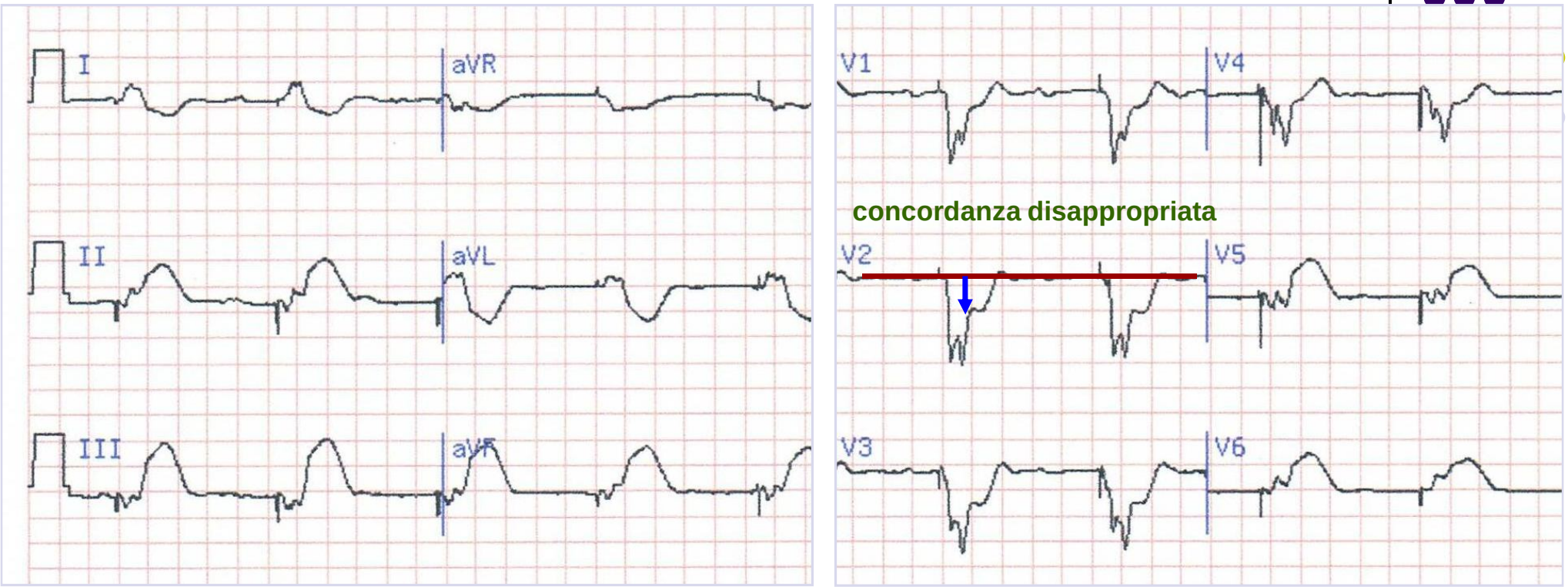

Fernandez S. anni 82

dispnea durante dolore toracico

In P.S. per asma cardiaco

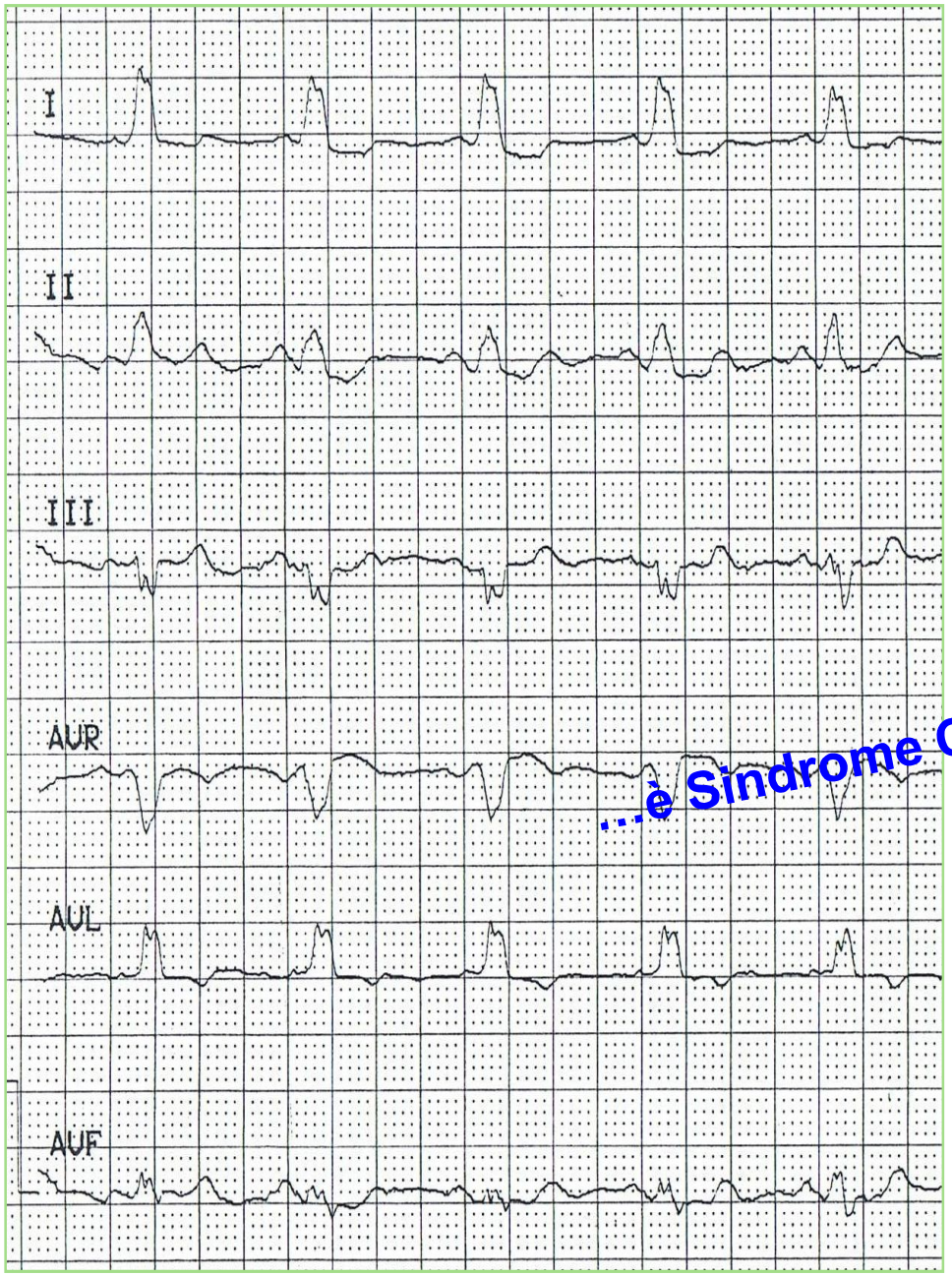

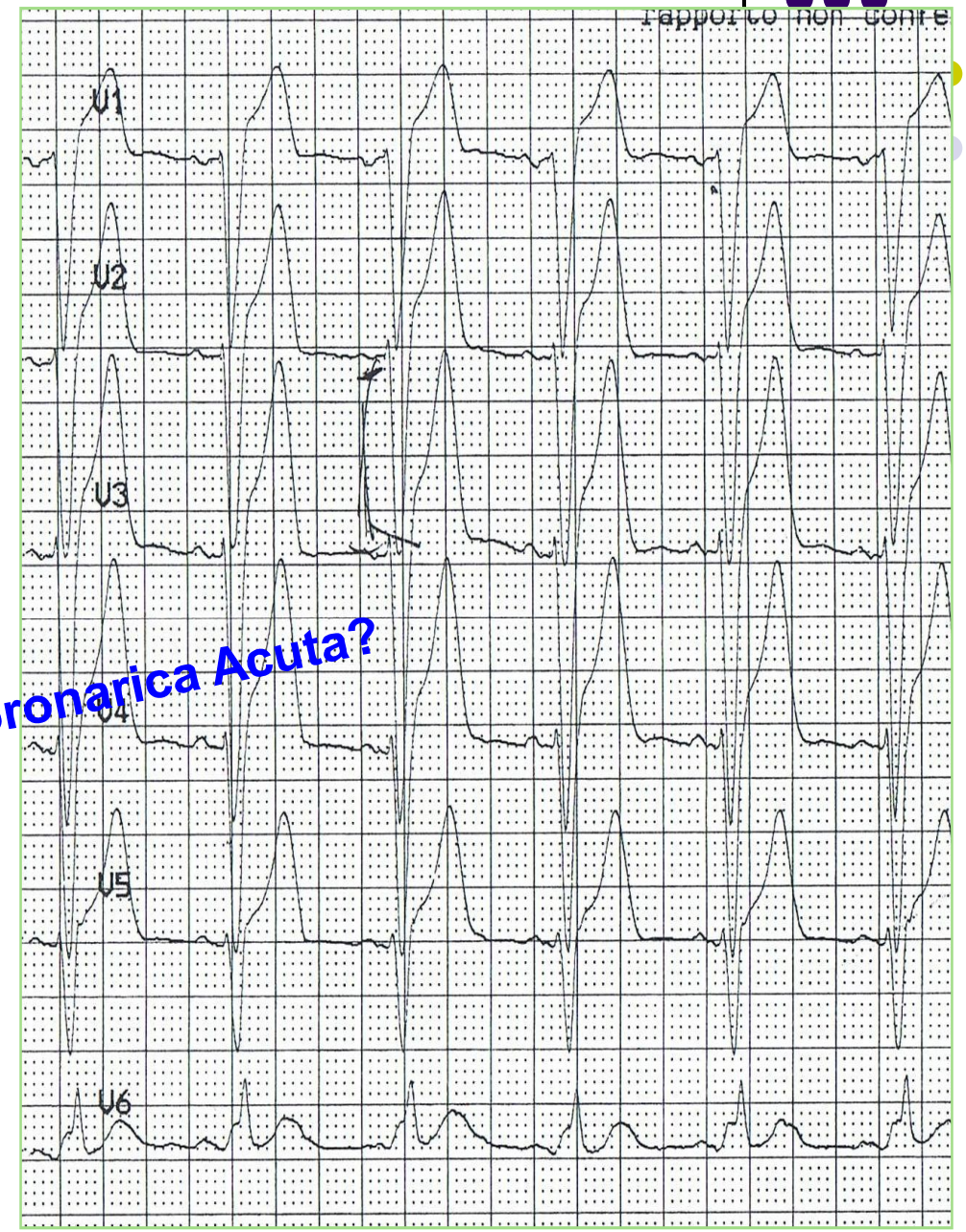

...è Sindrome Coronarica Acuta?

Strato F. anni 86

dolore toracico persistente costrittivo;

non disponiamo di ECG precedente

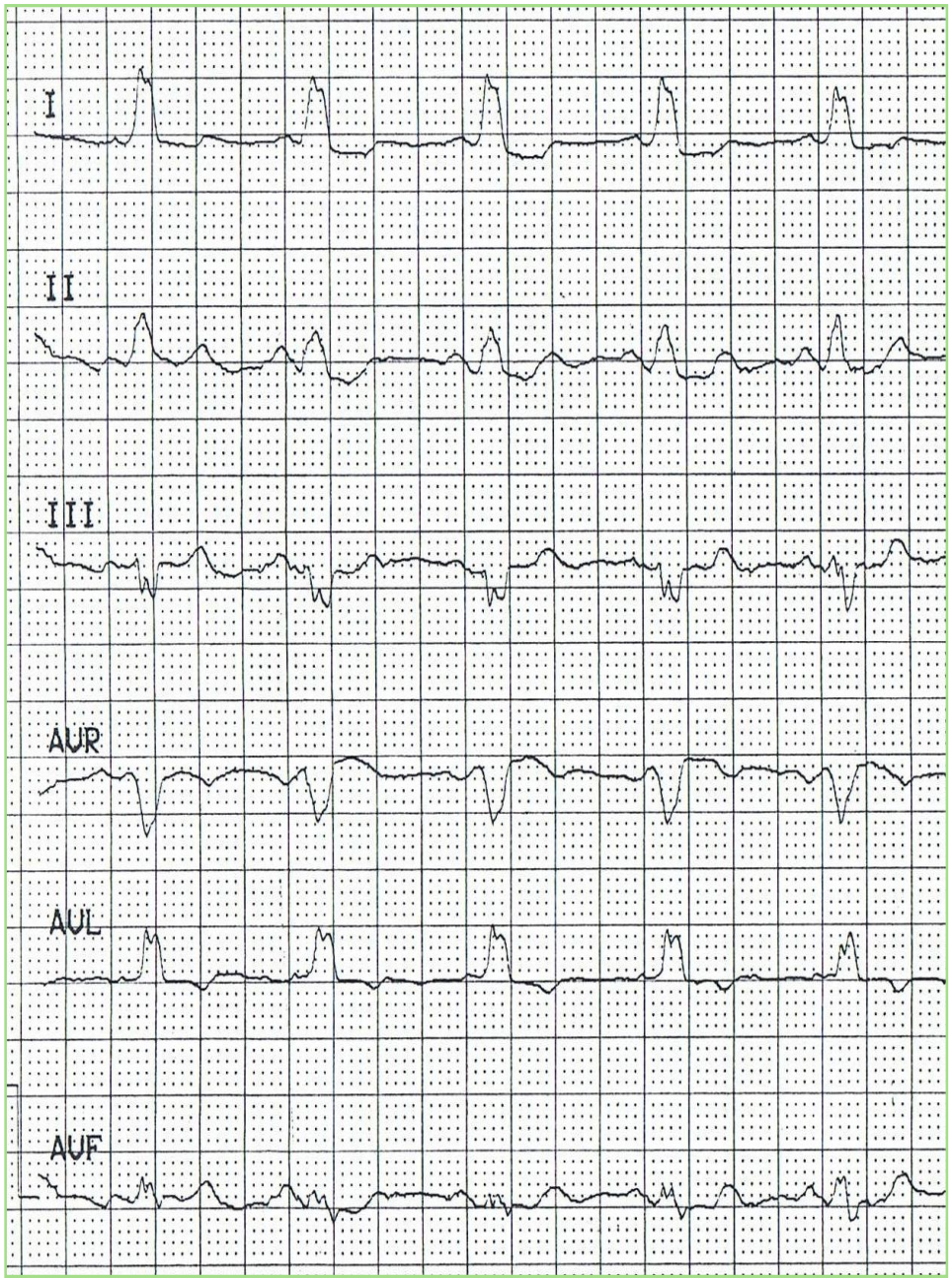

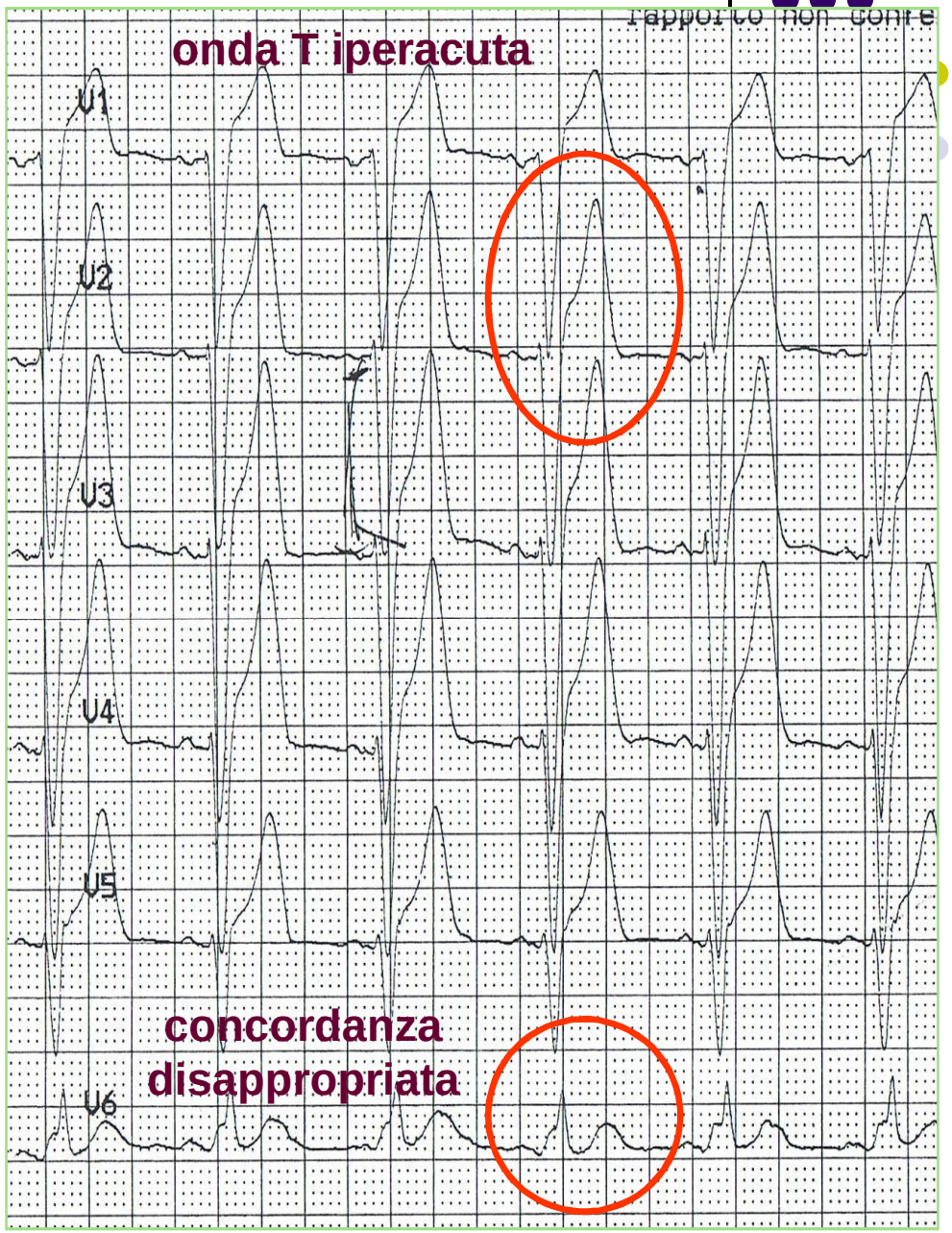

Strato F. anni 86

dolore toracico persistente costrittivo;
non disponiamo di ECG precedente

…le insidie sembrano terminate

…torniamo in P.S.

CORRELARE SEMPRE
tempo – modifiche ECG

l'ECG è un film… sempre in evoluzione

non accontentiamoci di un solo fotogramma

Attenzione! *dolore tipico ma…*

Eleonora a 74

…dopo circa 90 min

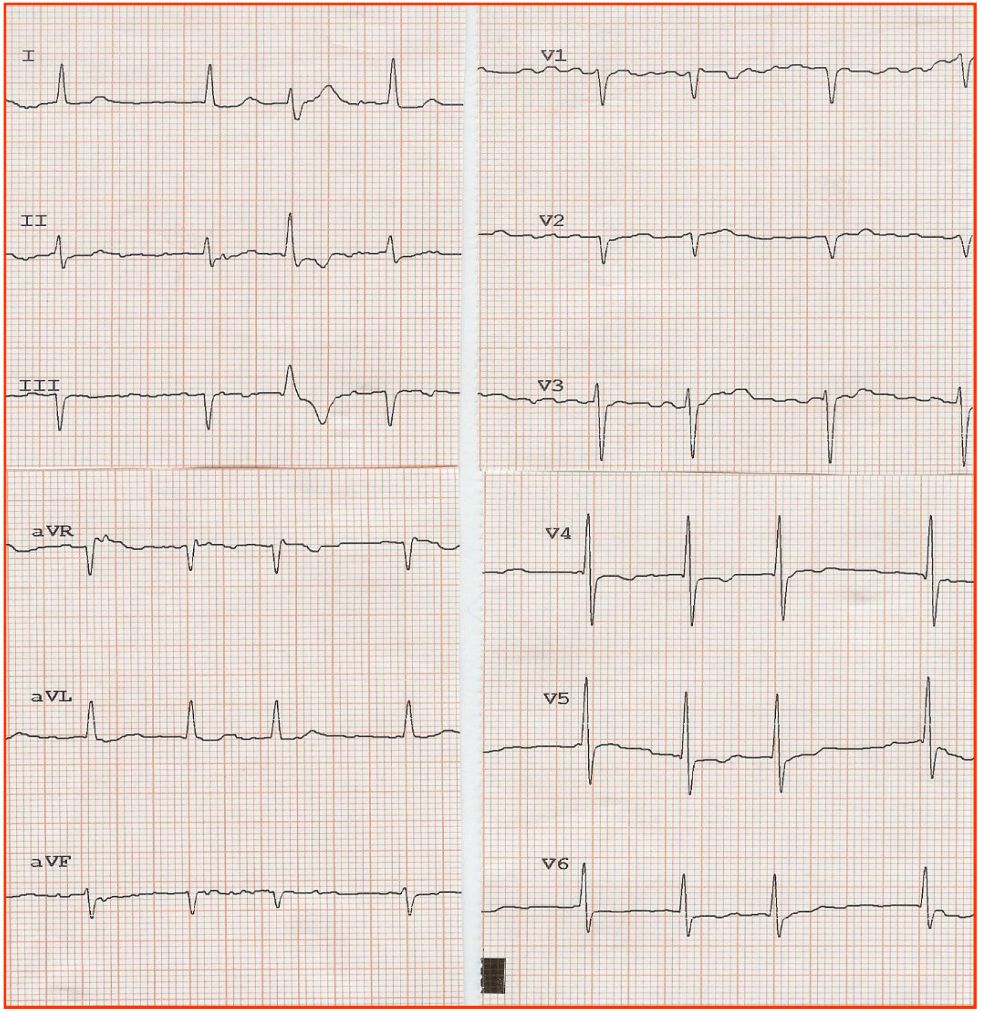

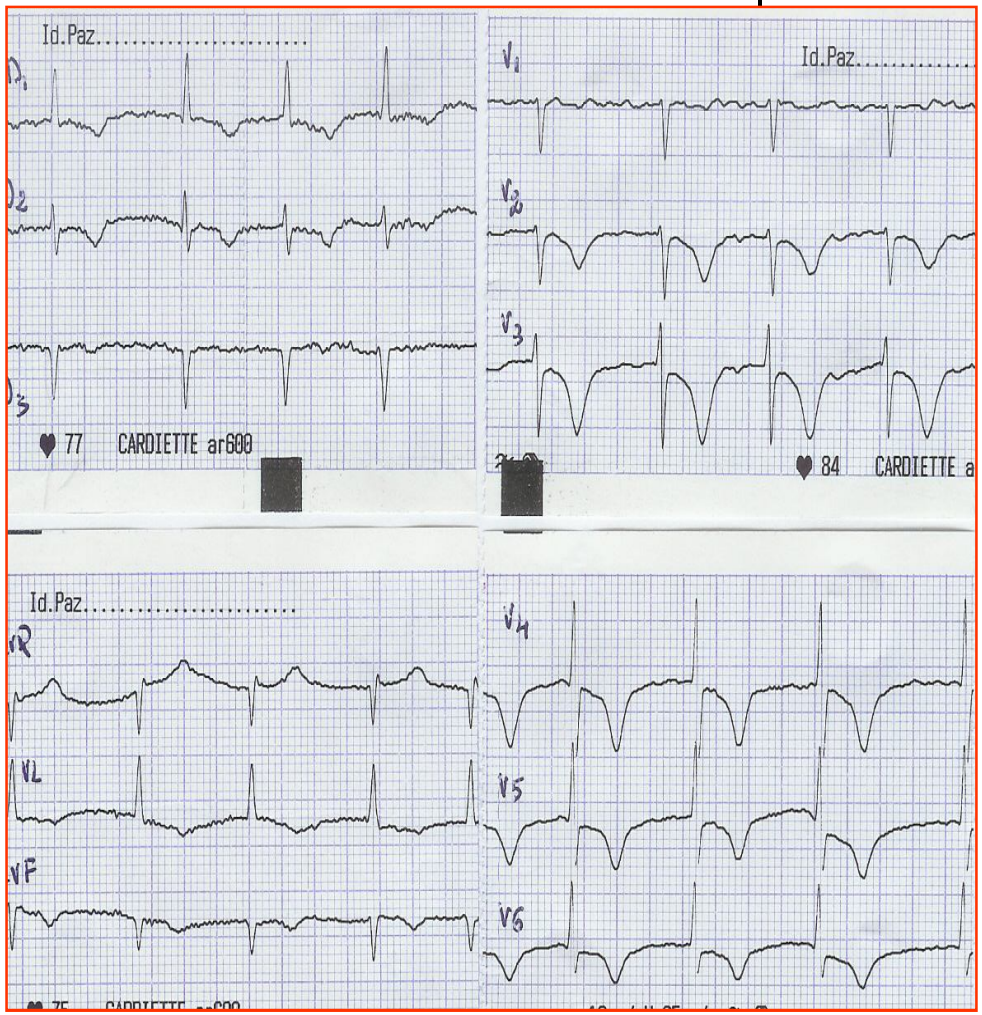

ECG muto all'esordio…

… che acquista di significato nei controlli successivi

Attenzione! *dolore tipico ma…*

Eleonora a 74

…dopo circa 90 min

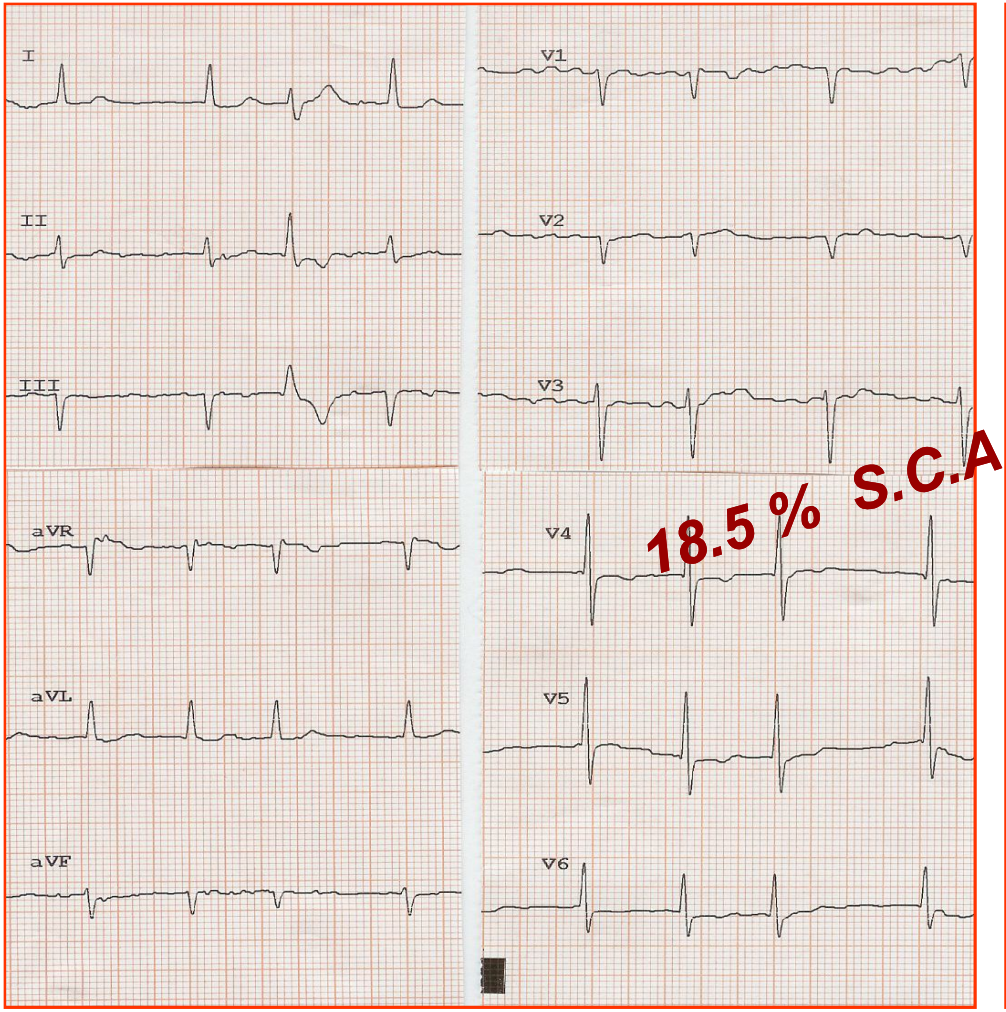

18.5 % S.C.A.

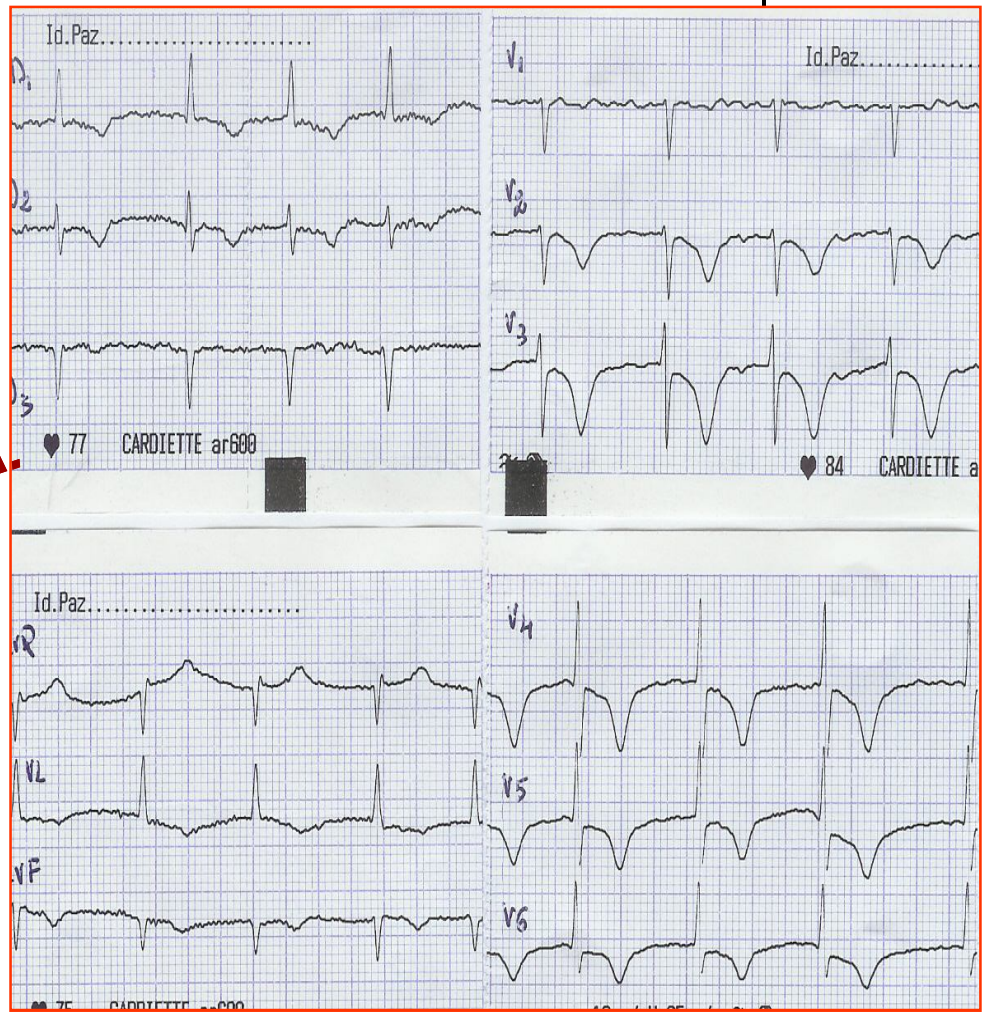

ECG muto all'esordio…

… che acquista di significato nei controlli successivi

UNITA' SEMPLICI DI VALUTAZIONE DOLORE TORACICO

Chest Pain Units – OBI - altro…

…limitrofa al P.S.

…dotata di sistemi di monitoraggio continuo

…dotata di strumenti per ACLS

…non è prevista la Sala di Emodinamica

…rilevazione continua dei parametri vitali

…monitoraggio continuo ECG per ritmo e tratto ST

…prelievo per marcatori danno miocardico ogni 3 – 4 ore

…ASA e nitrati s.l.

…eventuale stress-test prima della dimissione

CORRELARE SEMPRE
sintomo – modifiche ECG

Attenzione !

ISCHEMIA SILENTE
alterata soglia del dolore

Giulia C. ***a 78, da alcuni giorni tachipnea… mai dolore tipico…***

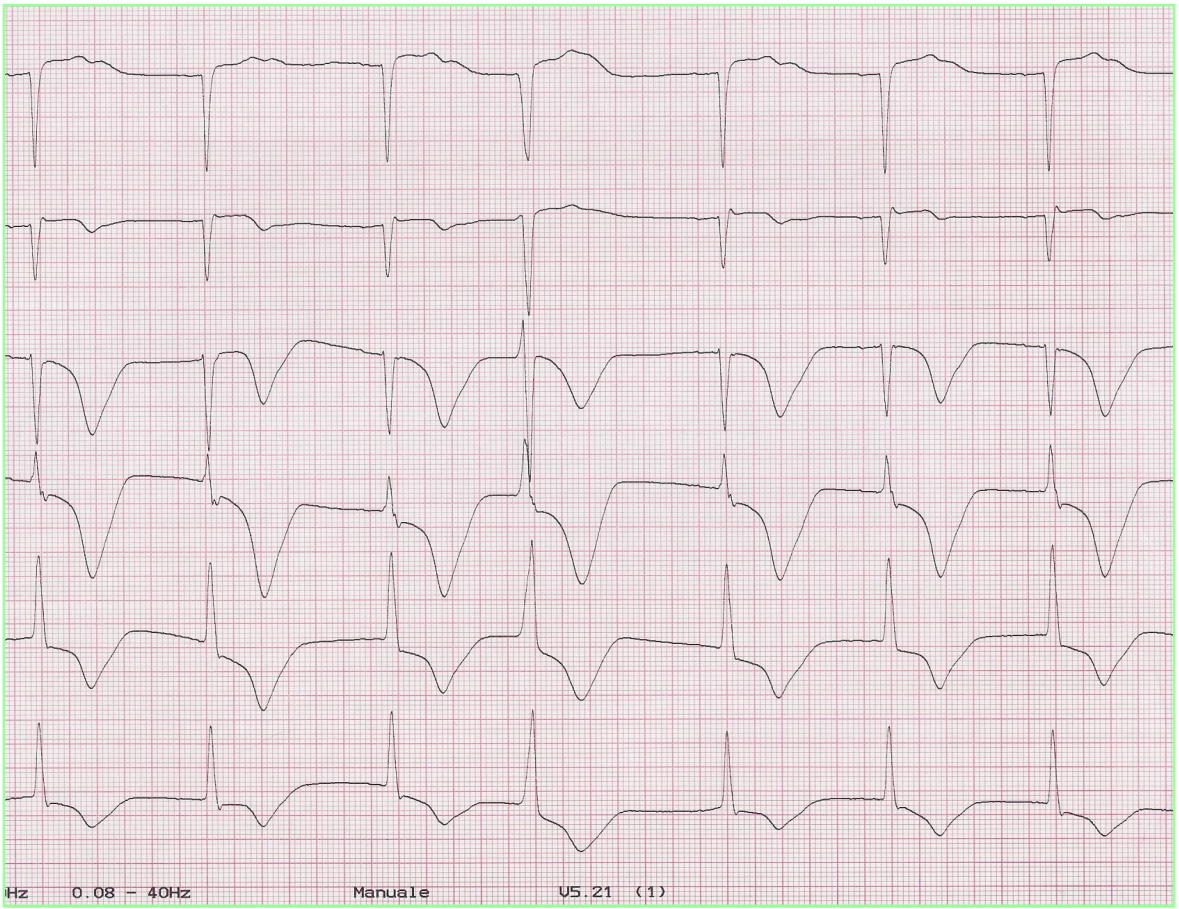

anni 78 donna

diabete mellito

polineuropatia

ipertensione arteriosa

FAST TRACK

valutazione medica + ECG

entro 10 min dall'arrivo in P.S.

se età > 30 anni dolore toracico non traumatico

e in assenza di infezioni respiratorie

FAST TRACK

valutazione medica + ECG

entro 10 min dall'arrivo in P.S.

se età > 30 anni dolore toracico non traumatico

e in assenza di infezioni respiratorie

se età > 50 anni anche in assenza di dolore toracico

ma con dispnea tachipnea sincope

circa 1/3 dei pazienti con IMA arriva in P.S.

senza dolore toracico

Reference: Graff L, Palmer AC, LaMonica P, Wolf S. Triage of patients for a rapid (5-minute) electrocardiogram: a rule based on presenting chief complaints. Ann Emerg Med. December 2000;36:554-560.

troponina

Brugada

onda delta

early

angina instabile

ipertrofia

T.E.P.

pace-maker

N-STEMI

blocco di branca

tempo

dolore

Kent

iperkalemia

S.C.A.

pericardite

elettrocatetere

I.R.C.

troponina

Brugada

onda delta

early

ipertrofia

angina instabile

T.E.P.

pace-maker

N-STEMI

blocco di branca

tempo

dolore

Kent

iperkalemia

S.C.A.

pericardite

elettrocatetere

I.R.C.

riconoscere… i quadri ECG tipici STE - NSTE

non dimenticare… compromissione Vt dx

infarto posteriore

occlusione tronco comune

ricordare…

STsopra non ischemici

considerare sempre

…fattore tempo

…le ischemie silenti

…le varianti normali

…e saper interagire con il "cugino" cardiologo

GRAZIE a voi tutti…

“le parole ci stancano… forse il cuore ci sostiene, forse il cuore”

Salvatore Quasimodo

...verifica
...verifica
...verifica

qualcuno già dorme…
è bene interrogare

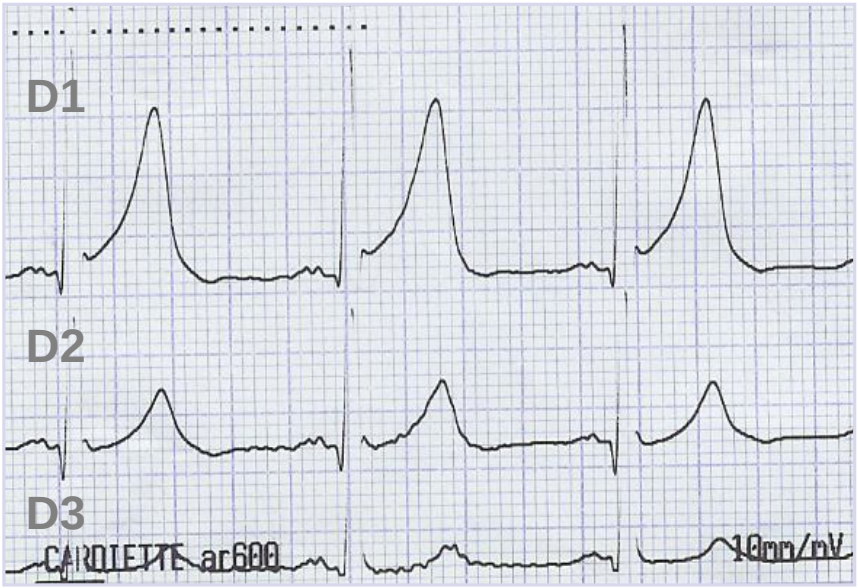

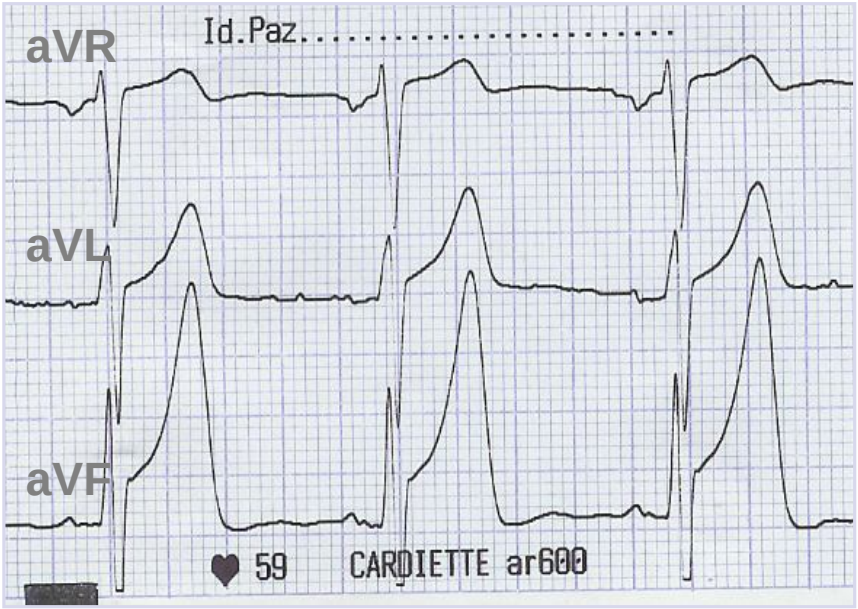

…elevazione punto J

se in soggetti non più giovani

se in derivazioni inferiori e/o laterali

se > 2 mv

AUMENTATA POSSIBILITA'

MIC PER ARITMIA ???

…quanta preoccupazione osservando questo ecg!

l'utilità della cultura …

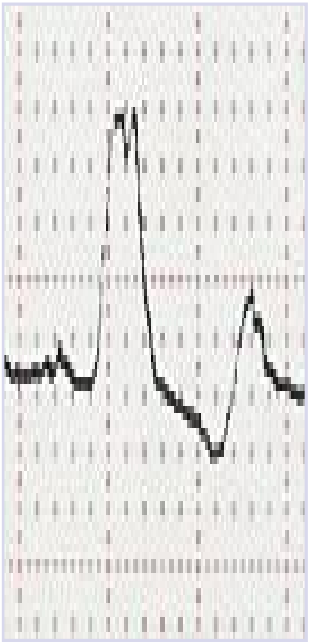

normale…

discordanza appropriata